

**Case Report****Chronic lymphocytic leukaemia with microfilaria: A rare coincidence with review of literature**Iffat Jamal^{1,*}, Ravi Bhushan Raman¹, V N Choudhary¹¹Dept. of Hematology, Indira Gandhi Institute of Medical Sciences, Patna, Bihar, India**ARTICLE INFO***Article history:*

Received 17-02-2020

Accepted 08-04-2020

Available online 19-08-2020

Keywords:

Splenomegaly

Microfilariae

W bancrofti

Elephantiasis

Haematological Case History

ABSTRACT

Filariasis is a common disease in tropical and subtropical countries including India. But only very few case reports of incidental filariasis have been observed associated with hematological malignancies. We are presenting a case of chronic lymphocytic leukemia (CLL) with associated filariasis which is a rare coincidence. It has been attributed to the immunocompromised state in hematological malignancies that make patients susceptible to parasitic infections.

© 2020 Published by Innovative Publication. This is an open access article under the CC BY-NC license (<https://creativecommons.org/licenses/by-nc/4.0/>)

1. Case History

A 59 year old patient presented to Dept of Hematology with complaints of low grade fever, malaise, pain abdomen and weakness. USG abdomen revealed moderate splenomegaly of 12 cm. Liver and kidney function tests were within normal limits. Complete blood counts revealed RBC counts of 1.35 millions/cumm, haemoglobin of 3.8 gm% and marked leucocytosis with total WBC count of 2.8 lacs /cumm with 96% lymphocytosis. Platelets were markedly reduced (45000/cumm). Peripheral blood smear examination showed marked leucocytosis composed of small monomorphic mature appearing lymphoid cells comprising 96% with 3% prolymphocytes and eosinophils 1%. Few sheathed microfilariae were seen in the blood smears, morphologically resembling as microfilariae of *W. bancrofti*, as they lacked terminal nuclei. Hence we report this case to highlight association of this common parasite with hematological malignancies which is quite uncommon. (Figure 1)

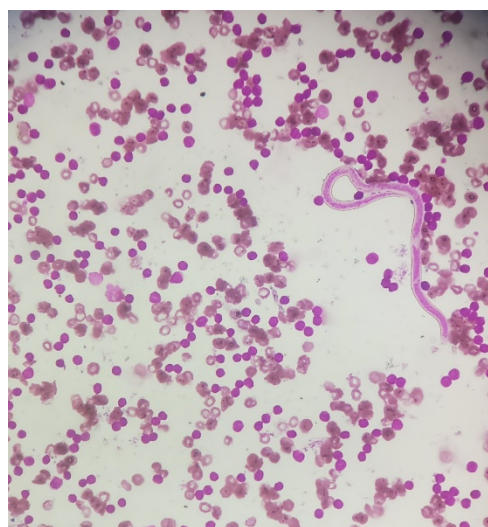


Fig. 1: Peripheral blood smear showing absolute lymphocytosis with mature lymphocytes and microfilaria (Leishman stain ; 400X)

* Corresponding author.

E-mail address: iffatjamal111@gmail.com (I. Jamal).

Table 1: comparative study of various hematological malignancies associated with microfilaria

Name of the study and year	Hematological malignancy associated with microfilaria	Age/sex
Arundhati et al., 2011	Acute lymphoblastic leukemia	21/F
Suniti P et al., 2015	Blast crisis of Chronic myeloid leukemia	37/M
Deepa R et al., 2018	Blast crisis of chronic myeloid leukemia	50/M
Present study. 2019	Chronic lymphocytic leukemia	59/M

2. Discussion

Filariasis is one of the most common hemoparasitic infestation in endemic zones like India. In human beings it is caused by *W. bancrofti* and *Brugia malayi* that causes lymphatic obstruction.¹ The adult worm lodges in the lymphatics and the microfilariae circulate in the blood stream.² Clinical manifestations of filariasis are lymphangitis, elephantiasis (swelling of limbs) and peripheral blood eosinophilia.³ Some cases of filariasis are asymptomatic and incidentally discovered.^{4–7} Such asymptomatic microfilaremia is relatively common in India.⁸

Microfilariae have been accidentally detected in the fine needle aspirate smears (FNAC) from thyroid, breast, subcutaneous nodules, cervical scrapings, bronchial washings including body fluids. The presence of microfilariae in bone marrow aspirate is an unusual finding. The first documentation of microfilariae in bone marrow aspirate, available in English literature was by Pradhan et al. in 1976. Association of filarial parasite with malignancy has been described but its role in tumorigenesis is not so far explained. The coexistence of microfilaria and malignancy may be coincidental. There are very few case reports of incidental finding of filariasis with haematological malignancy. Pahwa et al. reported a case of filariasis with blast crisis of CML in bone marrow smears.⁹ In her case there were no eosinophilia similar to our case. One of the explanation of absence of peripheral blood eosinophilia in these cases may be due to altered immune response secondary to malignancy or due to the oxidative stress associated with filariasis.¹⁰

Arundhati et al., reported a case of acute lymphoblastic leukaemia in association with *W. bancrofti* microfilariae in the bone marrow aspirates. They attributed it to the immunocompromised state in hematological malignancies that make patients susceptible to parasitic infections. In some studies microfilaria is also seen incidentally associated with megaloblastic anemia.¹

Newer diagnostic modalities like circulating filarial antigen (CFA) tests which are easy to perform have been developed. Filariasis causes acquired eosinophilia and eosinophil blood count is commonly used as a screening tool. But microscopy still remains the cornerstone of its diagnosis. Microscopy is performed on thick and thin blood smears or buffy coat films stained

with Giemsa.¹¹ Concentration using centrifugation or Millipore membrane filters increases the sensitivity of light microscopy. The limitation is labour-intensiveness of preparing and examining microscope slides. The sensitivity of microfilariae detection depends on the volume of blood sampled, the time of blood collection, and potential introduction of bias depending upon the skill and dedication of pathologists. Unfortunately, microfilariae are frequently absent from the blood during both the early and late stages of the disease.^{12–14} Microscopy is not sensitive enough to identify many infections, especially those of low density and those where adult worms are present but produce no microfilariae. Serological testing is neither nor sensitive enough. It does not differentiate between past and current infection. Real-time and conventional polymerase chain reaction have been developed for the detection of *W. bancrofti* which are not routinely done at most centres.^{15,16} [Table 1]

Worldwide, multicellular helminth parasites are most commonly associated with significant eosinophilia, followed by adverse reactions to medication, toxins, allergic disorders, idiopathic autoimmune inflammatory conditions, and malignancies. Eosinophil blood count is highest among parasites with a phase of development that involves migration through tissue including schistosomiasis, visceral toxocariasis, strongyloidiasis, filariasis, ancylostomiasis, fascioliasis, trichinellosis, and paragonimiasis.^{14,17} Peripheral blood eosinophilia considered to be a useful diagnostic clue was also found to be absent in many of the reported cases. The absence of eosinophilia in these cases may be attributed to the oxidative stress associated with chronic and occult filariasis causing altered immune responses.^{18–20}

3. Conclusion

It is concluded that all the smears should be examined carefully to find such an incidental finding. It is also concluded that it is not necessary to find the clinical sign and symptoms of filariasis in every case. The association of filariasis in haematological malignancy is rare so it must be carefully looked for.

4. Source of Funding

None.

5. Conflict of Interest

None.

References

1. Arundhati, Kumar A, Kumar R. Acute Lymphoblastic Leukaemia with Microfilaria: A Rare Coincidence in Bone Marrow Aspirate. *Indian J Hematol Blood Transfus.* 2011;27(2):111–2.
2. Tyagi PSS. An Unusual Cause of Eosinophilia in AML-M4 without the Inv(16) Abnormality. *J Blood Disord Transfus.* 2010;01(01):104.
3. Sharma S, Rawat A, Chowhan A. Microfilariae in bone marrow aspiration smears; their correlation with marrow hypoplasia: a report of six cases. *Indian J Pathol Microbiol.* 2006;49:566–8.
4. Chatterjee KD. Parasitology in Relation to Clinical Medicine. 7th ed.; 1969.
5. Sabesan S, Vanamail P, Raju KK, Raju P. Lymphatic filariasis in India: Epidemiology and control measures. *J Postgrad Med.* 2010;56(3):232–8.
6. Sharma S, Rawat A, Chowhan A. Microfilariae in bone marrow aspiration smears; their correlation with marrow hypoplasia: a report of six cases. *Indian J Pathol Microbiol.* 2006;49:566–8.
7. Hemachandran M, Varma N, Varma S. Aplastic anaemia following a varicella infection with a coexistent microfilaraemia of Wuchereria bancrofti- a case report. *Indian J Pathol Microbiol.* 2003;46:662–3.
8. Deepa R, Sandip K, Shruti. Incidental finding of Microfilaria in blast crisis of Chronic myeloid leukemia - a rare entity. *Clin Pathol Res J.* 2018;2:1–2.
9. Molina MA, Cabezas MT, Giménez MJ, Sheno U, Pai RR, Pai U, et al. Mansonella perstans filariasis in an HIV patient: a finding in the bone marrow. *Haematol.* 1998;84(9):815–31.
10. Rosenblatt JE. Laboratory Diagnosis of Infections Due to Blood and Tissue Parasites. *Clin Infect Dis.* 2009;49(7):1103–8.
11. Panja M, Ganguly S, Kar AK, Chhetri MK. Atypical filariasis. *J Assoc Physicians India.* 1987;35(8):596–7.
12. Rocha A, Addiss D, Ribeiro ME, Noroes J, Baliza M, Medeiros Z. Evaluation of the Og4C3 ELISA in Wuchereria bancrofti infection: infected persons with undetectable or ultra-low microfilarial densities. *Trop Med Int Health.* 1996;1:859–64.
13. Rao RU, Atkinson LJ, Ramzy RM, Helmy H, Farid HA, Bockarie MJ, et al. A real-time PCR-based assay for detection of Wuchereria bancrofti DNA in blood and mosquitoes. *Am J Trop Med Hyg.* 2006;74(5):826–32.
14. Tefferi A. Blood eosinophilia: a new paradigm in disease classification, diagnosis, and treatment. *Mayo Clin Proc.* 2005;80:75–83.
15. Sharma S, Rawat A, Chowhan A. Microfilariae in bone marrow aspiration smears; their correlation with marrow hypoplasia: a report of six cases. *Indian J Pathol Microbiol.* 2003;46:662–3.
16. Pradhan S, Lahiri VL, Elhence BR, Singh KN. The microfilariae of Wuchereria bancrofti in bone marrow smears. *Am J Trop Med Hyg.* 1976;25:199–200.
17. Sheno U, Pai RR, Pai U, Nandi GK, Adhikari P. Microfilariae in bone marrow aspiration smears. *Acta Cytol.* 1998;42:815–6.
18. Pal BK, Kulkarni S, Bhandari Y, Ganesh BB, Goswami K, Reddy MVR. Lymphatic filariasis: possible pathophysiological nexus with oxidative stress. *Trans R Soc Trop Med Hyg.* 2006;100(7):650–5.
19. Chavarkar SP. Lymphatic filariasis: the importance of screening all peripheral blood smears in low power for detection of asymptomatic cases. *Int J Res Med Sci.* 2016;5(1):350–3.
20. Bari FS, Juliana FM, Fatema B, Islam MJ, Mannan MA, Asaduzzaman M. Impact of Lymphatic Filariasis (LF) on haemoglobin content and anemia: a cross-sectional based study. *J Health Med Nurs.* 2017;44:30–2.

Author biography

Iffat Jamal Assistant Professor

Ravi Bhushan Raman Assistant Professor

V N Choudhary Professor

Cite this article: Jamal I, Raman RB, Choudhary VN. Chronic lymphocytic leukaemia with microfilaria: A rare coincidence with review of literature. *Indian J Pathol Oncol* 2020;7(3):483-485.