



## Case Report

# Squamous cell carcinoma in mature cystic teratoma ovary: A rare case report

Aruna Gupta<sup>1</sup>, Garima Thapa<sup>1,\*</sup>, Kavita Kumari<sup>1</sup>, Bikram Shah<sup>1</sup>

<sup>1</sup>Dept. of Pathology, Dr. Rajendra Prasad Government Medical College, Kangra, Himachal Pradesh, India



### ARTICLE INFO

#### Article history:

Received 15-11-2019

Accepted 22-12-2019

Available online 25-05-2020

#### Keywords:

Mature cystic teratoma

Squamous cell carcinoma

### ABSTRACT

**Introduction:** Mature cystic teratoma is the most common benign ovarian tumour accounting for 20% cases among all ovarian neoplasm. It is a germ cell tumour. Malignant transformation of an epithelial component to squamous cell carcinoma is very rare phenomena accounting for only 2% of squamous cell carcinoma cases. In this case report, we are presenting two cases of squamous cell carcinoma arising in the mature cystic teratoma.

**Case Report:** Two women of age 62 and 47 years were presented to the gynaecology OPD with the complaints of distension and pain in the lower abdomen. On CECT abdomen of both the cases, there were solid cystic mass seen and the possibility of teratoma was suggested. On histopathologic examination, diagnosis of a mature cystic teratoma with a component of squamous cell carcinoma was offered.

**Discussion:** Mature cystic teratoma is frequently seen in young women. Malignant transformation in the setting of mature cystic teratoma is rare event and is more common among postmenopausal women.

**Conclusion:** Malignant transformation in mature cystic teratoma carries a poor prognosis and need to be treated aggressively. Early diagnosis and adjuvant chemotherapy is the only way to increase the chances of survival of the patient. Mature cystic teratoma, especially if it is presenting in post-menopausal women is alarming and should be viewed with a high degree of suspicion as there are more chances of malignant transformation.

© 2020 Published by Innovative Publication. This is an open access article under the CC BY-NC-ND license (<https://creativecommons.org/licenses/by/4.0/>)

## 1. Introduction

Teratoma is a common benign ovarian germ cell tumour accounting for 20% cases of all the ovarian tumours.<sup>1</sup> To make a diagnosis of teratoma structures derived from all the three or at least two well-differentiated germ cell component is needed. Teratoma can be seen at many sites but ovarian teratoma is one of the commonest tumour presented in the gynaecology department. On the basis of the component seen on histopathological examination ovarian teratoma are subdivided into, mature cystic teratoma, immature teratoma, monodermal teratoma and fetiform teratoma. Mature cystic teratoma being commonest of these. Amongst the three germ layers' derivatives of ectoderm and mesoderm are the commonest component. Although mature cystic teratoma is a benign condition, 2% of cases show

malignant transformation and most of them are squamous cell carcinoma.<sup>2</sup> Apart from squamous cell carcinoma adenocarcinoma, melanoma, neuroendocrine tumour etc. were also reported in the setting of mature cystic teratoma.<sup>3</sup> This malignant transformation is accompanied by complex chromosomal aberrations.<sup>4</sup> It carries a poor prognosis and different treatment than mature cystic teratoma and hence needs to be diagnosed early. Unfortunately, most of the early lesions are missed on radio imaging and picked up only when they start invading nearby structure and shows adhesion and solid area or papillary excrescences. Histopathological examination is the gold standard for the final diagnosis.

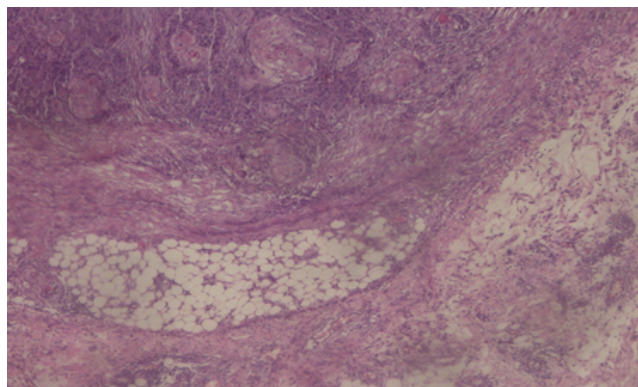
Here we are presenting two cases of squamous cell carcinoma arising in the mature cystic teratoma in postmenopausal women diagnosed postoperatively on histopathological examination.

\* Corresponding author.

E-mail address: [docshargarema@gmail.com](mailto:docshargarema@gmail.com) (G. Thapa).

## 2. Case Presentation

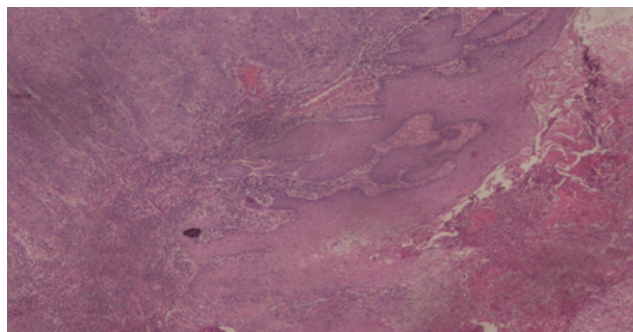
Our First case was a postmenopausal woman of age 47 years presented with the complaints of pain lower abdomen for the past 1 month. On clinical examination, an adnexal mass was felt on left side. Routine and specific examinations were carried out. On CECT, a cystic mass of 12 cm diameter seen and possibility of mature cystic teratoma was given. Trans Abdominal Hystrectomy with Bilateral Salpingo oophorectomy was done. Intraoperative findings showed left ovarian cyst with intact capsule and no adhesions were present. The sample was submitted for histopathological examination. Grossly the cyst of 13.8x11x10.8 cm received with smooth outer surface. Cut section showed-unilocular cyst was filled with sebaceous material and contain hair. There were solid and papillary areas also present. Microscopic examination showed –squamous cell lining, glands, adipose tissue, respiratory epithelium in a partially preserved ovarian stromal background. There were sheets of tumour epithelial cell replacing ovarian stroma. Tumour cells show features of well-differentiated squamous cell carcinoma. The report was signed out as squamous cell carcinoma arising in mature cystic teratoma (Figure 1).



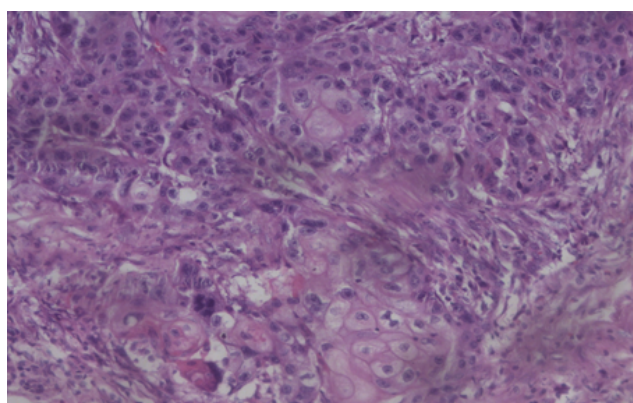
**Fig. 1:** Squamous cell carcinoma and adipose tissue in the ovary confirming the malignancy in mature cystic teratoma

The second case was a woman of age 62 years presented with the complaints of distension of abdomen from past 4-5 weeks. A mass was felt in the left adnexa. Routine and specific examinations were carried out. On USG a solid cystic mass identified and the possibility of Dermoid / Malignant tumour was suggested. Trans Abdominal Hysterectomy with Bilateral Salpingo-Oophorectomy was done. The intraoperative findings showed left ovarian cyst with dense adhesion on posterior aspect and omentum. The specimen was submitted for histopathological examination. Grossly a solid cystic tumour of 17x16x12 cm received with the irregular outer surface. Cut section showed multinodular cyst filled with sebaceous material and hair. The solid area with papillary excrescences also seen. On microscopic examination diagnosis of squamous cell carcinoma arising

in the mature cystic teratoma was given (Figures 2 and 3).



**Fig. 2:** Squamous cell carcinoma along with stratified squamous epithelial in the mature cystic teratoma ovary



**Fig. 3:** High 40 x view of squamous cell carcinoma arising from the stratified squamous epithelium in the ovary

## 3. Discussion

Mature cystic teratoma is a germ cell tumour of ovary having structures derived from all the three layers that are ectoderm, endoderm and mesoderm. As in 88% of cases, presenting cases were also unilateral. Both the patients in the present study were postmenopausal female which was similar to the study conducted by Hackethal et al.<sup>3</sup> Lesa dos Sentos et al in their study found mean age of 54.8 years which correlates well with the mean age of 54.5 years in present case.<sup>5</sup> Kikawa et al in their study observed that the mean size of the malignant teratoma was 152.3 mm. To consider the case as a malignant a criteria of (1) age more than 45 years and (2) tumour size of 99mm was given. Raised tumour markers were mandatory. In the present cases, the tumour size was 120mm and 170mm and the patient age was 47 years and 62 years respectively. This observation accredits with the study by Kikawa et al.<sup>6</sup> Takagi et al have studied tumour markers and found CEA to be a useful marker in malignant transformations.<sup>7</sup> Unfortunately preoperative serum markers were not done

in the present case. However, Hurwitz JL et al in their study observed the lack of usefulness of tumour marker preoperatively.<sup>8</sup> These malignant transformations carry poor prognosis than mature cystic teratoma and have different treatment which includes chemotherapy along with the surgery.

#### 4. Conclusion

Although mature cystic teratoma is common but its malignant transformation is extremely rare. It carries a poor prognosis and needs chemotherapy along with surgery. Clinicians, radiologists and pathologist should be aware of risk factors as early diagnosis is the only way to increase the survival of the patient. In our case report, we are highlighting certain factors that can be considered as risk factors for the malignant transformation of mature cystic teratoma. These risk factors are:

1. Post-menopausal women.
2. Size of the cyst > 10 cm.
3. Solid areas in the cyst.
4. Papillary excrescences in the cyst.
5. Presence of adhesions with the nearby structures.

#### 5. Source of Funding

None.

#### 6. Conflict of Interest

None

#### References

1. Schultheis AM, Ng CK, FilippoDe MR, Piscuoglio S, Macedo GS, Gatus S, et al. Massively parallel sequencing-based clonality analysis

- of synchronous endometrioid endometrial and ovarian carcinoma. *J Natl Cancer Inst.* 2016;108(6).
2. Comerci JT, Licciardo F, Bergh PA, Gregori C, Breen JL. Mature cystic teratoma: A clinicopathologic evaluation of 517 cases and review of the literature. *Obstet Gynecol.* 1994;84:22–30.
3. Hackethal A, Brueggmann D, Bohlmann MK, Franke FE, Tinneberg HR, Münstedt K. Squamous-cell carcinoma in mature cystic teratoma of the ovary: systematic review and analysis of published data. *Lancet Oncol.* 2008;9(12):1173–80.
4. Shen DH, Khoo US, Xue WC, Cheung ANY. Ovarian Mature Cystic Teratoma With Malignant Transformation An Interphase Cytogenetic Study. *Int J Gynecol Pathol.* 1998;17(4):351–7.
5. Santos LD, Mok E, Iasonos A, Park K, Soslow RA, Aghajanian C, et al. Squamous cell carcinoma arising in mature cystic teratoma of the ovary: a case series and review of the literature. *Gynecol Oncol.* 2007;105(2):321–4.
6. Kikaw F, Nawa A, Tamakashik. diagnosis of squamous cell carcinoma arising from mature cystic teratoma. *Cancer.* 1998;82:2249–55.
7. Takagi H, Ichigo S, Murase T, Ikeda T, Imai A. Early diagnosis of malignant-transformed ovarian mature cystic teratoma: fat-suppressed MRI findings. *J Gynecol Oncol.* 2012;23(2):125–8.
8. Hurwitz JL, Fenton A, McCluggage WG, McKenna S. Squamous cell carcinoma arising in a dermoid cyst of the ovary: a case series. *Int J Obstet Gynaecol.* 2007;114(10):1283–7.

#### Author biography

**Aruna Gupta** Assistant Professor

**Garima Thapa** Junior Resident

**Kavita Kumari** Senior Resident

**Bikram Shah** Senior Resident

**Cite this article:** Gupta A, Thapa G, Kumari K, Shah B. Squamous cell carcinoma in mature cystic teratoma ovary: A rare case report. *Indian J Pathol Oncol* 2020;7(2):309-311.