

# Interpretation of Bone Marrow Trepine Biopsies in Hematological Disorders with Special Emphasis on Morphological Patterns in Lymphomas

Gudeli Vahini<sup>1</sup>, I.V.Renuka<sup>2</sup>, P.Premalatha<sup>3</sup>, S.Indiradevi<sup>4</sup>, M.Atchyutha<sup>5</sup>, P.Krishna Divya<sup>6</sup>

<sup>1,5</sup>Assistant Professor, <sup>2,4</sup>Professor, <sup>3</sup>Professor & HOD, <sup>6</sup>Postgraduate, Department of Pathology, NRI Medical College, Chinakakani, Mangalgi

**\*Corresponding Author:**

E-mail: gudelivahini@yahoo.co.in

## ABSTRACT:

**Context:** Hematological disorders are seen in all age groups. Bone marrow trephine biopsy plays a major role in the diagnosis of underlying causes, in addition to staging and follow-up of hematological malignancies.

**Aims:** To study the trephine biopsies received in the department of clinical pathology with respect to age and sex incidence, to correlate with bone marrow aspirations, with special emphasis to its importance in cases where bone marrow aspiration yields a dry tap.

**Settings and Design:** 105 cases of bone marrow trephine biopsies performed in our institution over a period of one and a half years are included in the study.

**Methods and Materials:** A prospective study of 105 cases of bone marrow trephine biopsies was conducted. The biopsies were fixed in 10% buffered formalin solution and decalcified using 5% concentrated nitric acid for 4-6 hours, followed by routine processing. Serial sections were stained with Hematoxylin and Eosin (H and E), reticulin stains and Immunohistochemical markers in some.

**Results:** The majority of bone marrow biopsies showed reactive marrows (42 cases) followed by normal marrows (12 cases) and hypoplastic marrows (5 cases). Bone marrow biopsy showed involvement by leukemias in 11 cases (10.5%), lymphomas in 8 cases (7.6%), Myeloma in 6 cases (5.7%) and secondary deposits in 2 cases (1.9%). There were 5 cases of Megaloblastic anemia (4.8%), four cases of myelofibrosis (3.8%), two cases of idiopathic thrombocytopenic purpura (ITP) (1.9%) and one case each of aplastic anemia and autoimmune hemolytic anemia (0.9%). Out of 8 cases of Non Hodgkin's lymphomas - 3 (37.5%) showed nodular, 2 diffuse (25%), 1 (12.5%) interstitial pattern, 1 interstitial diffuse (12.5%) and 1 para trabecular pattern (12.5%) of marrow infiltration on trephine biopsy section. Nodular, interstitial and para trabecular patterns had good prognosis. Interstitial diffuse had intermediate prognosis and diffuse pattern had bad prognosis. There were 28 cases of dry tap in bone marrow aspiration and biopsy provided the clue in 18 cases. 5 cases in which bone marrow aspiration revealed a normal marrow study yielded a definitive diagnosis in bone marrow biopsies. 3 of them were lymphomas (NHL) with nodular pattern and two were metastatic deposits.

**Conclusions:** Examination of bone marrow biopsies increased diagnostic accuracy, hence contributing to prognosis especially in lymphomas and definitive targeted therapy. Only a biopsy provided a complete assessment of marrow architecture and pattern of distribution in case of infiltrative disorders like metastasis, lymphomas and was useful for special stains, Immunohistochemical stains.

**Key words:** Bone marrow, Trepine biopsy, Leukemia, Anemia, Bone marrow aspiration.

## INTRODUCTION

The spectrum of hematological disorders is varied in developing countries. In most cases the diagnosis can be arrived at by clinical examination, a complete blood examination and a few simple investigations. Bone marrow examination is considered as essential in conditions like Megaloblastic anemia, Idiopathic thrombocytopenic purpura, Leukemia, Lymphoma and Myeloma.

This study was conducted to evaluate bone marrow biopsies received in our department over a period of one and a half year. Special emphasis was given to those cases where bone marrow aspiration yielded a dry tap. Step sections of these biopsies aided in diagnosis of various conditions and helped to evaluate and stage leukemias and lymphomas.

We have described in detail the morphology and histopathological patterns of marrow involvement in these disorders. Bone marrow biopsy and aspiration were done from anterior iliac crest simultaneously. Bone marrow aspiration alone was done from sternum and tibia in some cases.

Although hemorrhage was rare following iliac crest aspiration and uncommon following trephine biopsy it was nevertheless the most frequently observed serious complication, sometimes

Access this article online	
Quick Response Code:	Website: www.innovativepublication.com
	DOI: 10.5958/2394-6792.2015.00024.1

requiring blood transfusion and occasionally leading to or contributing to death.

In a study of hundred patients in whom both techniques were applied, sternal aspiration was found to be technically easier and to produce a suitable diagnostic specimen more frequently, although on average the procedure was more painful both with regard to penetration and to actual aspiration.<sup>(1)</sup> Tibial aspiration was suitable for very small babies. Bone marrow aspiration caused only mild discomfort to the patient. A trephine biopsy caused moderate discomfort and in an apprehensive patient, sedation was used.

## SUBJECTS AND METHODS

105 cases of bone marrow biopsies were included in the study. The trephine biopsies were done under local anesthesia using the conventional technique using Jamshidi needle from the anterior iliac crest. Both bone marrow aspiration and biopsy were done simultaneously under aseptic conditions by trained pathologists. Minimum of one centimeter core biopsy was taken. Bilateral iliac crest biopsies were done in all suspected lymphomas and metastatic cases. Bone marrow aspiration was done from sternum in some and tibia for younger children.

**Exclusion criteria:** Patients with severe thrombocytopenia with platelet count less than 20,000/mm<sup>3</sup> or functional platelet defects, prolonged Prothrombin time, increased International normalized ratio (INR), severe bleeding and children below three years of age were excluded.

**Inclusion criteria:** Patients with platelet count above 20,000/mm<sup>3</sup>, no bleeding manifestations, normal prothrombin time and INR, children above three years of age were included.

The fixation was done with 10% formalin solution and decalcified using 5 % concentrated nitric acid for 4 to 6 hours followed by routine processing and paraffin embedding.

Serial sections 4 to 6 µm thickness were cut and stained by Hematoxylin and Eosin, reticulin stains in all cases of myelofibrosis, immunohistochemistry markers like pancytokeratin in some. In all bone marrow aspirates and needle biopsies informed consent was taken.

The relevant patient details including age, clinical findings and diagnosis, blood counts and peripheral smear findings were also studied. Sections of at least five well preserved marrow spaces were studied. We described in detail the morphology and histopathological patterns of marrow involvement of these disorders. Cellularity, hematological elements, presence of infiltration if any, the extent, histological pattern and morphology of infiltration including fibrosis were noted.

In lymphomas, the morphology and histological pattern of infiltration was categorized as diffuse, nodular, interstitial, focal, para trabecular, sinusoidal and mixed patterns.

## RESULTS

A total of 105 cases were subjected to bone marrow biopsy of which 77 cases had aspiration also. 98 cases we could conclude the diagnosis or provide clues to the disease process. 7 cases revealed a normal study. In the 105 cases studied, 55 were males and 50 were females. The age varied from 3 years to 80 years. Most of the cases were in the age group of 46 to 60 years that is 35 cases (33.3%).(Table 1)

The indications for performing biopsy in our study were varied. Most of the cases were fever of unknown origin 16 cases (15.23%), investigations of patients with Pancytopenia in 21 cases (20%) and in 26(24.76%) cases where bone marrow aspirate yielded dry tap. (Table2)

Other indications included evaluation and follow up of leukemias, staging of lymphomas, investigation of suspected myeloproliferative disorders, diagnosis of small round cell tumors of childhood, investigations of patients with suspected myeloma, investigation of patients with subleukemic leukemia, in leukoerythroblastic blood film, diagnosis of Aplastic anemia and in cases of metastasis. In the 105 bone marrow biopsies examined majority were reactive marrows comprising 42 cases (28%), Hypocellular marrows were seen in 5 cases (4.8%) and myelomas were (5.7%) 6 cases. All grades of myelofibrosis were in 4 cases (3.8%), Idiopathic thrombocytopenic purpura in 2 cases (1.9%) and Aplastic anemia in 1 case (0.9%). (Table 4)

Bone marrow biopsy diagnosed 2 cases of metastatic lesions where bone marrow aspiration revealed a normal study. (Table 3) There were 28 cases of dry tap in bone marrow aspiration and biopsy provided the clue in 18 cases. (Table5). 5 cases of normal study were diagnosed on bone marrow biopsy in which aspiration yielded a dry tap. 5 cases in which bone marrow aspiration revealed a normal marrow study yielded a definitive diagnosis in bone marrow biopsies. 3 of them were lymphomas (NHL) with nodular pattern and two were metastatic deposits.

## DISCUSSION

Bone marrow examination was an important investigation in the diagnosis of various hematological disorders. It was safe and relatively easy test to perform.<sup>(1)</sup> Both bone marrow aspiration and trephine biopsy had advantages and limitations. The two procedures were complementary to each other. Trephine biopsy was essential for diagnosis in cases of dry tap and blood tap in bone marrow

aspirations when the marrow was densely fibrotic or densely cellular. Only a biopsy provided a complete assessment of marrow architecture and pattern of distribution in case of infiltrative disorders.<sup>(2)</sup> In our study the most common age group undergoing bone marrow biopsy was 46-60 years (33.3%). In a study done by Pudasaini et al the most common age group was 31-40 years.<sup>(3)</sup>

Majority were reactive marrows constituting 42 cases (28%) in 105 (100%) bone marrow biopsies examined. In our study there were eight cases of lymphomas of which 4(50%) cases were diagnosed on bone marrow biopsy where aspiration yielded a dry tap. These were three cases of small lymphocytic lymphomas and one case of Non Hodgkin's lymphoma. Other four cases (50%) of lymphomas (two cases of small lymphocytic lymphomas and two cases of Non Hodgkin's) were diagnosed both on aspiration and biopsy sections. This was in variance with the results of Musoloni et al where 9.8% cases of lymphomas were positive on only aspiration.<sup>(4)</sup> In a series of 93 lymphoma cases, Foucar et al found that trephine sections and aspirate films were both positive in 79% of cases, trephine biopsy sections alone were positive in 3%.<sup>(5)</sup>

Similarly Conlan et al reported that in 102 cases of Non Hodgkin's lymphoma with marrow involvement, the trephine biopsy section, marrow clot section and marrow aspirate films were positive in 94%, 65% and 46% of Cases in only 6% of cases was the marrow aspirate positive when the trephine biopsy was negative.<sup>(6)</sup> This stressed the point that both aspiration and biopsy should be done in case of suspected lymphomas. Detection was also increased by serial sectioning of the biopsy specimens.<sup>(7)</sup> Examination of bone marrow trephine biopsy sections in Small lymphocytic lymphoma provided a valuable prognostic indicator which was partly independent of clinical stage. There were six major patterns of marrow infiltration either alone or in combinations as diffuse, focal, interstitial, nodular, paratrabeular and intrasinusoidal patterns on bone marrow biopsy studies done.<sup>(8,9,10)</sup>

Most investigators had demonstrated a statistically significant difference between the outcome in cases with diffuse pattern (poor prognosis) and those with non-diffuse (nodular and interstitial) patterns (good prognosis).<sup>(8,9,11)</sup> In our study two cases of small lymphocytic lymphomas had diffuse or packed marrow infiltration and both these patients had poor prognosis (Fig. 1). Interstitial and nodular patterns were seen in other two cases of small lymphocytic lymphomas and these patients had relatively good prognosis (Fig. 5 & 6). Some workers had further found cases with a mixed pattern to have prognosis intermediate between that of above two groups.<sup>(12)</sup> We noted one case of mixed pattern (diffuse interstitial) with intermediate

prognosis (Fig 2). Two cases of nodular infiltration of Non Hodgkin's lymphomas and one case of paratrabeular pattern in bone marrow biopsy had relatively good prognosis (Fig. 3 & 4).

Somewhat divergent findings were reported by Frisch and Bartl<sup>(10)</sup>; they also found the shortest survival in those with diffuse infiltration, but those with an interstitial pattern had a shorter survival than those with a nodular infiltrate. There were 11 cases of leukemias, 6 cases (54%) were diagnosed on bone marrow biopsy where aspiration yielded a dry tap. These were 3 cases of acute myeloid leukemia, two cases of acute lymphoblastic leukemia and one case chronic myeloid leukemia. Bone marrow histology was often a supplementary investigation in acute myeloid leukemia.<sup>(13,14,15,16)</sup> However was useful when peripheral blood features were not diagnostic and bone marrow aspiration was unsuccessful.

There were 3(100%) cases of myeloproliferative neoplasms which had both aspiration and biopsy. This was in contrast with the findings of Sitalakshmi et al where 18.75 % of cases revealed dry tap. The cause of increased number of dry taps in myeloproliferative disorders was due to the increased cellularity or increased fibrosis in the bone marrow (Fig 7).<sup>(17)</sup> In our study 2 cases of metastatic tumours (adenocarcinoma) were diagnosed on biopsy (fig 10&11). Our findings were almost similar to those of Nandu et al, Toi et al and Chandra et al.<sup>(18,19,20)</sup>

The greater diagnostic ability of bone marrow biopsy was due focal involvement of the bone marrow and increased fibrosis associated with metastasis.<sup>(21)</sup> Considering the small volume of tissue sampled, both bone marrow aspiration and trephine biopsy were relatively sensitive techniques for detecting bone marrow infiltration by metastatic tumors. In two autopsy studies which simulated biopsy procedures it is estimated that when osseous metastases were present, a bone marrow aspirate would give positive results in 28% of cases<sup>(22)</sup> and a single trephine biopsy in 35-45%. Trephine biopsy was more sensitive than bone marrow aspiration and sensitivity was increased in performing bilateral biopsies or by obtaining a single large biopsy specimen.

It was common for tumor cells to be detectable in trephine biopsy sections when none were demonstrable in the films of an aspirate.<sup>(23,24)</sup> The diagnosis of leukemia, myelofibrosis, Non Hodgkin's lymphoma, hypoplastic anemia, idiopathic thrombocytopenic purpura and myeloma was made by biopsy in cases of dry tap. We had 28 cases of dry tap. The incidence of dry tap in our study was similar to other studies.<sup>(25, 26)</sup>

There were five cases of Megaloblastic anemia diagnosed on bone marrow aspiration only, which were confirmed on biopsy (Fig no: 18). It was a well known fact that aspiration was better in

making out individual cell morphology whereas biopsy was useful in study of bone marrow architectural pattern and distribution.<sup>(27)</sup> This was the reason that early Megaloblastic change seen in an occasional erythroid cell was picked on aspiration and not in biopsy.

Bone marrow biopsy was recommended in multiple myeloma even if an adequate aspirate was

obtained, since was needed as a baseline to assess a post treatment response when no adequate aspirate is obtained.<sup>(28)</sup> There were six cases (5.7%) of myelomas in our study two of them were diagnosed on biopsy where aspiration yielded a dry tap (fig: 12,13,14). Bone marrow biopsy was done in all six cases as per the clinician's recommendations.

**Table 1: Age distribution of cases where bone marrow biopsy was done**

Age group	No. of patients	percentage
Less than 15yrs	8	7.6%
15-30yrs	20	19.0%
31-45yrs	29	27.6%
46-60yrs	35	33.4%
More than 60 yrs	13	12.4%
	105	100%

**Table 2: Indications for bone marrow biopsy**

No.	Indications for bone marrow biopsy	No.
1.	Evaluation of patient with dry tap in Bone marrow aspiration	26
2.	Investigation of patient with fever of unknown origin	16
3.	Investigation of Pancytopenia (to exclude Myelodysplastic syndrome)	21
4.	Staging of Non Hodgkin lymphoma/Hodgkin lymphoma	8
5.	Investigation of patient with suspected myeloma	8
6.	Evaluation and follow up of chronic lymphoid leukemia	6
7.	Diagnosis and staging of small cell tumors of childhood	5
8.	Investigation of leukoerythroblastic blood film	4
9.	Evaluation of patient with Acute myeloid leukemia	4
10.	Investigation of subleukemic leukemia	3
11.	Diagnosis of metastatic carcinoma	2
12.	Evaluation of chronic myeloid leukemia	1
13.	Diagnosis of Aplastic anemia	1

**Table 3: Comparative evaluation of incidence of bone marrow aspiration and bone marrow biopsies**

Diagnosis	Bone marrow aspiration	Bone marrow biopsy
Normal marrow	07	12
Reactive marrow	40	43
Hypoplastic marrow	05	05
Leukemia	05	11
Lymphoma	04	08
Metastatic deposits	00	02
Myeloproliferative neoplasm	03	03
Myeloma	04	06
Myelofibrosis	00	04
Megaloblastic anemia	05	05
Aplastic anemia	00	01
ITP	01	02
Miscellaneous	03	03
	77	105

**Table 4: Diagnosis in bone marrow biopsies**

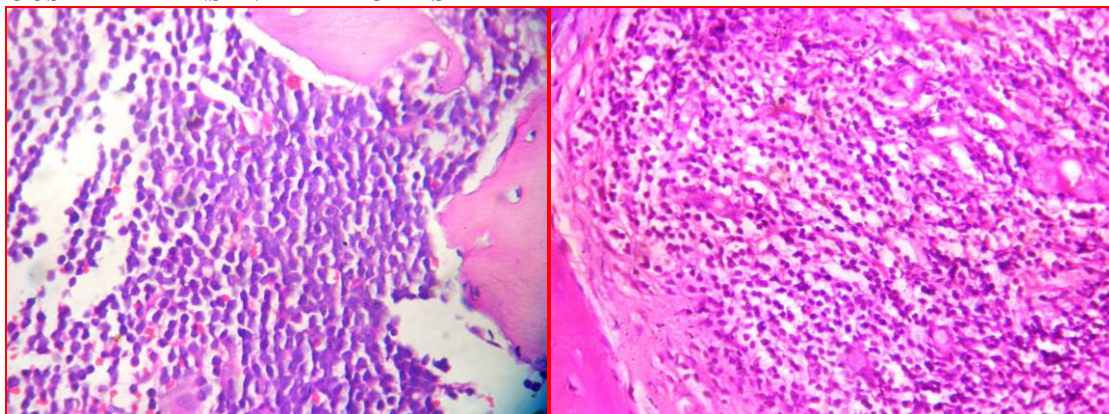
Bone marrow biopsy diagnosis	No. of cases	Percentage
Normal marrow	12	11.4%
Reactive marrow	42	28%
Hypoplastic marrow	05	4.8%
Leukemia	11	10.5%
Lymphoma	08	7.6%
Metastatic deposits	02	1.9%
Myeloproliferative neoplasm	03	2.8%
Myeloma	06	5.7%
Myelofibrosis	04	3.8%
Megaloblastic anemia	05	4.8%
Aplastic anemia	01	0.9%
ITP	02	1.9%
Miscellaneous	03	2.8%
	105	100%

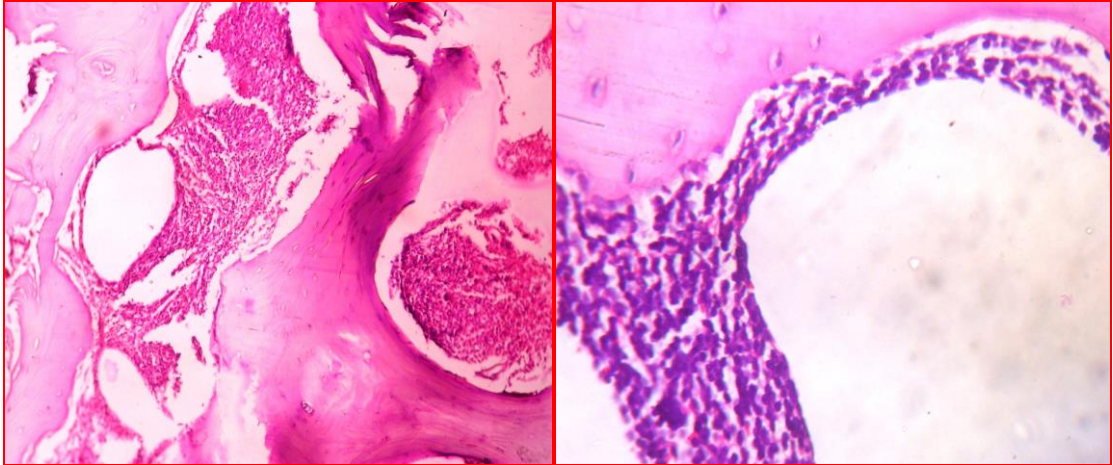
**Table 5: Bone marrow trephine biopsies diagnosed cases in dry tap.**

Biopsy diagnosis	cases	% BMA
Leukemia	6	21.4%
Lymphoma	4	14.3%
Myelofibrosis	4	14.3%
Normal marrow	5	17.9%
Reactive marrow	5	17.9%
Myeloma	2	7.2%
Aplastic anemia	1	3.5%
ITP	1	3.5%
Total cases	28	100%

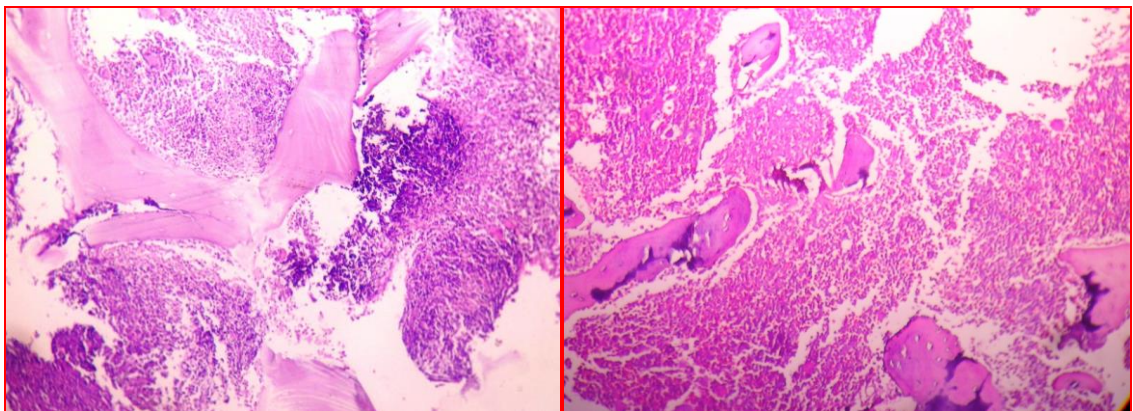
**Table 6: Bone marrow biopsy distribution patterns in lymphomas**

BMB Site	Diagnosis	Pattern of distribution
Bilateral iliac crest	Small lymphocytic lymphoma	Diffuse pattern
Bilateral iliac crest	Small lymphocytic lymphoma	Interstitial-diffuse
Bilateral iliac crest	Non Hogkin's lymphoma	Para trabecular
Bilateral iliac crest	Non Hodgkin's lymphoma	Nodular
Bilateral iliac crest	Non Hodgkin's lymphoma	Nodular
Bilateral iliac crest	Small lymphocytic lymphoma	Nodular
Bilateral iliac crest	Small lymphocytic lymphoma	Interstitial
Bilateral iliac crest	Small lymphocytic lymphoma	Diffuse

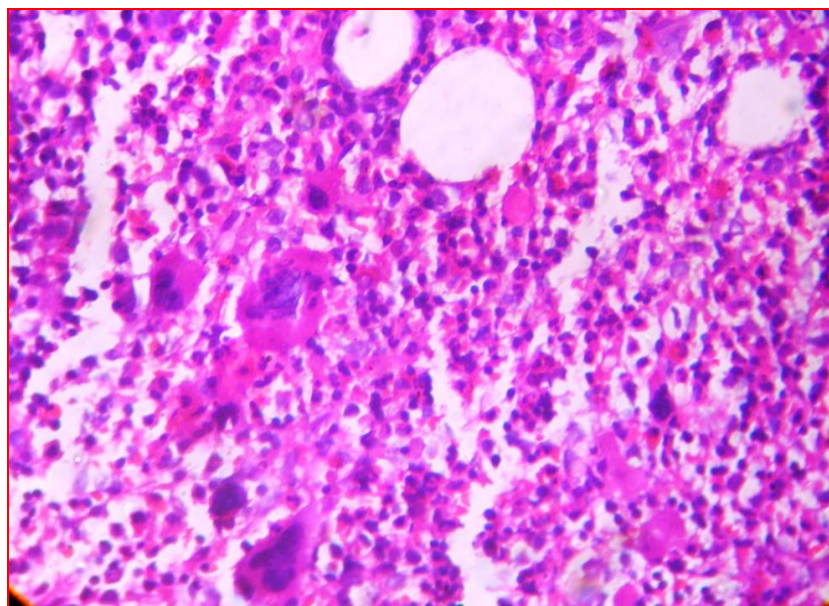
**VARIOUS PATTERNS IN LYMPHOMAS****Fig. 1 & 2: H&E 40X Diffuse pattern in Small lymphocytic lymphoma and Diffuse interstitial pattern**



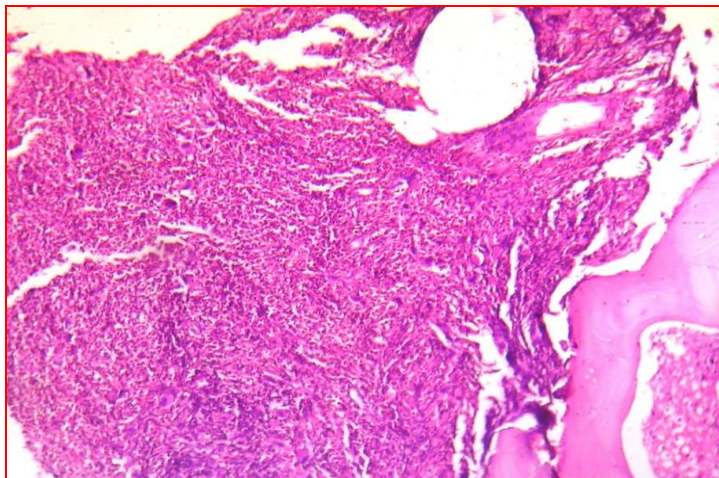
**Fig. 3 & 4: H&E 10X, 40X Para trabecular pattern in Non Hodgkin's lymphoma**



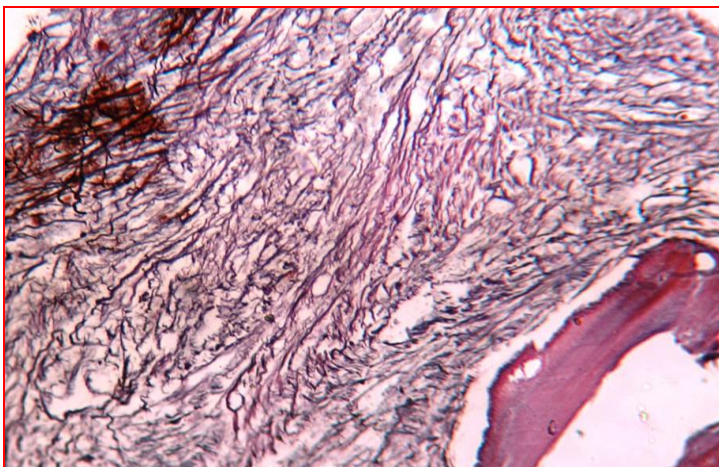
**Fig. 5 & 6: H&E 10X Nodular pattern in Non Hodgkin's lymphoma & interstitial pattern in Small lymphocytic lymphoma**



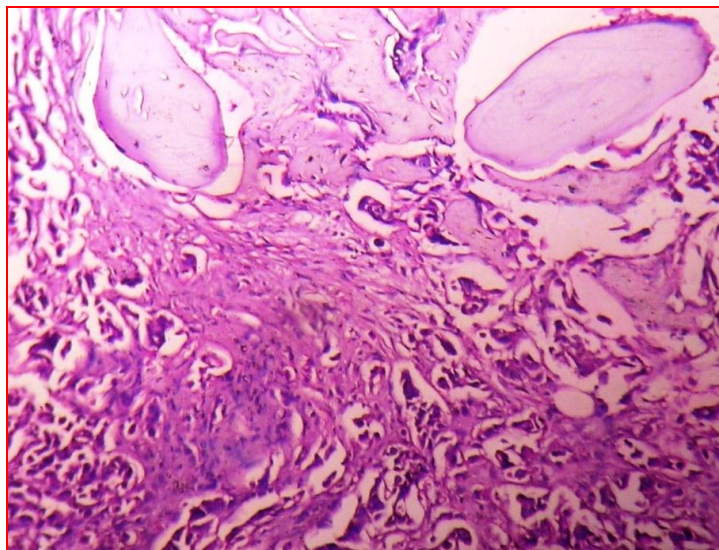
**Fig. 7: H & E 40X Myeloproliferative neoplasm**



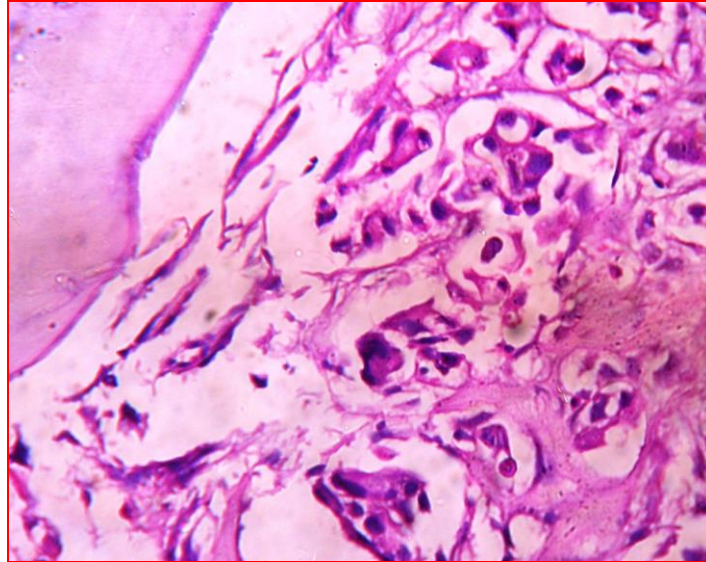
**Fig. 8: H&E 10X Myelofibrosis**



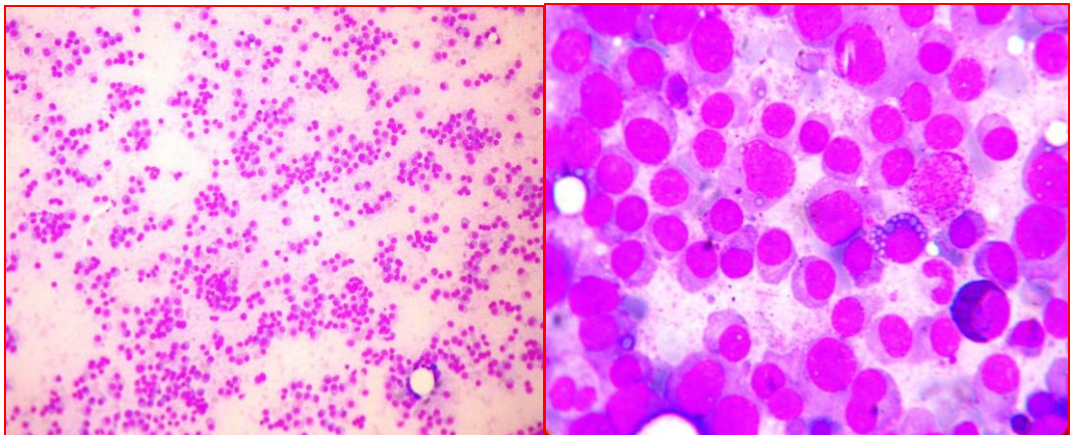
**Fig. 9: Reticulin stain 40X grade 3 positivity in myelofibrosis**



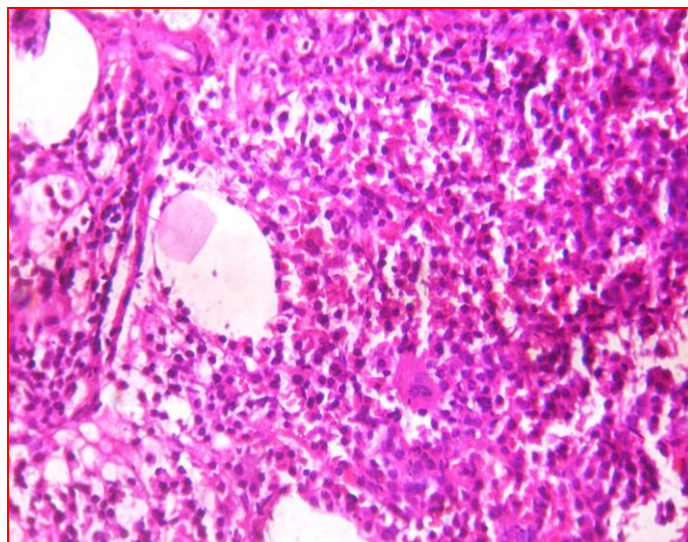
**Fig. 10: H & E 10 X Metastatic adenocarcinoma**



**Fig. 11: H&E 40X Metastatic adenocarcinoma.**

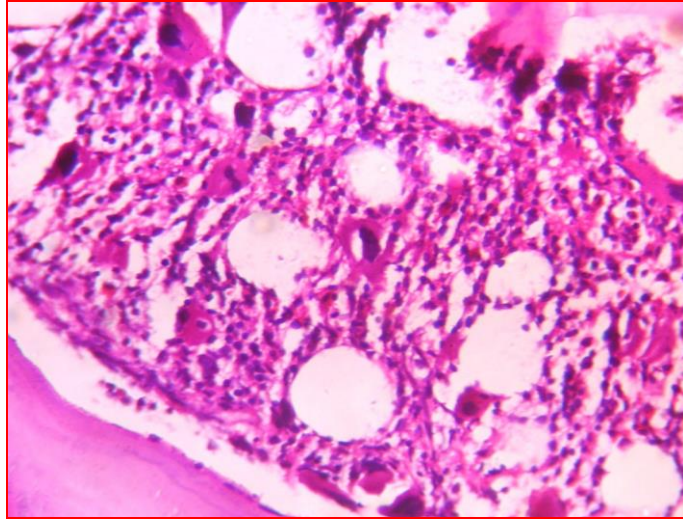


**Fig. 12, 13: Myeloma H&E 10X and 40X Mott cells**

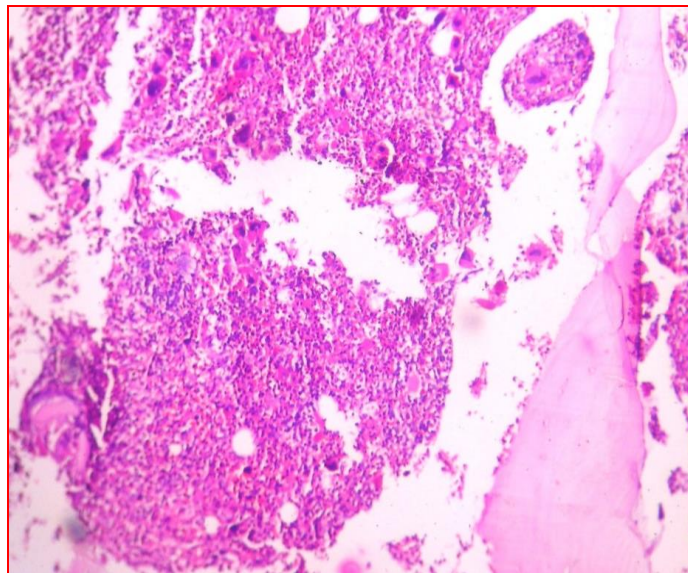


**Fig 14: Myeloma H&E Bone marrow biopsy 10X**

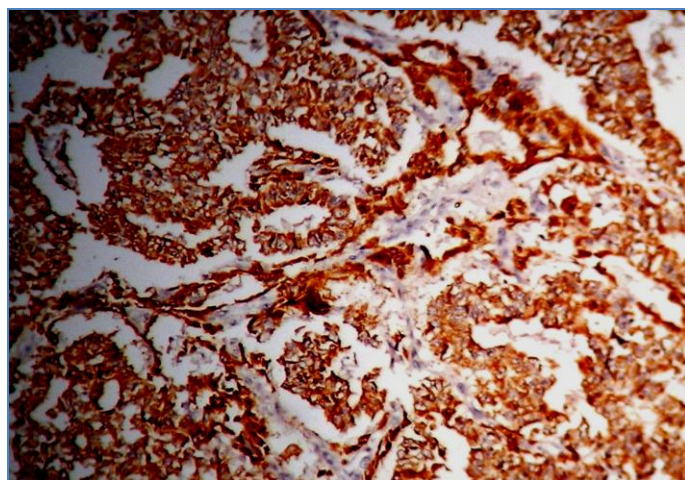




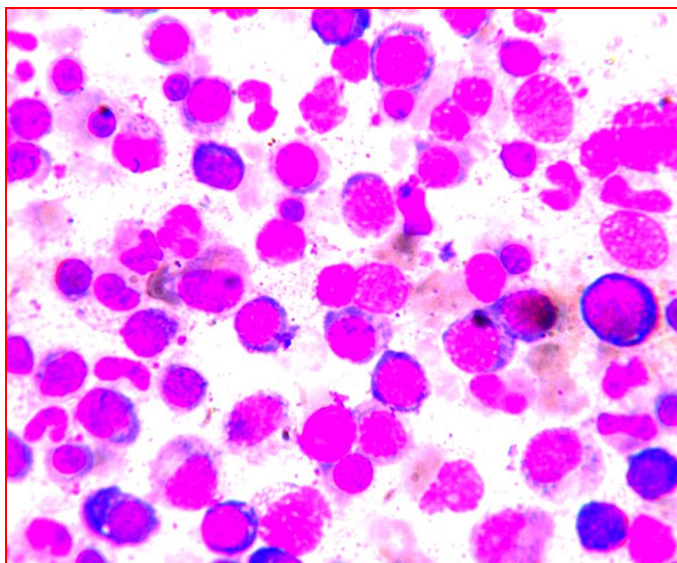
**Fig 15: ITP-H&E 40X**



**Fig. 16: ITP –H&E 10X**



**Fig. 17: Metastatic adenocarcinoma 40 X pancytokeratin positive.**



**Fig. 18: Megaloblastic marrow-H&E 40X**

## CONCLUSIONS

Bone marrow examination was an important investigation in the diagnosis of various hematological disorders. It was safe and relatively easy to perform. Trepine biopsy was extremely useful for diagnosis in cases of dry tap and blood tap in bone marrow aspirations and when the marrow was densely fibrotic or densely cellular. Bone marrow biopsy was particularly useful in investigation of patients with aplastic or hypoplastic anemia, lymphoma, metastatic carcinoma, myelofibrosis and myeloproliferative neoplasms. Only a biopsy provided a complete assessment of marrow architecture and pattern of distribution in case of infiltrative disorders like metastasis, lymphomas and was useful for special stains and Immunohistochemical stains.

Bone marrow biopsy proved to be of diagnostic value in our study just as in other studies. To conclude, it is the clinicians decision whether to do bone marrow aspiration alone or combine it with bone marrow biopsy depending upon clinical situation. Both are complimentary to each other as has been brought out in this study.

## ACKNOWLEDGEMENT

My special thanks to head of the department, all the professors, my colleagues and technicians working at NRI medical college pathology department for their encouragement to do this study.

## REFERENCES

1. B.J.Bain. Bone marrow trephine biopsy J. Clin.Pathol 2001; 54:10 737-742
2. Vidisha M, Vijay K, Surinder T, Rajni K. A comparative study of bone marrow aspiration and bone marrow biopsy in hematological and non hematological disorders –An institutional experience. JIACM 2013; 14(2): 133-5
3. Pudasaini S, Prasad KBR, Rauniyar SK, Shrestha R, Gautam K, et al Interpretation of bone marrow aspiration in hematological disorder. Journal of Pathology of Nepal 2012; Vol. 2: 309 -31230.
4. Muslino A et al. Accuracy and relative value of bone marrow aspiration in the detection of lymphoid infiltration in non Hodgkin lymphoma. Tumors, 2010; 96: 24-6
5. Foucar K, McKenna RW, Frizzera G and Brunning R. Bone marrow and blood involvement by lymphoma in relationship to the lukes-collins classification cancer 1982 ; 49:888-897.
6. Conlan MG, Bas M, Armitage JO and Weisenburger DD. Bone Marrow involvement by NHL: the clinical significance of morphologic discordance between lymph node and bone marrow. Nebraska lymphoma study group. J clin oncol 1990; 8-1172.
7. Campbell JK, Junega SK and wolf MM (1999) serial sectioning of the trephine biopsy increases the diagnostic accuracy of bone marrow involvement in diffuse large cell lymphoma. Blood 1990;9( suppl) ,243b.
8. Rozman C, Hernandez Nieto L, Montserrat E and Bruges R Prognostic significance of bone marrow patterns in chronic lymphocytic leukemia. Br J Haematol 1981; 47,529-537.
9. Rozwan C, Montserrat E, Rodriguez-Fernandez JM, Ayats R, Vallespi T, Parody Ret al (1984). Bone marrow histological Pattern - the best single parameter in chronic lymphocytic leukemia: a multivariate survival analysis of 329 cases. Blood,64,642-648.
10. Frisch B and Bartl R Histologic classification and staging of chronic lymphocytic leukemia. A retrospective and prospective study of 503 cases. Acta Haematol 1988; 79, 140-152.
11. Jamila H, Khalid Hassan. Pattern of Bone Marrow Infiltration in Non-Hodgkin's Lymphomas. JRMC; 2008; 12(2):66-71(1986).
12. Geiser C, Ralfkiaer E, Hansen MM, Housen –Jensen K and Larsen SO. The bone marrow histological pattern has independent prognostic value in early stage chronic lymphocytic leukaemia.Br J Haematol,62 ,47-54.

13. Islam A, Frisch B and Henderson ES (1989) Plastic embedded core biopsy: a complementary approach to bone marrow aspiration for diagnosing Acute myeloid leukemia. *J clin pathol* 42,300-306.
14. Islam A, catvosky D, Goldman JM and Galto DAG(1985), Bone marrow biopsy changes in acute leukemia. I :observations before chemotherapy. *Histopathology*.9, 939-957.
15. Islam A, catovsky D, Goldman J and Galton DAG (1984) Bone marrow fibre content in acute myeloid leukemia before and after treatment. *J clin Pathol*, 37, 1259-1263.
16. Wilkins BS, Bostanci AG, Ryan MF and Jones DB (1993). Hemopoietic regrowth after chemotherapy; an immunohistochemical study of bone marrow trephine biopsy specimens. *J clinic Pathol*, 46,915-92.
17. Sitalakshmi S, Srikrishna A, Devi S, Damodar P, Alexander B. The diagnostic utility of bone marrow trephine biopsies. *Indian J Pathol Microbiol* 2005; 48: 173-6.
18. Nanda A, Basu S, Marwaha N. Bone marrow trephine biopsy as an adjunct to bone marrow aspiration .*JAPI* 2002; 50:893-5.
19. Chandra S, Chandra H. Comparison of bone marrow aspirate cytology, touch imprint cytology, and trephine biopsy for bone marrow evaluation. *Hematol Rep* 2011 ;3:65-8.
20. Toi PC, Varghese RB, Rai R. Comparative evaluation of simultaneous bone marrow aspiration and bone marrow biopsy. An institutional experience .*Indian J Hematol blood transfusion* 2010; 26:41-4.
21. Bird AR, Jacobs P. Trephine biopsy of the bone marrow .*SA medical journal* 1983; 64:271-6.
22. Supurn H and Rywlin AM (1976) Metastatic carcinoma in histologic sections of aspirated bone marrow; a comparative autopsy study. *South Med J*, 69, 438-439
23. Ingle JN, Tormey DC and Tan HK (1978), The bone marrow examination in breast cancer. *Cancer*, 41,670-674.
24. Savage RA, Hoffman GC and Shaker K (1978) Diagnostic problems involved in detection of metastatic neoplasms by bone marrow aspirate compared to needle biopsy. *Am J clin Pathol*, 70,623-627.
25. Perez VU, Wilson RG, Alberto BA. Clinical significance of dry marrow Puncture or dry tap. *Rev Med Hered* 1997; 8:50-57.
26. Barua R, Rahman J, Tariquzzaman, Barua D. Histomorphological patterns in 50 bone marrow aspiration failure cases. *Bangladesh J Pathol* 2010; 25:18-22.
27. Ioannides K, Rywlin AM. A comparative study of histological sections of Bone marrow obtained by aspiration and by needle biopsy. *Am J clin Pathol* 1976;65:267-71.
28. Smith A, Wisloff F, Samson D, the UK myeloma Forum, Nordic myeloma study group and British committee for standards in Hematology (2006). Guidelines on diagnosis and management of multiple myeloma 2005. *Br J Haematol*, 132,410-451.