

## Primary renal teratoma: an important differential diagnosis in the evaluation of cystic renal masses in infants

Medhi Pranita<sup>1,\*</sup>, Dowerah Swagata<sup>2</sup>, Sharma Mahak<sup>3</sup>, Dutta Aparna<sup>4</sup>

<sup>1</sup>Associate Professor, <sup>2,3</sup>Demonstrator, <sup>4</sup>Assistant Professor, Department of Pathology, Assam Medical College and Hospital, Dibrugarh, Assam.

**\*Corresponding Author:**

E-mail: pranita\_medhi@yahoo.co.in

### ABSTRACT

Renal teratoma is an extremely rare condition and may create diagnostic confusion with teratoid nephroblastomas or retroperitoneal teratomas with secondary involvement of the kidney. We report a 35 day old female child presenting in paediatric surgery OPD with complaints of pain abdomen and abdominal distension. On palpation, a lump was felt in the lower abdomen measuring around 5x4x3 cms and a diagnosis of multilocular cystic nephroma was given on CECT abdomen. The kidney mass was excised and on gross examination, multiloculated thin walled cysts containing both mucinous and serous fluid with some areas of hemorrhage were noted. Microscopy revealed areas of columnar epithelium, squamous epithelium with keratin deposition, cartilage, bone, fibrocollagenous tissue and muscle tissue. A diagnosis of mature primary renal teratoma was given. This case was presented as primary renal teratomas are extremely rare and must be considered in the differential diagnosis of infantile renal masses.

**Keywords:** Renal Teratoma, Primary

### INTRODUCTION

Teratomas are neoplasms that arise from pluripotent cells and can differentiate along one or more embryonic germ lines.<sup>[1]</sup> Common sites of teratoma are sacrococcygeal, ovary, testicle, pineal gland, and the retroperitoneum. Renal teratoma is an exceedingly rare condition.<sup>[1]</sup> Most cases have been misdiagnosed as teratoid nephroblastomas or retroperitoneal teratomas secondarily invading the kidney.<sup>[2]</sup> Differentiation between these neoplasms often creates problems to the pathologist.

### CASE HISTORY

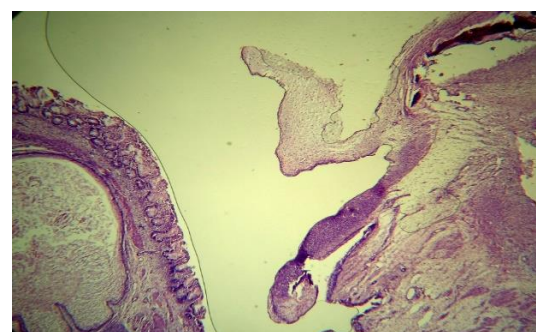
A 35 day old female child presented in paediatric surgery OPD with complaints of pain abdomen and abdominal distension. On examination, abdominal distension was noted. On palpation, a lump was felt in the right lower abdomen measuring around 5x4x3cms. CECT abdomen suggested a diagnosis of multilocular cystic nephroma. Renal and liver function tests as well as the findings of blood investigations were within normal limits. A chest radiogram showed no abnormality. The mass was excised and sent to Pathology department with the clinical differential of multilocular cystic nephroma, congenital mesoblastic nephroma, renal teratoma and Wilms tumor.

On gross examination, a soft tissue specimen measuring 5x3x3 cms with irregular surface was seen which was greyish white in colour (Fig-1). Cut section was solid-cystic with multiloculated thin walled cysts containing both mucinous and serous fluid with some areas of hemorrhage. H& E staining of the sections showed areas of columnar epithelium, squamous

epithelium with keratin deposition, cartilage, bone formation, fibrocollagenous tissue and muscle tissue (Fig-2a, 2b, 2c, 2d). A diagnosis of mature renal teratoma was given. Unfortunately, the patient died following the operation due to intraoperative haemorrhage leading to cardiorespiratory arrest and hence follow up was not possible.



**Fig 1:** showing gross appearance of the tumor



**Fig. 2(a):** Section showing areas of squamous epithelium, columnar glands and an area of bone formation (H & E, 10X)

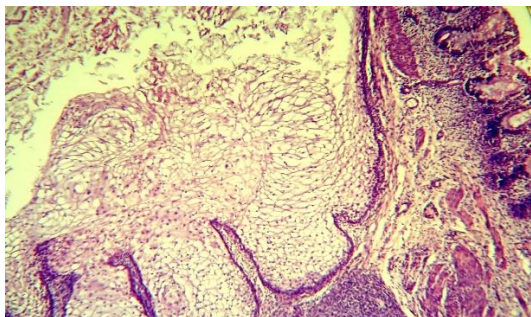


Fig. 2(b): Same under higher magnification (H&E, 40X)

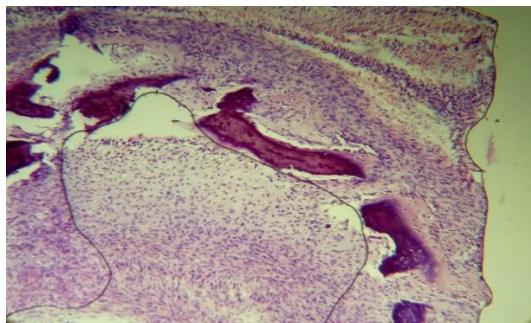


Fig. 2(c): Areas showing bone formation (H&E, 10X)

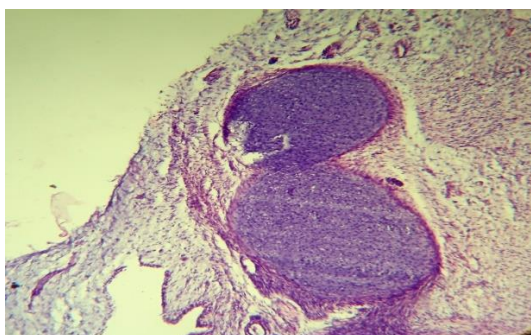


Fig. 2(d): An area showing cartilaginous tissue (H&E, 10X)

## DISCUSSION

Teratomas are rare neoplasms (incidence 0.7/100,000 children/year) with tissue derived from all three germ layers.<sup>[3]</sup> Teratomas are believed to have been present since birth, or even before birth, and are therefore considered as congenital tumors.<sup>[3]</sup> Teratomas and other germ cell tumors rarely originate primarily from kidney.<sup>[1]</sup>

In 1934, McCurdy described the first case of teratoma of kidney in a 7-week-old child with prune belly syndrome.<sup>[4]</sup> Since then, about 30 cases of primary intrarenal teratomas have been described in English literature.<sup>[5]</sup> The clinical complaints include a mass in the abdomen, abdominal pain and discomfort, pyelonephritis, and constipation.<sup>[6]</sup> Plain X-ray may show calcification or bony components like teeth. Serum alpha fetoprotein is an important marker for follow up to detect recurrence.<sup>[7]</sup> Hayasaka *et al.* have described that internal homogeneity, fat density; cyst formation and calcification are important predictors

of benign retroperitoneal tumor on computed tomography scan.<sup>[8]</sup>

S In mature teratoma presence of skin with dermal appendages, bronchial glands and cartilage, neuroglial tissue, teeth are regarded as evidence of organogenesis. Immature teratomas were found to contain neuroepithelial elements with an embryonic appearance and ependymal rosette-like structures.<sup>[9]</sup> Mature teratomas are usually benign and metastasis from intrarenal teratoma has not been reported till now. However, metastasis from mature teratoma of various other origins has been described.<sup>[10]</sup> Risk of malignancy is higher in children presenting in early age as compared to older children. So, surgical excision is justified. For a diagnosis of teratoma to be made, it is important for the pathologist to exclude two major differential diagnoses: (i) metastasis from a gonadal primary tumor and (ii) glomerular and tubular differentiation of nephroblastoma (Wilm's tumor). Teratomas are generally solid and avascular but when cystic, may sometimes be confused with cystic lesions of the kidney. Accurate diagnosis of these lesions is of utmost importance as complete excision of the tumor mass is the recommended treatment and there is no need to undergo anti-cancer drug therapy. This case was presented due to the fact that primary renal teratomas are extremely rare tumors; this entity must be considered in the differential diagnosis of infantile renal masses.

## REFERENCES:

1. Nirmal TJ, Krishnamoorthy S, Korula A. Primary intrarenal teratoma in an adult: A case report and review of literature. 2009; 25: p. 404-406.
2. Beckwith JB. Wilms' tumor and other renal tumors of childhood: a selective review from the National Wilms' Tumor Study Pathology Center. 1983; 14: p. 481-492.
3. Alexander M, Alexander K, Uta B, Holger T, Wolfgang H, Ivo L, Nicole S, Christian W, Thomas A. Mixed hepatoblastoma and teratoma of the liver in a 3-year-old child: a unique combination and clinical challenge. 2009; 4: p. 37.
4. Liu YC, Wang JS, Chen CJ, Sung PK, Tseng HH. Intrarenal mixed germ cell tumor. ; 164: p. 2020-1.
5. Yavuz A, Ceken K, Alimoglu E, Akkaya B. Mature cystic renal teratoma. 2014; 11: p. e11260.
6. Kyoko M, Yasuharu O, Yukiko T, Takashi K, Masahiko O, Akira K, Hiroyuki M, Mitsuru N, Tomayoshi H. Congenital intrarenal teratoma arising from a horseshoe kidney. 2006; 03: p. 019
7. Chaudhary A, Misra S, Wakhlu A, Tandon RK, Wakhlu AK. Retroperitoneal teratomas in children. 2006; 73: p. 221-3.
8. Hayasaka K, Yamada T, Saitoh Y, Yoshikawa D, Aburano T, Hashimoto H, et al. CT evaluation of primary benign retroperitoneal tumor. 1994; 12: p. 115-20.
9. Govender D, Nteene LM, Chetty R. Mature renal teratoma and a synchronous malignant neuroepithelial tumor of the ipsilateral adrenal gland. 2001; 54: p. 253-256.
10. Prasad SB. Intrarenal teratoma. Postgrad Med J. 1983; 59: p. 111-2.