

## PRIMARY MYXOID EPITHELIOID EXTRA-INTESTINAL GASTROINTESTINAL STROMAL TUMOR OF GREATER OMENTUM

Padmapriya K<sup>1,\*</sup>, Srinivasa Murthy V<sup>2</sup>, Sandhya Lakshmi BN<sup>3</sup>

<sup>1</sup>Junior Resident, <sup>2</sup>Professor and Head, <sup>3</sup>Assistant Professor, Department of Pathology, ESIC Medical College and PGIMSR, Rajajinagar, Bangalore 560010, INDIA.

**\*Corresponding Author:**

E-mail: padmakasukurti@gmail.com

### ABSTRACT

**Background:** Gastrointestinal stromal tumors (GISTs) are the most common mesenchymal neoplasms of the gastrointestinal tract believed to originate from interstitial cells of Cajal. Development of GISTs outside the gastrointestinal system, called as Extra-intestinal gastrointestinal stromal tumor (EGISTs) is rare. Incidence of primary GIST in the greater omentum has been reported to be <1%. Case report: A rare case of EGIST in an 89 year old woman, arising from the greater omentum is presented here. In this patient EGIST was primary and of epithelioid type with prominent myxoid change.

**Conclusion:** Recognition of myxoid epithelioid variant of EGIST is important as it is defined as a separate entity with availability of molecular targeted therapy.

**Key words:** Myxoid epithelioid EGIST, Greater omentum, Primary.

### INTRODUCTION

Gastrointestinal stromal tumors (GISTs), although rare of all gastrointestinal neoplasms, are the most common mesenchymal neoplasms of the gastrointestinal tract. Typically GISTs arise from the wall of the gastrointestinal tract and is believed to originate from interstitial cells of Cajal (ICC) or from their precursors in the gastrointestinal tract.<sup>1</sup> GISTs can occur anywhere along the gastrointestinal tract where ICC are present - the most common sites being the stomach (40-60%), small intestine (30-40%), anorectum (7%), colon and esophagus. Development of GISTs away from these sites i.e. outside the gastrointestinal system is rare and these are named as extra intestinal GISTs (EGISTs). EGISTs occur in the omentum, mesentery, retroperitoneum and account for <5% of cases.<sup>2</sup> The incidence of primary GIST in the greater omentum has been reported to be <1%, whereas on the other hand, metastasis from a GIST arising in the GIT to the omentum and mesentery is common.<sup>1,2</sup> EGISTs, like the conventional GISTs are histologically classified as spindle cell type (most common), epithelioid type, and mixed spindle and epithelioid type with expression of CD 117 protein, which is detected immuno-histo-chemically. Prominent myxoid change in an epithelioid GIST is a rare change and few authors have defined myxoid epithelioid GISTs as a distinct subtype of GISTs that are closely associated with PDGFRA gene mutations.<sup>3,4</sup> We present here a rare case of myxoid epithelioid GIST occurring primarily in omentum in 89 year old women.

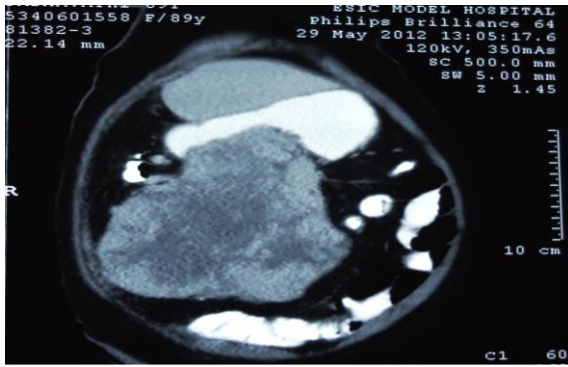
### CASE REPORT

An 89 year old woman presented with abdominal fullness for duration of two months. A

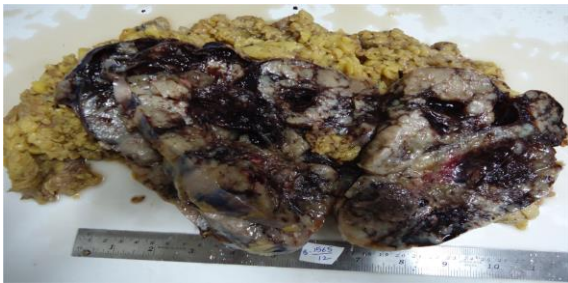physical examination revealed a firm, large abdominal mass, extending from the left hypogastrum to the umbilicus. An endoscopy of the GI tract showed a normal mucosal study. A computed tomography (CT) scan of the abdomen revealed a large, ill-defined and heterogeneous enhancing soft tissue exophytic mass arising from the omentum. (**Fig 1**) The mass was not adherent to any intra-abdominal structure. At laparotomy, a well encapsulated, large mass measuring 20 x 15 cm was found in the greater omentum. The tumour was completely resected and post-operative period was uneventful.

The specimen was grey white, lobulated and cystic measuring 20 x 15 x 10 cm and weighing 1.3 kg. External surface was congested. Cut surface showed solid, cystic hemorrhagic areas with large myxoid areas. (**Fig 2**)

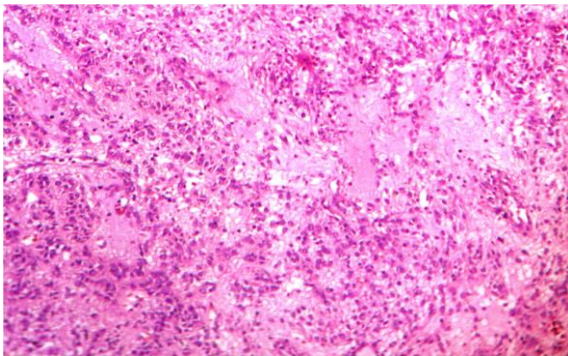
Microscopic sections showed a diffuse and nested pattern of tumour cells which were round to polygonal with a central vesicular nucleus and nucleoli. At places, these cells showed a clear cytoplasm. Areas of hemorrhage and myxoid changes were also seen. 1- 2 mitoses/50 high power fields were seen. (**Fig 3**) Immunohistochemistry showed c-KIT (CD117) to be strongly positive. (**Fig 4**) CD34 was focally positive. Vimentin was diffusely positivity. Tumour cells were negative for S100, desmin, smooth muscle actin, cytokeratin and HMB-45. A diagnosis of Myxoid Epithelioid GIST of the greater omentum was made based on the histological and immuno-histo-chemical findings. Patient has not turned up for follow up since her discharge.



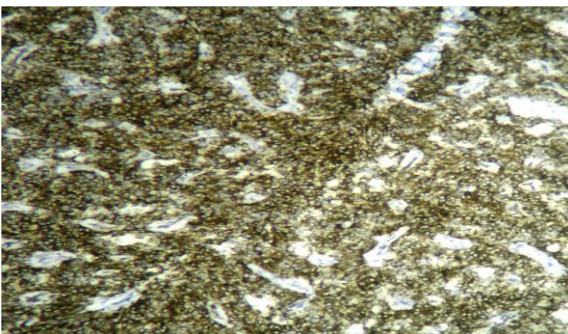
**Fig 1: Computed tomography scan of the abdomen: large, ill-defined and heterogeneous enhancing soft tissue exophytic mass.**



**Fig 2: Cut surface of tumor: solid and cystic with myxoid and hemorrhagic areas.**



**Fig 3: Microphotograph of EGIST – tumor cells in diffuse pattern with areas of myxoid change. (Hematoxyline and Eosin stain – 10X)**



**Fig 4: Microphotograph: CD 117 positivity of tumor cells (Immunohistochemistry – 10x)**

## DISCUSSION

Gastrointestinal stromal tumors (GISTs), the mesenchymal tumors arising commonly in the gastrointestinal tract and occasionally outside the GIT constitutes 1% of all GI malignancies.<sup>3</sup> These tumors are derived from interstitial cells of Cajal, the primitive stem cells that can differentiate into both interstitial cells of Cajal and smooth muscle cells and these tumors are defined by expression of CD 117 immune reactivity. It is now accepted that mutations in the kit receptor tyrosine kinase protein play a central role in the pathogenesis of GIST and likewise these lesions are designated as specific ckit expressing tumors and kit signaling driven mesenchymal tumors.<sup>5</sup>

Extra-intestinal Gastrointestinal stromal tumors (EGISTs) arise outside the GIT but share a similar morphological, immuno-phenotype and molecular genetic characteristics with GISTs.<sup>6</sup> EGISTs are rare and more aggressive compared to GISTs.<sup>6</sup>

Gastrointestinal stromal tumors in the omentum apparently arises from the normal CD 117/CD 34 positive mesenchymal cells, like the cells of Cajal, as reported by Sakurai ET al.<sup>4</sup>

Gastrointestinal stromal tumors have been reported in all age groups. However, they occur predominantly in adults, the median age being 60 years and shows a male predilection.<sup>7</sup> A literature survey by Fagkrezos et al states that the median diagnosis of omental GISTs is 65 years with an even male to female ratio. The authors further state that there is no difference in the occurrence of GIST between greater and lesser omentum.<sup>7</sup>

Most of the patients with omental GISTs show symptoms as these tumors are large. Miettinen et al and Reith et al state that only large tumors produce symptoms.<sup>8,9</sup> In our case, since the tumor was large, patient presented with symptoms. Since the tumors are large at initial diagnosis, the clinical symptom is often delayed. Imaging diagnostic modalities such as CT and MRI plays an important role in pre-operative diagnosis of EGISTs and in addition helps in obtaining material for guided aspiration/biopsies. Ortiz-Ryet et al underlines the importance of this imaging diagnostic modality in EGIST, especially in obtaining material for fine needle aspiration.<sup>10</sup>

Omental GISTs seem to be morphologically and immuno-histo-chemically identical to their gastric counter parts. Histologically they can be either spindle cell, epithelioid cell or can show a mixed pattern. Our case showed predominantly an epithelioid pattern. Generally EGISTs like GISTs shows a strong expression for CD117 and CD 34 immuno-histo-chemically. At times, expression of CD 117 may be weak or absent. Among the different types of GISTs, epithelioid GISTs are known to be

more often negative for CD 117 protein. However our case showed positivity to both CD 117 and CD 34. As suggested by all workers, we are also of the opinion that a combination of immuno-histo-chemical markers for c-kit and CD 34 are the most reliable markers for the diagnosis of EGISTs and GISTs.

One distinct feature about the present case is that the epithelioid variant showed a prominent myxoid change. Myxoid change in the stroma is a rare occurrence. Suster et al suggested that GIST with a myxoid stroma is a distinct morphological variant of myogenic GIST and needs to be differentiated from benign schwannoma of the stomach and Gastrointestinal Autonomic Neural Tumors (GANT).<sup>11</sup> The authors further mention that the myxoid change observed in these tumors probably represents a secondary, non-specific reaction pattern of the tumor cells to some noxious stimulus or it may be a form of degenerative phenomenon. We concur with the statements made by Suster et al that myxoid change represents a degenerative phenomenon.

Another interesting fact about myxoid epithelioid GISTs is that some of the workers have suggested it to be a distinct subtype of GIST that shows PDGFRA gene mutation.<sup>2</sup> The authors further mention that recognition of such subtle histological feature is necessary for molecular sub classification of GISTs that are important for molecular targeting therapy by imitinib mesylate, inspite of weak or negative expression of CD 117 on IHC. We stress that the need for PDGFRA gene mutation studies in all cases of myxoid epithelioid EGISTs. Unfortunately PDGFRA gene mutation analysis could not be done in our patient.

## CONCLUSION

Recognition of myxoid epithelioid variant of EGIST is important for two reasons: one, for weak/negative expression of CD 117 protein immuno-histo-chemically which may prevent its recognition; two, for the presence of PDGFRA gene mutation which enables the oncologist for use of imitinib mesylate as a molecular targeted therapy.

## REFERENCES

1. Basnet S and Lakhey A. Extra-intestinal Gastrointestinal Stromal Tumor of Omentum. *Journal of Pathology of Nepal* 2014; 4:682-684.
2. Murayama Y, Yamamoto M, Iwasaki R, Miyazaki T, Saji Y, Doi Y et al. Greater omentum gastrointestinal stromal tumor with PDGFRA mutation and hemoperitoneum. *World J Gastrointest Oncol* 2012; 4(5):119-124.
3. Kaur G, Manucha V, Verma K. Gastrointestinal Stromal Tumors: Cytomorphologic spectrum in fine needle aspiration smears. *Indian J Pathol Microbiol* 2010; 53:271-5.
4. Sakurai S, Hasegawa T, Sakuma Y, Takazawa Y, Motegi A, Nakajima T et al. Myxoid epithelioid gastrointestinal stromal tumor (GIST) with mast cell infiltrations: A subtype of GIST with mutations of platelet derived growth factor receptor alpha gene. *Hum pathol* 2004; 35:1223-30.
5. Todoroki T, Sano T, Sakurai S, Segawa A, Saitoh T, Fujikawa K, Yamada S et al. Primary omental Gastrointestinal stromal tumor (GIST). *World Journal of Surgical Oncology* 2007; 5(66):1-5.
6. Reith JD, Goldblum JR, Lyles RH, Weiss SW. Extra gastro intestinal (soft tissue) Stromal Tumors; An analysis of 48 cases with emphasis on histologic predictors of outcome. *Mod Pathol* 2000; 13(5):577-85.
7. Fagkrezos D, Touloumis Z, Giannila M, Penlidis C, Papapaskeva K, Triantopoulou C. Extra-gastrointestinal stromal tumor of the omentum: a rare case report and review of the literature. *Rare Tumors* 2012; 4(3):e44.
8. Miettinen M, Lasota J. Gastrointestinal stromal tumors-definition, clinical, histological, immuno-histo-chemical and molecular genetic features and differential diagnosis. *Virchows Arch* 2001; 438:1-12.
9. Reith JD, Goldblum JR, Lyles RH, Weiss SW. Extra gastro intestinal (soft tissue) Stromal Tumors; An analysis of 48 cases with emphasis on histologic predictors of outcome. *Mod Pathol* 2000; 13(5):577-85.
10. Ortiz-Rey JA, Fernandez GC, Magdalena CJ, Alvarez C, Anton I, San Miguel P, et al. Fine needle aspiration appearance of extra gastro intestinal stromal tumor: A case report. *Acta Cytol.* 2003; 47(3):490-4.
11. Suste D, Sorace D, Moran CA. Gastrointestinal stromal tumors with prominent myxoid matrix. Clinico-pathologic, immuno-histo-chemical and ultra-structural study of nine cases of a distinct morphologic variant of myogenic stromal tumor. *Am J Pathol* 1995; 19:59-70.