

## Histopathological spectrum of lesions in women with postmenopausal bleeding

Vidya Vasudev<sup>1,\*</sup>, Geetha S<sup>2</sup>, Rejani K.<sup>3</sup>, Bharthi. M<sup>4</sup>

<sup>1</sup>Assistant Professor, <sup>2</sup>Post Graduate, <sup>3</sup>HOD, Dept. of Pathology, Mysore Medical College & Research Institute Karnataka, India

**\*Corresponding Author:**

Email: vidyammcri@gmail.com

Received: 23<sup>rd</sup> September, 2017

Accepted: 15<sup>th</sup> February, 2018

### Abstract

**Introduction:** Postmenopausal bleeding is regarded as an ominous and serious alarm of genital pathology. It is a symptom having various etiology and has a strong association with malignancy, which demands its thorough evaluation.

**Aims and Objectives:** The present study was carried out to know the causes of postmenopausal bleeding based on histopathology and the percentage of various benign premalignant & malignant lesions in postmenopausal bleeding. The association with age was also studied.

**Methodology:** This study included 139 specimens received in in Department of Pathology MMC & RI Mysore, with history of postmenopausal bleeding, from January 2013 to December 2014.

**Results:** Mean age of the patients in the study was 57 years. Cervical biopsy was most common biopsy received (43.8%). Benign cases were 51.6%, malignant cases 36.07% and premalignant lesions were 9.27%. Among the benign lesions atrophic endometrium was most common (11.2%). Cervical cancer was most common (33%) among malignancy.

**Conclusion:** Any patient presenting with history of postmenopausal bleeding should be investigated thoroughly to determine the cause of bleeding. Cervical lesions are still the most common cause postmenopausal bleeding so screening programme should be effectively implemented.

**Keywords:** Postmenopausal bleeding, Histopathology.

### Introduction

Menopause is taken from the Greek word “Meno” (month) & “pause” means stop. Menopause occurs physiologically in women who are about the age of 50.<sup>1</sup> Most women all over the world attain menopause at 45-55yrs with the average age 51 yrs.<sup>2</sup> Vaginal bleeding which occurs after one year of amenorrhea in a woman of the age in which menopause can be expected is defined as postmenopausal bleeding.<sup>3</sup> In gynecological practice PMB represents for 5% of cases.<sup>4</sup> Cancer is an important cause of this abnormal bleeding, with the dictum is that postmenopausal bleeding indicates malignancy until proven otherwise.<sup>5-17</sup> The dictum is that postmenopausal bleeding always indicates malignancy until proven otherwise.<sup>11</sup> In postmenopausal women with vaginal bleeding the probability of endometrial carcinoma is approximately 10%.<sup>18</sup> Malignant tumors account for 7-49% of cases of PMB and this depends on racial, genetic, ethnic differences in incidence of malignancy in diverse population as well as to different criteria adopted by different studies. The present era life expectancy of women have increased & most will experience the postmenopausal phase. The chances of malignancy increases with increase in age of onset of PMB. Most studies on PMB are based on endometrial biopsies. Since few of studies describing the histological spectrum of lesions in entire genital tract the present study was undertaken to examine the lesions in genital tract in cases of PMB.

### Aims and Objectives

The present study was carried out to know the causes of postmenopausal bleeding based on histopathology and the percentage of various benign premalignant & malignant lesions in postmenopausal bleeding. The association with age was also studied.

### Materials and Methods

The present study was conducted for a period of 2 years from January 2013 to December 2014 at Department of Pathology, MMC&RI. Material for study was collected from endometrial, cervical, vaginal, vulval biopsies and hysterectomy specimens which were sent for histopathological examination to Department of Pathology from clinically diagnosed cases of postmenopausal bleeding. The History noted were spotting per vagina, brownish discharge, scanty flow and moderate to profuse bleeding. Premature menopause whether surgical or natural, with age <40yrs and patient on hormonal replacement therapy/on anticoagulant/having bleeding disorders were excluded from the study. After the collection of detailed data, the specimens were examined grossly. Specimens were fixed in 10% buffered formalin. Sections were processed and stained with H & E. Slides were examined under microscope and observations were done. The results were compiled, analysed using proportion and compared with other studies.

## Results

The study comprised of 139 cases which met the inclusion criteria were taken for this study. Age of the patients with post menopausal bleed (Table 1) ranged between 41-80 years with the mean age of 57yrs. The maximum number of cases 36(25.8%) were between the age group of 46-50 years. The most common site biopsy received were from cervix, 61(43.8%). (Table 2)

Postmenopausal bleeding was due to benign causes in 78 cases (51.6%). (Table 3) Atrophic endometrium was the commonest benign cause comprising total 19 cases (11.7%). Proliferative endometrium 15 cases (9.2%), endometrial hyperplasia without atypia 11 cases (6.7%), cervicitis 6 cases (3.7%), cervical polyp 6 cases (3.7%), endometrial polyp 5 cases (3%), adenomyosis 3 cases (1.55%), leiomyoma 3 cases(1.55%) and one case of endometritis (0.6%) & one case of prolapse(0.6%). Inadequate samples were 11 cases (6.7%).

Most of the malignant tumors were from the cervix 55 cases (33%) (Table 3) followed by uterine malignancy 15 cases (9.2%), Carcinoma vulva 3 cases (1.85%), Carcinoma vagina 2 cases (1.23%). The ratio

of malignant tumor in cervix to those in uterus was 2.9:1 (Table 4). Among the malignant lesions squamous cell carcinoma was the most common 46 (28.35%). The number of benign lesions added up to more than 100% as these lesions overlapped that is one specimen had more than one lesion.

**Table 1: Distribution of study subjects according to age groups**

AGE (years)	No of study subjects	Percentage
41-45	11	7.9
46-50	36	25.8
51-55	28	20.1
56-60	26	18.7
61-65	18	12.9
66-70	13	9.3
>70	6	4.3
>80	1	0.7
Total	139	100

**Table 2: Type of specimens received**

Type of specimen	Numbers	Percentage
Biopsy vulva and vagina	4	2.83
Biopsy cervix	61	43.8
Biopsy cervix and endometrium	13	9.3
Endometrial curettage	42	30.2
Hysterectomy	7	5.03
Hysterectomy with adnexa	11	7.9
Hysterectomy with adnexa, omentum and lymph nodes	1	0.7
Total	139	100

**Table 3: Distribution and percentage of various lesions**

S. No	Histopathology diagnosis	Number	Percentage
1	Indequate	11	6.7
2	Cervicitis	6	3.7
3	Cervical polyp	6	3.7
4	Atrophic endometrium	19	11.7
5	proliferative endometrium	15	9.2
6	Endometrial hyperplasia without atypia	11	6.7
7	Endometrial hyperplasia with atypia	3	1.85
8	Endometrial polyp	5	3
9	Endometritis	1	0.6
10	Adenomyosis	3	1.85
11	Leiomyoma	5	3
12	Prolapse	1	0.6
13	Carcinoma cervix(total)	55	3
	CIN	11	6.7
	SCC	42	25.9
	Undifferentiated	2	1.23
14	Malignant Uterus (Total)	15	9.5
	Adenocarcinoma	10	6.2
	Adenosquamous carcinoma	2	1.2

	Papillary Serous Carcinoma	2	1.2
	MMMT	1	0.6
15	Carcinoma Vulva (SCC)	3	1.85
16	Carcinoma Vagina (SCC and Adenocarcinoma)	2	1.23
	Total	162	100

**Table 4: Distribution of lesions**

S. No	Histopathology	Number of cases	Percentage
1	Benign	78	51.6
2	Malignant	59	39.07
3	Premalignant	14	9.27
	Total	151	100

## Discussion

PMB means bleeding from genital tract occurring in postmenopausal women after 12 months of amenorrhea in a women of postmenopausal age.<sup>19</sup> PMB is frequent and accounts for 5% of gynecological presentations.<sup>4</sup> In PMB the incidence of malignancy is very high, so it requires immediate investigations for early diagnosis, follow up and prompt treatment. In present era life expectancy has increased and women tend to live longer and many will experience the postmenopausal phase. PMB is a very alarming sign that may be associated with cervical or uterine malignancy.

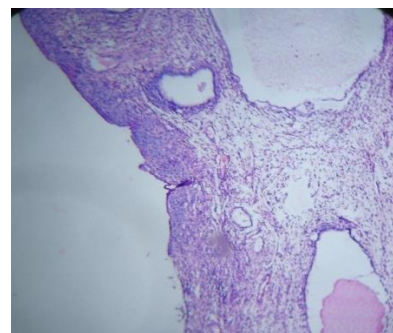The investigations and assessment is moving away from operation theatre, ward environment into outpatient department. However the primary assessment in all cases of PMB should be trans vaginal ultrasound scanning(TVS) as the thickening of endometrium may indicate significant pathology.<sup>20</sup> The present trend in investigating only lesions with PMB when endometrial thickness is >4mm as measured by ultrasound.<sup>21</sup> However the authors have recommended systematic collection of biopsies from symptomatic patients<sup>22</sup> because there have been reports of cancer in patients presenting with ultrasound measured endometrial thickness <5mm.<sup>23</sup>

In the present study it was noted that maximum number of cases that is (25.8%) were in the age group of 46-50 years while minimum number of cases(7.9%) were in 41-45 yrs. In the present study age range was from 41-80 yrs while the study done by Way sf et al, Sousa R et al, Bharani B et al and Sheikh M et al was 38-94, 43-82,52-65, 42-84 yrs respectively.<sup>24-27</sup>

Mean age of the present study was 57yrs whereas in other studies it was 47.43 to 56.5yrs.<sup>28</sup> It was also noted that as the age of subjects increases the incidence of PMB decreases which shows an inverse relationship between age and age of PMB. In study done by Gredmark T et al, the number of cases of PMB decreased with increasing age.<sup>16</sup>

In this present study 139 samples were received which were biopsy specimens from cervix,

endometrium, vulva, vagina and hysterectomy specimens. Benign conditions were 51.6%, malignant 39.07% and premalignant 9.27%. (Table 5) Benign conditions included cervicitis, cervical polyp, atrophic endometrium, proliferative endometrium without atypia, endometrial polyp, endometritis, adenomyosis, leiomyoma and prolapse. It was noted that atrophic endometrium (Fig. 1) was the most common histological lesion in benign conditions that is 19 cases (11.7%), followed by proliferative endometrium 15 cases (9.2%). (Table 6) But atrophy was found to be 49.9% by Gredmark et al,<sup>16</sup> 52% by Lee WH et al,<sup>12</sup> 16.3% by Naik et al,<sup>11</sup> 32% by Cheema et al.<sup>2</sup> The probable explanation for unexplained bleeding from atrophic endometrium are fluctuation of serum levels of estrogen, nonspecific chronic endometritis, sclerotic degeneration of myometrial arterioles, associated diabetes mellitus & hypertension, uterus prolapse causing passive congestion& bleeding, rupture of endometrial cysts.<sup>29</sup>

**Fig. 1: Atrophic endometrium(H&E x 10x)**

In the present study it was noted that proliferative endometrium was in 15 cases (9.2%) which is comparable to study of Naik et al<sup>11</sup> who found it to be 8.6% and Cheema et al 8%.<sup>2</sup> Choo YC et al found out that stimulation of postmenopausal endometrium can occur because of conversion of adrenal androsteinedione by peripheral fat to estrogen which leads to proliferative endometrium and also fluctuation of low level of estrogen results in bleeding from proliferative endometrium.<sup>30</sup>

**Table 5: Ratio of cervical and uterine cancer in different studies**

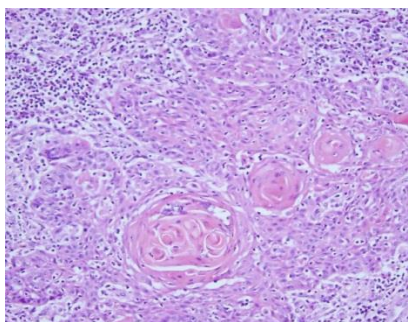
Study	Ratio of cervical and uterine carcinoma
Lee et al	1.2:1
Tyagi et al	2.6:1
Present study 2015	2.9:1

**Table 6: Distribution of various lesions in different studies**

	Lee 1995	Gredmark 1995	Naik 2005	Cheema 2008	Tyagi 2010	Present Study
Ca vagina and vulva	0.6				4.3	1.23
Ca cervix	12.9		39	14	34.5	33
Ca uterine	11	8	9.6	10	13	9.2
Ca ovary	1.2		0.96	6	5.5	
Cervicitis	12.9		2.8	68	2.1	3.7
Polyp	6.7	9		16	16	3
Proliferative endometrium		4	8.6	8	1.5	9.2
Secretory endometrium		1		14	1.2	
Atrophic endometrium		50	16.3	32	2.4	11.7
Endometrial hyperplasia	3.1	10	13.4	2	4.9	8.5
Leiomyoma	4.3				1.8	1.85
Endometritis	1.2					0.6
Inadequate	24.5	14		4	5.2	6.7

In endometrial polyp bleeding can be as a result of injury to thin walled vein below surface epithelium or thrombosis of the vessels. The bleeding in leiomyoma can occur due to congestion or atrophy & thinning of overlying endometrium and myometrium results in ulceration and bleeding.<sup>31</sup>

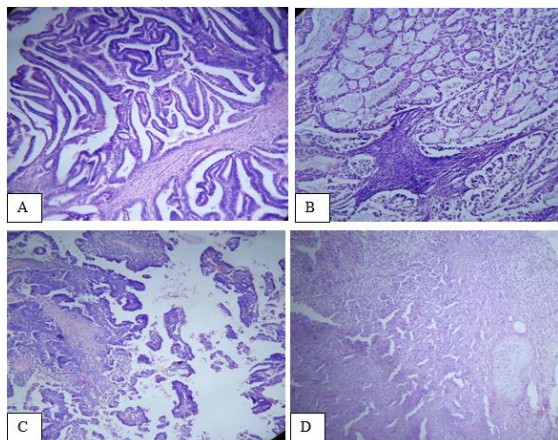
PMB due to malignant and premalignant cases in present study was 48.2% (Table 7) which is comparable with Naik et al<sup>11</sup> 49% and Tyagi et al<sup>31</sup> 58.5%. Other studies were Gredmark et al<sup>16</sup> 15%, Lee et al<sup>12</sup> 25.8% and Cheema et al<sup>2</sup> 30%. The ratio of cervical to uterine cancer was 2.9:1 similar to Tyagi et al<sup>31</sup> 2.6:1 and Lee et al<sup>12</sup> it was 1.2:1. Cervical cancer was responsible for 33% of PMB, squamous cell carcinoma was the most common cancer (25.9%). (Fig. 2)

**Fig. 2: Well differentiated Squamous cell carcinoma of cervix (H&E x40x)****Table 7: Incidence of malignant tumors in case of postmenopausal bleeding**

Study	Malignant lesions
Gredmark et al	15
Lee et al	25.8
Naik et al	49.1
Cheema et al	30.0
Tyagi et al	58.5
Present Study	48.2

Hence cervical cancer is almost thrice as common as endometrial cancer in our study of women with postmenopausal bleeding. These results support the fact that the diagnostic focus in our country with history of PMB should be towards excluding cervical pathology.

In this study endometrial adenocarcinoma is the most common (9.2%) cause of PMB after cervical carcinoma which was similar to Naik et al<sup>11</sup> 9.6%. Other studies were Gredmark et al<sup>16</sup> 8%, Cheema et al<sup>2</sup> 10%, Lee et al<sup>12</sup> 11%, Tyagi et al<sup>31</sup> 13%. Histologically 12 cases (7.4%) were there of adenocarcinoma in which 9 (5.4%) were endometrioid adenocarcinoma, 2 cases (1.2%) were papillary serous adenocarcinoma and 1 (0.6%) case was endometrioid carcinoma with mucinous differentiation. Also reported was one case of MMT (0.6%). (Fig. 3)



**Fig. 3: Endometrial carcinoma.**

**A: Endometrioid carcinoma.**

**B: Endometrioid carcinoma with mucinous differentiation.**

**C: Papillary serous carcinoma.**

**D: Malignant mixed müllerian tumor (H&Ex 10x)**

Simple endometrial hyperplasia was observed in 11 cases (6.7%), 3 cases were endometrial hyperplasia with atypia (1.85%). Hyperplasia is significant that it carries the risk of development of endometrial cancer more so with hyperplasia with atypia. Other studies were 3-13%.<sup>2,11,12,16</sup>

## Conclusion

PMB is a symptom which should not be taken lightly. Accurate diagnosis is usually made by histopathological examination. In our study, a wide spectrum of both neoplastic and non-neoplastic conditions of female genital tract has displayed as a cause of PMB with predominance of benign causes (51.6%). The main aim of evaluation of PMB is to exclude premalignant and malignant lesions. Cervical cancer is still the most common cause of PMB, which point out that the effective implementation of screening program is utmost important. More awareness among people, especially elderly women should be made about the importance of pap screening.

PMB indicates malignancy until proved otherwise and it demands thorough evaluation of patients with histopathological confirmation. An accurate diagnosis is immensely important as it will be helpful for the management of patient by implementing a proper treatment plan.

## References

1. Dawood NS, Peter K, Ibrar F, Dawood A. PMB causes and risk of genital tract malignancy. *J Ayub Medical coll. Abbottabad* 2010;22:117-20.
2. Cheema SZ, Saeed R, Ikram M, Saeed M. Postmenopausal bleeding. *Professional Med J* 2008;15:328-34.

3. Miyazawa K. Clinical significance of an enlarged uterus in patients with postmenopausal bleeding. *Obstet Gynecol* 1983;61:148-52.
4. Carlos RC, Bree RL, Abrahamse PH, Fendrick AM. Cost effectiveness of saline assisted hysterosonography and office hysteroscopy in the evaluation of PMB. *Acad Radiol* 2001;8:835-44.
5. Escoffery CT, Blake GO, Sargeant LA. Histopathological findings in women with postmenopausal bleeding in Jamaica. *West Ind Med J* 2002;51:232-5.
6. Sarfraz T, Tariq H. Endometrial biopsy findings in postmenopausal bleeding. *Pak J Pathol* 2007;18:4-6.
7. Giusa-Chiferi MG, Goncalves WJ, Baracat EC, Cavalcanti de Albuquerque Neto L, Bortoletto CCR, Rodrigues de Lima G. Transvaginal ultrasound, uterine biopsy and hysteroscopy for postmenopausal bleeding. *Int J Gynecol Obstet* 1996;55:39-44.
8. Ghazi A, Jabbar S, Siddiqui N. Frequency of endometrial carcinoma in patients with postmenopausal bleeding. *Pak J surg* 2005;21:41-4.
9. Garuti G, Sambruni I, Cellani F, Garzia D, Alleva P, Luerti M. Hysteroscopy and transvaginal ultrasonography in postmenopausal women with uterine bleeding. *Int J Gynecol Obstet* 1999;65:25-33.
10. Dwines E, Al-Azzawi F. The predictive value of outpatient hysteroscopy in a menopause clinic. *Br J ObstetGynecol* 1993;100:1148-9.
11. Naik VS, Rege JD, Jashnani KD. Pathology of genital tract in postmenopausal bleeding. *Bombay Hospital Journal* 2005;47:14-7.
12. Lee WH, Tan KH, Lee YW. The aetiology of postmenopausal bleeding- a study of 163 consecutive cases in Singapore. *Singapore Med J* 1995;36:164-8.
13. Lidor A, Ismajovich B, Confino E, David MP. Histopathological findings in 226 women with postmenopausal uterine bleeding. *Acta Obstet Gynecol Scand* 1986;65:41-3.
14. Asaf KH, Samina, Hamid. Causes of Postmenopausal Bleeding. *Pak J Obstet Gynaecol* 1997;10:22-6.
15. Asim SS, Akhtar AZ. Frequency of malignancy in women presenting with postmenopausal bleeding. *Ann Abbasi Shaheed Hospital Karachi Med Dent Coll* 2004;9:506-9.
16. Gredmark T, Kvint S, Havel G, Mattsson LA. Histopathological findings in women with postmenopausal bleeding. *Br J Obstet Gynaecol* 1995;102:133-6.
17. Merrill JA. Management of postmenopausal bleeding. *Clin Obstet Gynecol* 1981;24:285-99.
18. Smith- Bindman R, Kerlikowske K, Feldstein VA et al. Endovaginal ultrasound to exclude endometrial cancer & other abnormalities. *The Journal of American Medical Association*. 1998;280:1510-17.
19. PMB (Internet). Patent.co.UK. Accessed June 16 2014. Available from www.patent.co.uk
20. Wolman I, Amster R, Hartoov J et al. Reproducibility of transvaginal ultrasonographic measurements of endometrial thickness in patients with postmenopausal bleeding. *Gynecol Obstet Invest* 1998;46:191-94.
21. Biriniyi L, Darago P, Torok P et al. Predictive value of hysteroscopic examination in intrauterine abnormalities. *Eur J. Obstet Gynecol. Reprod Biol* 2004;115(1):75-79.
22. Tabor A, Watt HC, Wald NJ. Endometrial thickness as a test for endometrial cancer in women with postmenopausal bleeding. *Obstet Gynecol* 2002;99(4):663-70.
23. Litta P, Merlin F, Saccordic C et al. Role of hysteroscopy with endometrial biopsy to rule out endometrial cancer in

- postmenopausal women with abnormal uterine bleeding. *Marturitas* 2005;50(2):117-23.
24. Wong SF, Luk KL, Wong AY, Tang LC. Finding in women with postmenopausal bleeding investigated with hysteroscopy. *J Obstet Gynecol* 2001;21:392-95.
  25. Sousa R, Silvestre M, Almedia e Sousak, Falco F, Dias I, Silva T, De Oliveria C, Oliveria HM. Transvaginal ultrasonography and hysteroscopy in postmenopausal bleeding a prospective study. *Acta Obstet Gynecol Scand* 2001;80:856-62.
  26. Bharani B, Phatak SR. Feasibility and yield of endometrial biopsy using suction curette device for evaluation of abnormal pre and postmenopausal bleeding. *J Obstet Gynecol India*. 2008;58:322-6.
  27. Sheikh M, Sawhney, Khurana A, Al Yatama M. Alteration of sonographic texture of the endometrium in PMB a guide to further management. *Acta Obstet Gynecol Scand*. 2009;79:1006-50.
  28. Yousuf S, Shaheen M and Rana T. Frequency of endometrial carcinoma in patients with postmenopausal bleeding. *Annals* 2010;16:290-94.
  29. Dina GEE, Halah MN. Unexplained postmenopausal uterine bleeding from atrophic endometrium: Histopathological and hormonal studies. *Middle East Fertility Society Journal* 2015;20:262-70.
  30. Choo YC, Mak KC, Hsu C, Wong TS, Ma HK. Postmenopausal uterine bleeding of nonorganic cause. *Obstet Gynecol* 1985;66:225-28.
  31. Tyagi R, Issacs R, Dhar T. Postmenopausal bleeding – Histopathological spectrum and association with age & clear span; case series of 328 cases. *Journal of Evolution of Medical and Dental Sciences*. 2014;3(26):7210-7221.