

The spectrum of various palpable pathological lesions in head and neck region in a tertiary care hospital – FNAC study

Vedashree MK^{1,*}, Girish M², Maruthi CV³

¹Assistant Professor, ²Associate Professor, Dept. of Pathology, ³Associate Professor, Dept. of Orthopaedics, Chamarajanagar Institute of Medical Sciences, Chamarajanagar

***Corresponding Author:**

Email: pathomkvedashree@gmail.com

Abstract

Fine needle aspiration cytology (FNAC) is an important tool for the diagnosis of various palpable lesions of head and neck. It is an inexpensive, reliable and patient acceptable technique for the diagnosis of lesions.

Aim: 1. To study the age and sex incidence and the pathological spectrum of palpable lesions of head and neck in tertiary care hospital.

Objectives: 1. To collect the details regarding age and sex of the patients & site of palpable swellings in the head and neck region. 2. To perform fine needle aspirations in such cases and do cytological study. 3. To analyse the frequency of these lesions based on the site and cytological diagnosis.

Materials & Methods: This prospective study included 72 cases who presented with palpable head and neck swelling to the department of Pathology, district hospital Chamarajanagar from July 2015 to June 2016. The detailed history and examination of swelling were done. FNAC was performed on all cases and the smears were stained with rapid Hematoxylin and Eosin stain and examined. The smears from the lymph node of cases clinically suspicious of tuberculosis were stained with Ziehl Neelsen technique and Auramine O staining.

Results: In our study, females were predominant (63.88%) and males constituted 36.11%. Most of the cases were in thyroid (48.6%), followed by lymph node (40.2%) and equal incidence of lesions in the salivary gland and skin (5.5%). Maximum age was 60 years and the minimum age was 5 years. In thyroid, lymphocytic thyroiditis was the predominant lesion (57.14%) followed by colloid goitre (42.85%). In lymph node FNACs, reactive lymphadenitis was most common (34.48%). Out of 10 smears from lymph node clinically suspicious of tuberculosis, two were positive for Ziehl Neelsen stain and Auramine O stain. Three cases showed metastatic deposits. Out of four salivary gland lesions, three had chronic sialadenitis (75%) and one had Pleomorphic adenoma (25%). All the cutaneous lesions were epidermal cyst cytologically. The age incidence of head and neck swelling was similar to the study conducted in north India but in contrast females were more common in our study than males due to the higher number of thyroid swellings. Cytologically, lymphocytic thyroiditis was higher in our study compared to the studies conducted in the north and western parts of India probably due to the higher prevalence of autoimmunity in this region. The incidence of tuberculous lymphadenitis was less compared to these studies which may be due to less number of lymph node swellings in our study.

Conclusion: FNAC is a reliable and inexpensive outpatient procedure for the rapid diagnosis of various palpable lesions in the head and neck region. Thus it is the first investigation of choice in the diagnosis of these swellings.

Keywords: FNAC, Head and neck lesions, Lymphocytic thyroiditis, Metastatic deposits, Tuberculous lymphadenitis

Introduction

Fine needle aspiration cytology (FNAC) is an important tool for the diagnosis of various palpable lesions of head and neck. It is an inexpensive, reliable and patient acceptable technique for the diagnosis of lesions.⁽¹⁾ It is an outpatient department procedure which causes minimal inconvenience to the patients with no risks and complications. It helps in guiding the clinicians for the treatment of the patients. It plays an important role in the early diagnosis of the lesions.^(2,3) The common palpable lesions in the head and neck region include thyroid swellings, lymph node swellings, salivary gland swelling and cutaneous swellings. FNAC helps in diagnosing inflammatory, infective, benign and malignant neoplasms as well.^(4,5) Neoplasms of neck region account for 23% of all cancers in males in India and 6% in females.⁽⁶⁾ FNAC also helps in the distinguishing benign from malignant lesions except in differentiating follicular adenoma from follicular

carcinoma of thyroid.^(7,8) The smears prepared from the aspirations are stained using H&E staining methods along with special stains like Ziehl Neelsen staining and Auramine O staining. The common lesions in the thyroid swelling include colloid goitre and Hashimoto's thyroiditis. The lesions in the lymph nodes include tuberculosis, reactive lymphadenitis and metastatic deposits. Pleomorphic adenoma and sialadenitis are the common lesions in the salivary gland. The cutaneous lesions include adnexal tumors, cysts and cutaneous malignancies. The study was conducted with the aim to assess the incidence and spectrum of various pathological lesions by FNAC in patients presenting with palpable head and neck swellings and to compare with the other similar studies.

Aim

To study the age and sex incidence and the pathological spectrum of palpable lesions of head and neck in tertiary care hospital.

Objectives

1. To collect the details regarding age and sex of the patients & site of palpable swellings in the head and neck region.
2. To perform fine needle aspirations in such cases and do cytological study.
3. To analyse the frequency of these lesions based on the site and cytological diagnosis.

Material and Methods

This study was conducted in the Department of Pathology, district hospital, Chamarajanagar for a period of one year from July 2015 to June 2016. It was a prospective study with 72 cases presenting with the palpable lesions in the head and neck region. The detailed history was taken for each patient and the descriptions of the swelling were noted. 35 patients presented with thyroid swelling, 29 with swelling in the cervical region, 4 with swelling in the parotid region and 4 had skin swelling. Fine needle aspiration was performed in all the cases in the procedure room by aseptic precautions using 22 gauge needle and 10cc syringe. The smears were fixed using 90% alcohol. All the smears were stained using rapid H&E stain kit and observed under binocular microscope using scanner view(4x), low power(10x), high power(40x) and oil immersion(100x) where required. Ziehl Neelsen stain was done for smears from lymph node of 10 patients who were clinically suspicious of tuberculosis. Auramine O stain was also used for such cases and observed under fluorescent microscope. The age, sex of the patient and site of swelling were tabulated. The microscopic diagnosis was given for all the cases. All the smears were examined and lesions were classified based on the site of swelling and microscopic diagnosis. The data was analysed using descriptive statistical method. The limitation of our study was the non availability of the cyto-histopathological correlation for the cases that underwent FNAC.

Inclusion criteria: All patients with palpable lesions of head and neck region fulfilling the criteria for FNAC.

Exclusion criteria: 1. Vascular swelling which were clinically diagnosed as hemangiomas. 2. Thyroid swelling associated with thyrotoxicosis(based on the T3,T4 & TSH levels). 3. Patients undergoing radiation therapy were not included in the study.

Observation and Results

The patients in the present study were in the mean age group of 35 years. The youngest patient was 5 years old boy presenting with bilateral submandibular swelling which was diagnosed as sialadenitis and the oldest patient was 65 years old female presenting with

swelling thyroid who was diagnosed cytologically as colloid goitre. Maximum number of cases was seen in 21-30 years age group. Out of 72 patients, 46(63.88%) patients were female and 26(36.11%) patients were male. Maximum number 35(48.6%) of the cases presented with thyroid swelling (Table 1). 29 cases (40.2%) presented with lymph node swelling. Out of these, 22 cases (76%) were cervical group and 7 cases (24%) were submandibular group of lymph nodes. 4(5.5%) cases presented with salivary gland swelling. 2(50%) were in submandibular region and 2(50%) in the parotid region. Out of the 4(5.5%) cutaneous swellings in head and neck region, 3(75%) were in forehead and 1(25%) in scalp region. The mean age of presentation of thyroid swellings and cutaneous swellings was 35 years and lymph node swelling was 32 years and salivary gland swelling was 23years.

Table 1: Frequency of head and neck lesions

S. No	Lesions	Cases		Mean age
		Number	%	
1	Thyroid swelling	35	48.6	35.3
2	Lymph node swelling	29	40.2	32.2
3	Salivary gland swelling	4	5.5	23.75
4	Skin swelling	4	5.5	35.75
Total		72		

Among 35 cases of thyroid swellings, 20(57.14%) were diagnosed as lymphocytic thyroiditis, 15(42.85%) were diagnosed as colloid goitre cytologically (Table 2). Out of 29 cases of lymph node swellings, 10(34.48%) had reactive lymphadenitis, 6(20.6%) cases had chronic non-specific lymphadenitis. 10 cases were clinically suspected as tuberculous lymphadenitis and the smears were subjected for Ziehl Neelsen stain and Auramine O stain. Out of them, 5(17.24%) had acute suppurative lymphadenitis, 3(10.34%) had Granulomatous and 2(6.89%) showed tuberculous lymphadenitis which were positive for both Ziehl Neelsen stain and Auramine O stain. Out of 4 cases of salivary gland swellings, 1(25%) case had pleomorphic adenoma and other 3(75%) cases had sialadenitis cytologically. All the four cutaneous lesions were diagnosed as epidermal cysts cytologically.

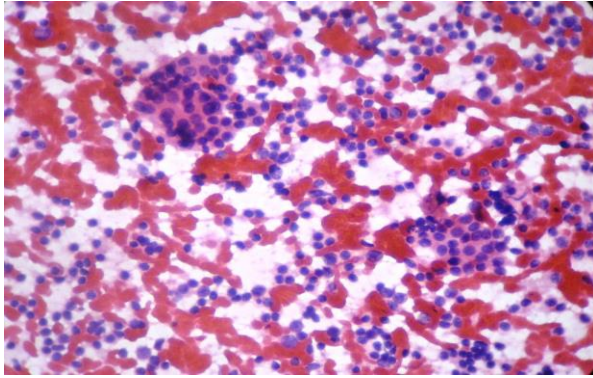


Fig. 1: Hashimoto's thyroiditis, cytological appearance, (40x, high power)

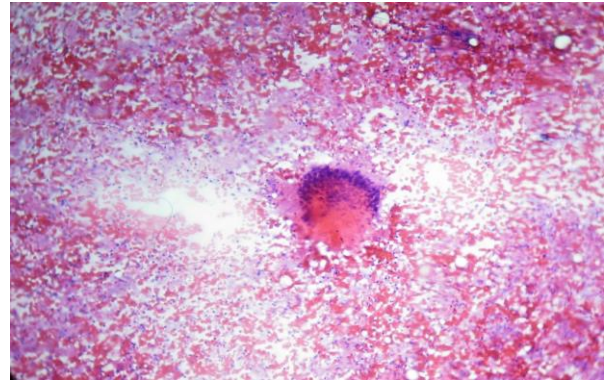


Fig 5: Tuberculous lymphadenitis, cytological appearance, (10x, low power)

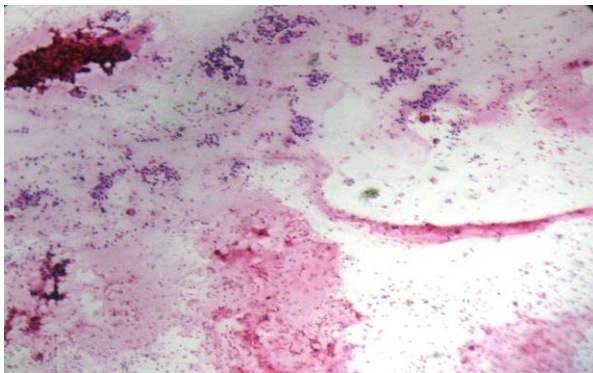


Fig. 2: Colloid goitre, cytological appearance, (40x, high power)

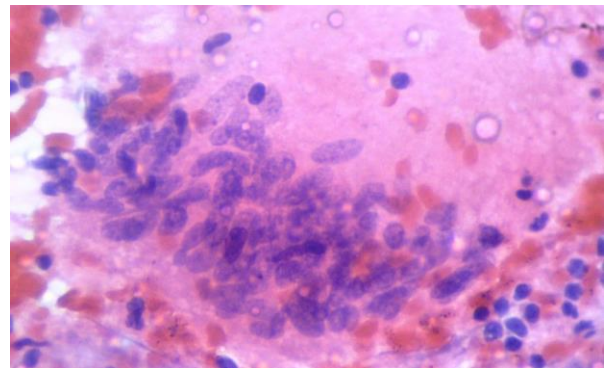


Fig 6: Epitheloid granuloma in Tuberculous lymphadenitis, cytological appearance, (40x, high power)

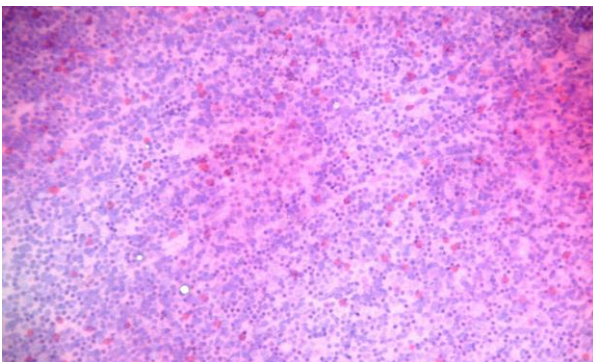


Fig. 3: Reactive lymphadenitis, cytological appearance, (10x, low power)

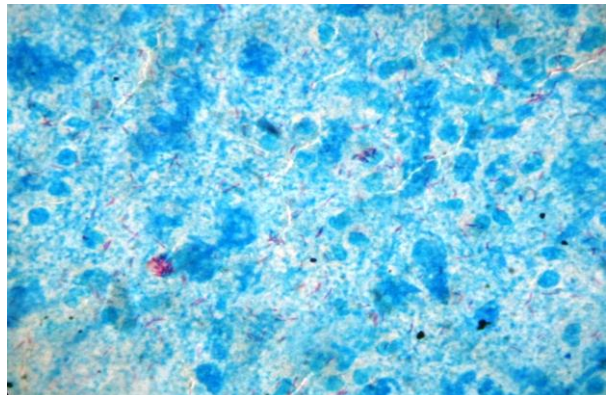


Fig 7: Ziehl Neelsen stain showing acid fast bacilli in Tuberculous lymphadenitis (100x, oil immersion)

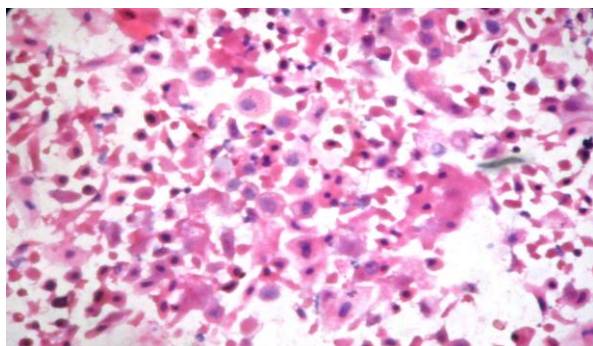


Fig 4: Metastatic carcinomatous deposit – lymph node, cytological appearance, (40x, high power)

All the patients who presented with thyroid swellings were female. Among lymph node swellings, 21 (72.4%) were male and 8(27.5%) were female and among salivary gland swellings, 3(75%) were male and 1(25%) was female patient. Both the sex had equal incidence of cutaneous swellings (50% each).

Table 2: FNAC diagnosis of palpable head and neck swellings with the age and sex incidence

Site	FNAC diagnosis	Number	Percentage	Mean age	Sex	
					Male	Female
Thyroid	Colloid goitre	15	42.85%	38.6	Nil	15
	Lymphocytic thyroiditis	20	57.14%	30.65	Nil	20
Lymph nodes	Reactive lymphadenitis	10	34.48%	22.2	9	1
	Chronic non-specific lymphadenitis	6	20.6%	35.5	3	3
	Acute suppurative lymphadenitis	5	17.24%	28.4	3	2
	Granulomatous lymphadenitis	3	10.34%	41.6	2	1
	Tuberculous lymphadenitis	2	6.89%	32	2	Nil
	Metastatic deposits	3	10.34%	60	2	1
Salivary gland	Pleomorphic adenoma	1	25%	20	Nil	1
	Chronic sialadenitis	3	75%	25	3	Nil
Skin swelling	Epidermal cyst	4	100%	35.75	2	2

Discussion

Lesions of the head and neck constitute a very important chunk of the causes of morbidity and mortality worldwide. The palpable lesions in this region are easily accessible for fine needle aspiration, thus it is the primary investigation of choice. It helps in classifying the lesions as inflammatory, infective, benign and malignant thus helps for the further management of patients. The age distribution, sex distribution, site of lesion and the cytological diagnosis were evaluated and compared with the other studies. The limitation of our study was the non availability of the cyto-histopathological correlation of the cases that underwent FNAC. The data was analysed using descriptive statistical method. The mean age of patients included in our study was 35 years and maximum numbers of cases were in the age group of 21-30 years. This is similar to the observation made by Khetrpal et al,⁽⁹⁾ who found maximum cases between 21-30 years. The maximum patients in our study were female constituting 46(63.88%) and males were 26(36.11%) and female: male ratio was 1.8:1. This is similar to the study conducted by Khetrpal et al⁽⁹⁾ which showed female: male ratio 1.3:1. In contrast our study is not concordant with the study conducted by Lalji G. Valiya et al⁽¹⁰⁾ where female: male ratio is 1:1. All the patients presenting with thyroid swelling were females and this is similar to the studies by Khetrpal et al⁽⁹⁾ and Lalji G Valiya et al⁽¹⁰⁾ which also showed female

preponderance. The majority of patients had thyroid swelling 35(48.6%) followed by lymph node swelling 29(40.2%). The salivary gland swelling and skin swelling constituted 5.5% each. Our study is not concordant with the studies conducted by Khetrpal et al⁽⁹⁾ in New Delhi, Lalji G. Valiya et al⁽¹⁰⁾ in Gujarat and similar studies in Indian subcontinent^(11,7) which showed the majority of lymph node swelling followed by salivary gland swelling. In contrast our study is similar to the studies conducted in tertiary centre in South India where the largest number of cases are from thyroid gland constituting 56.45%.^(12,13) The common cytological diagnosis of thyroid swelling was lymphocytic thyroiditis accounting for 20(57.14%) followed by colloid goitre 15(42.85%). Our study is not concordant with the studies conducted by Khetrpal et al⁽⁹⁾ and Lalji G. Valiya et al⁽¹⁰⁾ which showed colloid goitre in majority followed by lymphocytic thyroiditis. This is probably due to the higher prevalence of autoimmunity in this region. Maximum cases of lymph node swellings had reactive lymphadenitis 10(34.48%) followed by chronic non -specific lymphadenitis 6(20.6%) which is concordant with the studies conducted by Khetrpal et al⁽⁹⁾ and Lalji G. Valiya et al⁽¹⁰⁾ which also showed reactive lymphadenitis as predominant lesion. The incidence of tubercular lymphadenitis in our study was 6.89% which is less compared to studies by Khetrpal (23.2%). This is probably due to the less number of cases presenting

with lymph node swellings in our study. Sialadenitis is the common lesion accounting for 75% followed by pleomorphic adenoma which is similar to the other studies by Lalji et al,⁽¹⁰⁾ Kishor SH et al⁽¹⁴⁾ and Rathod GB et al⁽¹⁵⁾ and not similar to the study by Khetrapal et al.⁽⁹⁾ All the four patients presenting with skin swellings had epidermal cyst which is similar to the study conducted by Lalji et al (36.21%)⁽¹⁰⁾ and Kishor SH et al (57.14%).⁽¹⁴⁾

Results

72 patients presenting with palpable head and neck lesions were subjected for fine needle aspiration cytology and included in the study. The maximum number of patients was in the age group of 21-30 years. The majority 35(48.6%) presented with thyroid swelling followed by lymph node swelling 29 (40.2%) and with equal frequency in salivary gland and skin 4(5.5%). The most common cytological diagnosis was lymphocytic thyroiditis followed by colloid goitre in thyroid swellings, reactive lymphadenitis followed by chronic non-specific lymphadenitis in lymph node swellings. Out of 10 cases from lymph node swellings stained with Ziehl Neelsen stain and auramine O stain, 2(6.89%) cases showed acid fast bacilli. 3(10.34%) cases showed metastatic carcinomatous deposits. Sialadenitis was the common diagnosis followed by pleomorphic adenoma in salivary gland swellings. All the cutaneous swellings showed epidermal cyst cytologically. According to our study, the age incidence of head and neck swelling was similar to the study conducted in north India. Lymphocytic thyroiditis was the common lesion in the head and neck region compared to other studies in north and western parts of India probably due to the higher prevalence of autoimmunity in this region. The incidence of tubercular lymphadenitis was less compared to these studies which may be due to less number of lymph node swellings in our study.

Conclusion

Fine needle aspiration cytology (FNAC) is an important tool for the diagnosis of various palpable lesions of head and neck. It helps in analysing the various pathological spectrum of palpable lesions in this region. It is an inexpensive, reliable and patient acceptable and outpatient department procedure which causes minimal inconvenience to the patients with no risks and complications. It helps in guiding the clinicians for the treatment of the patients. It plays an important role in the early diagnosis of the lesions.

References

1. Fable, WJ. 1989. Needle aspiration biopsy. Past, present and future. *Hum Pathol.* 20:504-517.
2. Ahluwalia H, Gupta SC, Singh M, Gupta SC, Mishra V, Singh PA, Walia DK. Spectrum of head and neck cancers at Allahabad. *J Otolaryngology Head Neck Surg.* 2001;53:16-20.
3. Mehrotra R, Singh M, Gupta RK, Singh M, Kapoor AK. Trends of prevalence and pathological spectrum of head and neck cancers in North India. *Indian J Cancer.* 2005;42:89-93.
4. Rahman MA, Biswas MMA, Sikder AM. Scenario of fine needle aspiration cytology of neck masses in a tertiary care hospital. *J Enam Med Col.* 2011;1(1):8-14.
5. Advani SK, Dahar A, Aqil S. Role of fine needle aspiration cytology (FNAC) in neck masses/cervical lymphadenopathy. *Pak J Chest Med.* 2008;14(3):9-14.
6. Rao YN, Gupta S, Agarwal SP. National Cancer Control Programme: Current Status & Strategies. In Agarwal SP, ed. *Fifty Years of Cancer Control In India.* Dir Gen of Health Services, MOHFW, Government of India, 2002;41-7.
7. Maniyar Amit U, Patel Harshid L, and Parmar BH. Study of Cytodiagnosis of Head and Neck Neoplastic Lesions and Comparison with Histopathology. *Research and Reviews: Journal of Medical and Health Sciences* 2013;2:54-9.
8. El Hag IA, Chiedozi LC, al Reyees FA, Kollur SM. Fine needle aspiration cytology of head and neck masses. Seven years' experience in a secondary care hospital. *Acta Cytol* 2003;47:387-92.
9. Shaan Khetrapal, Sujata Jetley, Zeeba Jairajpuri, Safia Rana, Sunil Kohli. FNAC of head & neck lesions and its utility in clinical diagnosis: a study of 290 cases. *NJMR* 2015;5:33-8
10. Lalji G Valiya, Bhavin B Padhariya, Seema N Bax. Spectrum of FNAC in Palpable Head and Neck Lesions in a Tertiary Care Hospital in Western India- A 2 Years Study. *IOSR-JDMS;* 2016;15(6):14-19.
11. Setal Chauhan, Dharmendra Rathod, D. S. Joshi. FNAC of swellings of head and neck region. *Indian Journal of Applied and Basic Medical Sciences* 2011;13:1-6.
12. Fernandes H, D'Souza C R S, Thejaswini B N. Role of Fine Needle Aspiration Cytology in Palpable Head and Neck Masses. *JCDR* 2009;3:1717-25.
13. Prakash H Muddegowda, Shuba Srinivasan, Jyothi B Lingegowda, Ramkumar Kurpad R, and K Sathiya Murthy. Spectrum of Cytology of Neck Lesions: Comparative Study from Two Centers. *Journal of Clinical & Diagnostic Research.* 2014;8(3):44-45.
14. Kishor SH, Damle RP, Dravid NV, et al. Spectrum of FNAC in palpable head and neck lesions in a tertiary care hospital in India-a 3 years study. *Indian J of pathology and oncology* 2015;2(1):7-13.
15. Rathod GB, Parmar P. Fine needle aspiration cytology of swellings of head and neck region. *Indian Journal of Medical Science* 2012;66(3):49-54.