



Case Report

Gaucher disease: A case presentation

Krupali Patel^{1*}, Pragati Shah¹, Raj Shah¹, Suchita Mishra¹

¹Dept. of Pathology, Smt. NHL Municipal Medical College, Ahmedabad, Gujarat, India



ARTICLE INFO

Article history:

Received 13-02-2024

Accepted 22-05-2024

Available online 09-07-2024

Keywords:

Gaucher disease(GD)

Genetic disorder

Glucocerebrosidase activity

Lysosomal storage disorder

Hepatosplenomegaly

ABSTRACT

Gaucher disease (GD) is an autosomal recessive genetic disorder. It is a rare disorder due to mutation in the acid- β -glucosidase (GBA1) gene. This mutation leads to deficiency of the enzyme glucocerebrosidase. The gene responsible for the disease is located on chromosome 1 band q21. The disorder is characterized by accumulation of gaucher cells in bone marrow, spleen and liver. Gaucher cells are macrophages with deposition of glucosylceramide. Gaucher disease is the most common lysosomal storage disorder. It affects all ethnicities. The clinical presentation of GD is highly variable which depends on geographic and ethnic origin. There are three clinical subtypes have been identified- Type 1 (Adult subtype- Non neuropathic), Type-2 (Infantile subtype-Acute neuropathic), Type -3 (Juvenile subtype- Chronic neuropathic) . Diagnosis is confirmed on the basis of identification of deficiency of glucocerebrosidase activity and also by Bone marrow biopsy examination which demonstrates Gaucher cells. The mainstay of treatment in gaucher disease is enzyme replacement therapy. In this study we reported a case of GD in a 39-year-old male with hepatosplenomegaly and pancytopenia. The diagnosis was challenging in this case since we needed to work out all the differential diagnosis of pancytopenia and hepatosplenomegaly. The patient was initially diagnosed as suffering from decompensated liver disease by radiological investigations and other biochemical investigations. Later on Bone marrow biopsy examination done which shows large number of gaucher cells. Special stain PAS and prussian blue were done on bone marrow biopsy and result came positive. Assesment of enzyme B-glucocerebrosidase level was done which was below the reference range so the diagnosis of GD confirmed.

This is an Open Access (OA) journal, and articles are distributed under the terms of the [Creative Commons Attribution-NonCommercial-ShareAlike 4.0 License](https://creativecommons.org/licenses/by-nc-sa/4.0/), which allows others to remix, tweak, and build upon the work non-commercially, as long as appropriate credit is given and the new creations are licensed under the identical terms.

For reprints contact: reprint@ipinnovative.com

1. Introduction

Gaucher disease (GD) is a metabolic disorder of lysosomal deposit of genetic origin, with an autosomal recessive inheritance pattern, produced by a deficiency of the acid glucocerebrosidase (GBA) enzyme.^{1,2} The consequence of the enzymatic defect is a lysosomal storage disease, given by the accumulation of cerebroside that occurs in the phagocytic cells of the whole organism, mainly in the cells of the reticulo-endothelial system and in some variants of the disease in the central nervous system.^{1,3} The

approximate incidence of GD in the general population is 1/100,000 inhabitants and among Jews of Ashkenazi origin, the population with the highest incidence, is 1/500–1/1000 habitants, with 1 in 10 carriers.^{1,4,5} The purpose of this case report is to highlight the diagnostic difficulties and effort for its early diagnosis and treatment to reduce severe morbidity and mortality in such disease.

2. Case Report

A 39-year-old male patient was admitted to the medicine department with chief complaint of abdominal distention gradually increasing since 6 months, fever on and off since past 6 months and sleep disturbance in form of inability

* Corresponding author.

E-mail address: rshah9402@gmail.com (K. Patel).

to sleep since 1 month. No history of hematemesis, blood in stool, hematuria. On physical examination, liver was palpable, firm, non-tender and spleen was tense. There were no signs and symptoms of neurological impairment. Rest of the systemic examination was normal. Ultrasound sonography Abdomen show massive hepatomegaly with altered echotexture and irregular margin suggesting Liver parenchymal disease and mild ascites was noted. Portal vein was dilated with multiple collaterals at peripancreatic region, at porta and splenic hilum. Spleen is massively enlarged and shows multiple lesions largest measuring approx. 15 x19 cm suggestive of developing splenic abscess. Ultrasound sonography for liver fibroscan shows fibrosis. Laboratory investigation revealed pancytopenia (hemoglobin=6.8 g/dL, white blood cells=2.12×10⁹/L, and platelets=16 ×10⁹/L). His biochemical investigations reveal slightly raised Serum glutamic oxaloacetic transaminase (SGOT), alkaline phosphatase and total bilirubin and mild decrease in serum albumin level and normal serum globulin level. Renal function tests were normal. Serum iron and Total iron binding capacity (TIBC) were normal but serum ferritin was markedly elevated >1620 (normal 10 – 282ug/L). Serum α -fetoprotein (AFP) and Lactate dehydrogenase (LDH) level were normal. Erythrocyte sedimentation rate (ESR) was 45 mm/hr. Serum vit B 12 level was >2000 (normal 211 -911 pg/ml). C- reactive protein was high 73.09 mg/l (<5 mg/L). Prothrombin time (PT) was 32.0s (12-16s) [international normalized ratio [INR] =2.50] and Activated partial thromboplastin time(APTT) was 48.4s (20-35s). Peripheral blood smear findings reveal predominantly macrocytic normochromic rbc with anisopoikilocytosis (++). Wbcs and platelets were reduced on smear. The patient was suspected for liver disease (but not Gaucher disease) and for pancytopenia bone marrow aspiration/ biopsy was planned. Bone marrow aspiration revealed many macrophages having one or two eccentric nuclei with abundant pale fibrillary content in cytoplasm which resemble crumbled tissue paper so they were labelled as Gaucher cells. Subsequently Bone marrow biopsy examination was showing large populations of these Gaucher cells replacing normal hematopoietic tissue. Cells were Periodic acid Schiff (PAS) and pearl's stain positive. Level of B-glucocerebrosidase was below the reference range : 0.40 (5.0- 22.0) confirmed our diagnosis.

3. Discussion

GD is characterized by its clinical polymorphism. It affects multiple organ systems and does not always correlate exactly with the specific genotype diagnosed.² In most patients, GD is diagnosed by pathologists, usually by means of a bone marrow trephine biopsy.^{1,6} Gaucher cells are usually large and can measure up to 100 microns in diameter; they may have one or more dark eccentric nuclei and rarely have vacuoles in

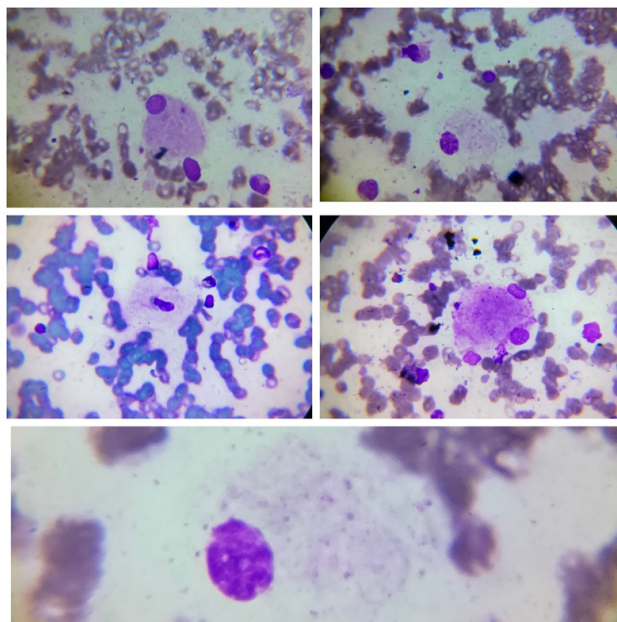


Figure 1: Representative images show Gaucher cells with crumpled tissue paper appearance in bone marrow aspirate smear

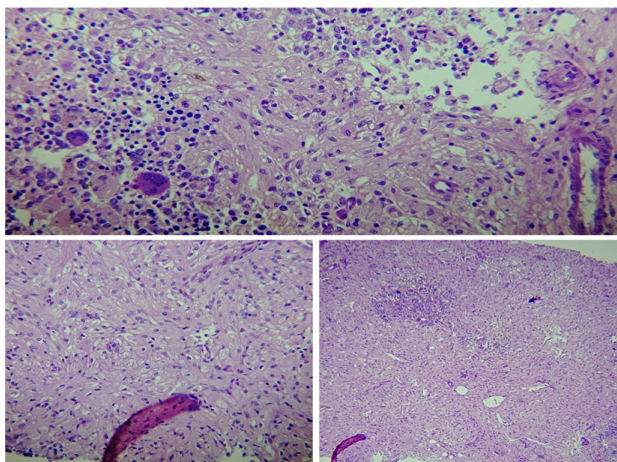


Figure 2: Representative images are of Bone marrow biopsy which show severe infiltration by Gaucher cells, surrounded by residual hematopoietic tissue

their cytoplasm.⁴ The differential diagnosis of “foamy” macrophages in bone marrow should be performed with lysosomal storage disorders such as: Gaucher disease, Fabry disease, Gangliosidosis GM1, Wolman/cholesterol ester, Niemann Pick A and B (dark blue histiocytes) and hematologic disorders with pseudo-Gaucher cells such as: multiple myeloma, Hodgkin’s lymphoma, non-Hodgkin’s lymphoma, chronic myeloid leukemia, myelodysplasia, B-cell acute lymphoblastic leukemia, thalassemia, and sickle cell disease.^{6,7} When GD is suspected, it can be achieved by measuring the beta-glucocerebrosidase activity

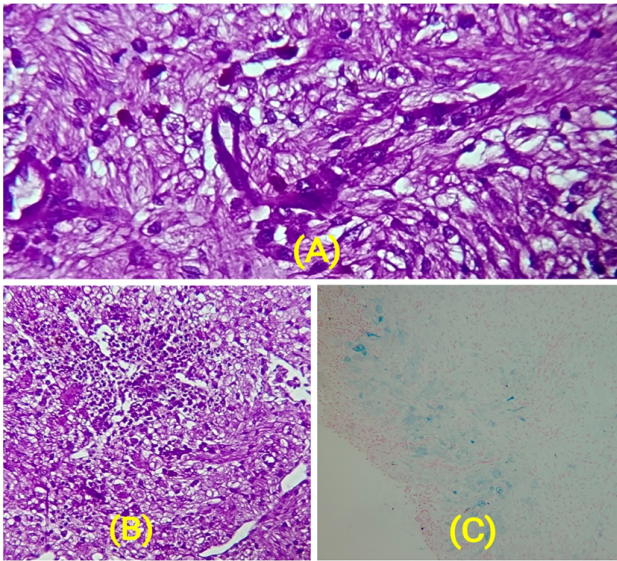


Figure 3: A, B): Gaucher cells demonstrate strong positivity with Periodic Acid-Schiff (PAS) Stain; C): Gaucher cells with Perls stain show pale blue cytoplasm

in the blood leukocytes, which can help avoid invasive procedures.¹ One of the challenges that clinicians face is to differentially diagnose GD from other diseases that have similar presentations for instance, cirrhosis of liver, splenic congestion, infection, and hematologic disorders. Despite the fact that liver parenchymal disorder could explain organomegaly which includes viral, alcohol, metabolic disorders, autoimmune disorders were ruled out. Presence of pancytopenia and unusual hepatomegaly recommended bone marrow examination which shows infiltration in large amount by Gaucher cells replacing normal hematopoietic tissue and positivity for PAS and Perls stain. Low levels of B -glucocerebrosidase activity confirmed our diagnosis.

Enzyme-directed macrophage replacement therapy (TRE) has long been the standard treatment. It is not a cure for GD, because it does not repair the underlying genetic defect but it can reverse and prevent numerous manifestations of type 1 GD.⁸

The present case is of relevant interest to the scientific community due to its low incidence, which makes it a rarely-suspected diagnostic possibility, leading, not infrequently, to a diagnostic delay, which makes it important for medical personnel in charge of its diagnosis and monitoring.

4. Conclusion

Diagnosis of GD should be suspected in differential diagnosis in case of patients presenting with massive hepatosplenomegaly in the background of liver

parenchymal disease and portal hypertension, particularly if organomegaly is not correlating with the stage of liver parenchymal disease. The present case illustrate the significance of clinical and bone marrow examination in the diagnosis of GD. Since the disease is rare, patients frequently experienced diagnostic delays during which severe irreversible complications can occur. Therefore, an early diagnosis and treatment is necessary to reduce severe complications and mortality.

5. Source of Funding

None.

6. Conflict of Interest

None.

References

1. Cassinero E, Graziadei G, Poggiali E. Gaucher disease: a diagnostic challenge for internists. *Eur J Intern Med.* 2014;25(2):117–24.
2. Cristo-Pérez V, Arias-Galán L, Quesada-Laferté Y, Yllodo-Hernández O, Valle-Castro MCD, Pérez-Porrás B. Enfermedad de Gaucher tipo I y enfermedad de Parkinson. Presentación de un caso. *Rev Cubana Hematol Inmunol Hemoter.* 2018;33(S1).
3. Herráez-Albendea MM, Fernández-Cofrades EG, Jarilla-Fernández MC, Jiménez-Burgos F. Enfermedad de Gaucher: a propósito de un caso. *Reumatol Clin.* 2017;13:242–3.
4. Acanda RAM. Aspectos bioquímicos, genéticos y comorbilidades de la enfermedad de Gaucher, diagnóstico molecular en Cuba. *Rev Cubana Genet Comunit.* 2012;6(1):8–19.
5. Relichman GD, Linares A, Villalobos J, Cabello JF, Kerstenetzky M, Kohnan R, et al. Enfermedad de Gaucher en Latinoamérica. Uninforme del registro internacional y del grupolatinoamericanopara la enfermedad de Gaucher. *Medicina.* 2012;72:273–82.
6. Hughes D. Rare but important haematological conditions: Gaucher disease. *Medicine.* 2017;45(4):256–9.
7. Ferreira CR, Gahlc WA. Lysosomal storage diseases. *Transl Sci Rare Dis.* 2017;2(1-2):1–71.
8. Grabowski GA, Zimran A, Ida H. Gaucher disease types 1 and 3: Phenotypic characterization of large populations from the ICGG gaucher registry. *Am J Hematol.* 2015;90(Suppl 1):12–8.

Author biography

Krupali Patel, Assistant Professor <https://orcid.org/0009-0003-0994-557X>

Pragati Shah, Resident <https://orcid.org/0009-0004-1039-4338>

Raj Shah, Resident <https://orcid.org/0009-0008-1944-4919>

Suchita Mishra, Assistant Professor <https://orcid.org/0000-0003-0636-5775>

Cite this article: Patel K, Shah P, Shah R, Mishra S. Gaucher disease: A case presentation. *Indian J Pathol Oncol* 2024;11(2):213-215.