

Content available at: <https://www.ipinnovative.com/open-access-journals>

Indian Journal of Pathology and Oncology

Journal homepage: www.ijpo.co.in

Case Report

Pleomorphic adenoma of external auditory canal: A common tumor at an uncommon site

Kavita Somani^{1*}, Pretty Singh¹, Sujatha Poduval¹

¹Dept. of Pathology, Apollomedics Superspeciality Hospital, Lucknow, Uttar Pradesh, India



ARTICLE INFO

Article history:

Received 08-04-2024

Accepted 12-04-2024

Available online 17-04-2024

Keywords:

Pleomorphic adenoma

External auditory canal

Ear

Salivary gland

Immunohistochemistry

ABSTRACT

Pleomorphic adenoma (PA) of external auditory canal is an extremely rare benign neoplasm of uncertain origin with only few reported cases in the literature. It's always challenging to diagnose pleomorphic adenoma of external auditory canal due to its rarity, unusual location as well as nonspecific symptoms mimicking more prevalent benign and malignant lesion of this site. Due to its premalignant nature and chances of recurrence, this case highlights the importance of Pleomorphic Adenoma as differential diagnosis in patient presenting with external auditory canal masses and necessity of complete surgical excision. This case report of 52 years male describes the clinical presentation, histopathological features and immunohistochemical findings of pleomorphic Adenoma of external auditory canal with review of literature emphasizing the diagnostic and therapeutic challenges associated with neoplasm.

This is an Open Access (OA) journal, and articles are distributed under the terms of the [Creative Commons Attribution-NonCommercial-ShareAlike 4.0 License](https://creativecommons.org/licenses/by-nc-sa/4.0/), which allows others to remix, tweak, and build upon the work non-commercially, as long as appropriate credit is given and the new creations are licensed under the identical terms.

For reprints contact: reprint@ipinnovative.com

1. Introduction

Pleomorphic adenomas are most common benign tumours of salivary glands, primarily occurring in parotid gland and comprise of approximately 80% of all of the benign salivary gland neoplasms. Occasionally, cases of pleomorphic adenoma originating from the minor salivary glands of the lips, buccal mucosa or palate have also been reported.¹ Rarely, these tumors can arise from unusual sites like the tongue, trachea, turbinate and lacrimal glands, however, external auditory canal is one of the rarest site for pleomorphic adenoma.² These are usually slow growing tumors with an indolent course and complete surgical removal of the tumor with adequate margins results in good clinical outcome. However due to rare chances of recurrence, it is recommended to keep patient under follow up.³

PA is a biphasic tumor comprising of polygonal epithelial cells admixed with spindle shaped myoepithelial cells on a

variable background, composed of chondromyxoid, mucoid or hyalinised stroma. Due to presence of both epithelial and mesenchymal components, these tumors are also called as benign mixed tumour and term pleomorphic is used due to presence of various morphological variants of both epithelial and mesenchymal components.⁴ Pleomorphic adenoma of external auditory canal is a slow growing benign tumor and have tendency to grow into large mass and become malignant. Based on the literature, there is a 6% probability of malignant transformation, with the duration of the disease being the primary factor influencing this outcome.⁵ Pleomorphic adenoma is extremely uncommon entity and belongs to a group of benign and malignant tumors of external auditory canal. Approximately 5% of all neoplasms found in the external ear are constituted by benign adenoma.⁶ The external auditory canal contains both sebaceous glands and apocrine sweat glands. Majority of the benign tumours of external auditory canal originates from the ceruminous glands, which are considered to be modified sweat glands of the skin of the external auditory canal.⁷ First

* Corresponding author.

E-mail address: kavita_somani@apollohospitals.com (K. Somani).

case of pleomorphic adenoma of external auditory canal was reported in 1951 by Marks and Rothberg, since then only 150 cases of glandular tumours of the external auditory canal are reported in the literature so far.⁸

Due to uncommon occurrence of this neoplasm, at this unusual location, there is scarcity of extensive literature leading to inconsistent etiology, nomenclature and categorization.

2. Case Presentation

A 52 years of male presented with history of ear discharge, gradually progressive hearing loss and fullness in right ear from last one year, in outpatient department of Otorhinolaryngology in our tertiary care hospital. Physical examination showed a non-friable, non-tender, mass covered with skin. On probing mass was attached to posterior canal wall. Tympanic membrane was not visible. Facial nerve function was normal and both parotid gland and cervical lymph nodes were not palpable. On pure tone audiometry there was moderate conductive hearing loss in right ear. Computed tomography (CT) scan of right temporal bone showed a soft tissue mass measuring around 2.0 cm, in the external auditory canal with no underlying bony erosion. Middle and internal ear were normal with no obvious abnormality. Complete resection of the mass with preservation of the adjacent facial nerve was achieved by local excision of mass via postaural transcranial approach along with mastoidectomy and tympanoplasty, under general anaesthesia. Intraoperative findings showed a firm, skin covered mass of around 2.0 cm, attached to cartilaginous and bony canal wall junction of external auditory canal, reaching upto tympanic membrane. No bony erosion or osteitis were noted. On removal of mass was non-friable, non-vascular, tympanic membrane showed a medium sized central perforation. Rest of the middle ear and mastoid air cells were normal. Postoperative recovery was uneventful and patient reported resolution of symptoms and improvement of hearing.

Tissue was sent for histopathological evaluation, postoperatively. On gross examination the tumor was a globular grey-white soft tissue mass, measuring 2.5x1.5x1.0 cm. Cut section revealed firm grey white areas. On Microscopic examination Haematoxylin and eosin stained sections showed a circumscribed, non-capsulated neoplasm, lined by stratified squamous epithelium on the outside. The underlying areas showed nest, tubules and cords of epithelial cells with outer layer of myoepithelial cells, present in a chondromyxoid stroma. Few cystically dilated tubules, filled with mucoid material were also present (Figures 1 and 2).

Few areas of fibro-collagenous stroma along with foci of squamous metaplasia and calcification were also noted. There was no nuclear pleomorphism, increased mitotic activity or perineural invasion. Further,

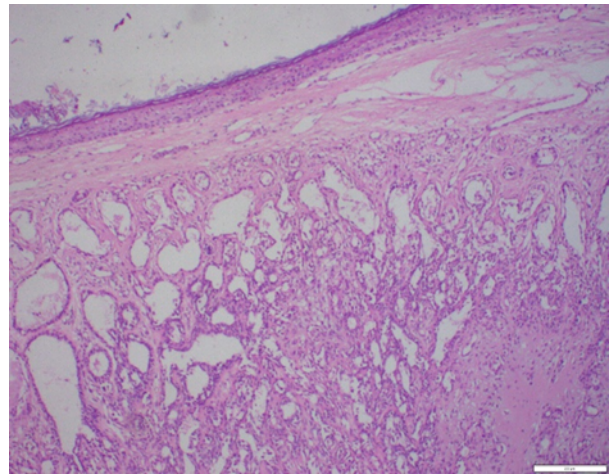


Figure 1: Haematoxylin and Eosin (100x): Lower power view of tumor with overlying stratified squamous epithelium

Immunohistochemical staining demonstrated epithelial cells highlighted by CK7 whereas the outer layers of myoepithelial cells were highlighted by S100, SMA and p63 (Figures 2, 3 and 4). On the basis of all these findings the diagnosis of pleomorphic adenoma of external auditory canal was given.

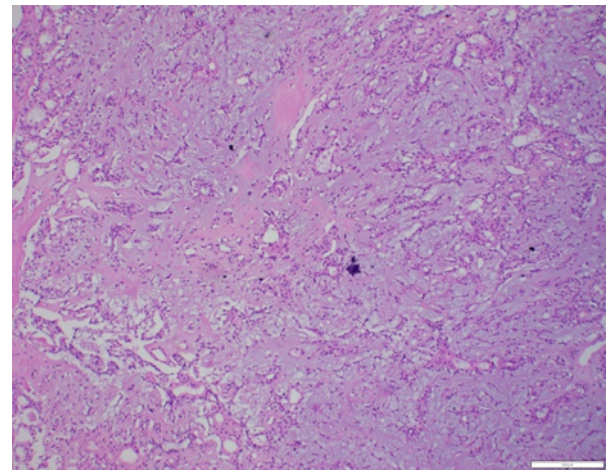


Figure 2: Haematoxylin and Eosin stain (200x): Cords and tubules of tumor cells in chondromyxoid stroma

3. Discussion

Pleomorphic adenoma of external auditory canal poses several diagnostic and therapeutic challenges due to its rarity at this anatomical location. The etiology of pleomorphic adenoma in external auditory canal remains poorly understood, it is hypothesized to originate from the ectopic salivary tissue or from the direct extension of the tumour from the parotid gland. However according to current literature pleomorphic adenoma of external

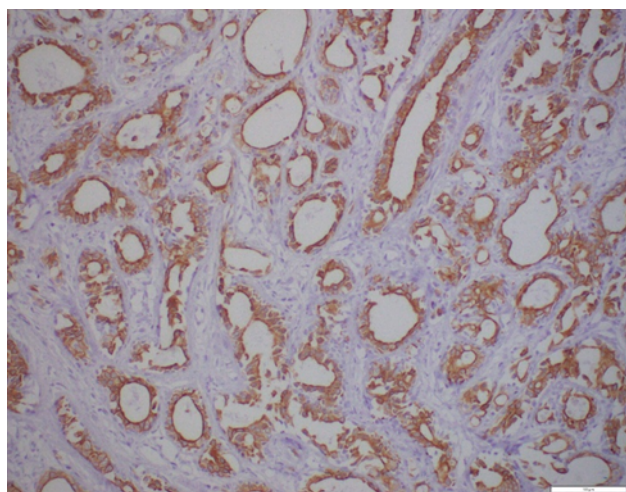


Figure 3: Immunohistochemistry: CK7 (200x): Cytoplasmic positivity in epithelial tumor cells

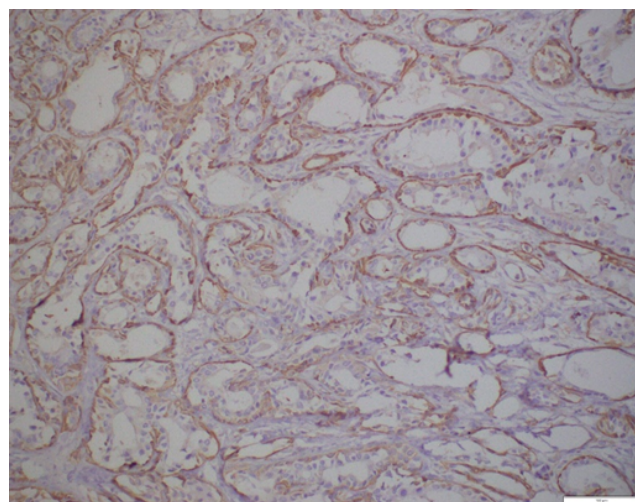


Figure 5: Immunohistochemistry: SMA (200x): Cytoplasmic positivity in atypical myoepithelial cells

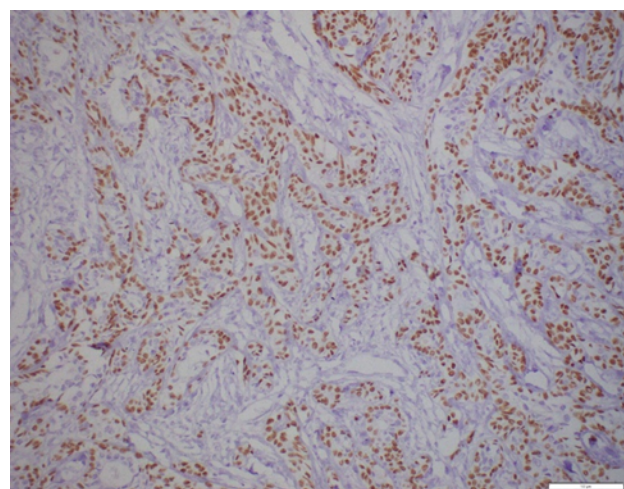


Figure 4: Immunohistochemistry: p63 (200x): Nuclear positivity in atypical myoepithelial cells

auditory canal are termed as ceruminous gland neoplasm which are in turn considered to be modified sweat glands of the external auditory meatus skin.⁹ Collins and Yu documented the immunohistochemical and electron microscopic characteristics of these tumors and they proposed that these tumors originate from the benign ceruminous glands.¹⁰ Use of staining for cerumen pigment, and IHC for CK7 and p63 can help in differentiating pleomorphic adenoma from other neoplasms.

In 1894 Haugh was first to report the ceruminous gland tumour in external auditory canal and called it Ceruminoma.¹¹ In 1991 this term was obsoleted by world health organization (WHO) and the according to new WHO classification, ceruminous neoplasm of external auditory canal has classified into benign and malignant.¹² The benign neoplasm comprise of ceruminous pleomorphic

adenoma, chondroid syringoma, ceruminous adenoma, and ceruminous syringocystadenoma while malignant neoplasm constitute ceruminous adenocarcinoma, ceruminous adenoid cystic carcinoma, and ceruminous mucoepidermoid carcinoma.¹³ Wetli et al. categorized these tumors based on their histopathological characteristics. They identified two benign tumors, pleomorphic adenoma and ceruminous adenoma, and two malignant tumors, adenoid cystic carcinoma and adenocarcinoma. This classification effectively distinguishes between the benign and malignant entities.¹⁴ The majority of the tumors found in the external auditory canal are of a malignant nature and can extend into the middle ear, resulting in a notable loss of hearing. Despite being benign in nature it may have symptoms mimicking other benign lesions of external ear, middle ear and mastoid, leading to delayed diagnosis and management. In our case progressive hearing loss with otorrhoea prompted further evaluation, ultimately leading to finding of this tumor.

The mean age for diagnosis of EAC pleomorphic adenoma is fifth decade, with a range of 12-85 years, which is different from malignant ceruminous glands tumors, which appear at an earlier age.¹⁵ There is no gender predilection for this tumor. The clinical symptoms depends upon duration of disease leading to increase in the size of tumour and level of obstruction of the auditory canal, which further causes otalgia, fullness of ear, conductive hearing loss, tinnitus and otorrhoea. Before clinical presentation the duration of patient's symptoms may range from days to years. Some of tumors also present with chronic otitis media and cholesteatoma.¹⁶ The mean size of tumour reported in various case reports range from 0.4-20.0cm with mean size 1.1 cm.¹⁷ In our patient the tumor size was 2.5 cm. which is slightly larger than mean size. The most common location for the pleomorphic adenoma

of external auditory canal is posterior to postero-superior canal wall,¹⁸ in our case tumour was attached to posterior canal wall. Imaging modalities like CT and especially MRI have crucial role in diagnosis of external auditory canal lesion as well as in guiding surgical planning. On Computed tomography scan and MRI, the tumour usually appears as hypointense on T1-weighted image and hyperintense on T2-weighted image. Complete surgical excision with careful preservation of adjacent structures with an emphasis on preserving facial nerve function, remains the cornerstone of treatment, ensuring optimal outcome and minimizing the risk of recurrence. In our case intraoperative findings revealed the tumour adherent to the junction of cartilaginous and bony canal without invading into surrounding structure, facilitating complete excision with preservation of facial nerve function. Despite being benign in nature, incomplete removal of the tumor can lead to recurrence, highlighting the importance of achieving clear surgical margins. Recurrence rates of pleomorphic Adenoma of external auditory canal vary in literature, with some reports suggesting a higher propensity for recurrence at this area compared to pleomorphic adenoma occurring in other salivary gland locations. Factors contributing to recurrence include inadequate surgical margins, incomplete resection and presence of satellite nodules. Long term follow up is essential to monitor for recurrence and to ensure optimal outcome.¹⁹

Although it is rare for these tumors to become malignant, there have been documented cases in the literature of pleomorphic adenoma of the external auditory canal progressing or relapsing into malignant form along with metastasis. Metastasis commonly occurs in regional lymph nodes, bones, and lungs. The histological characteristics of malignant transformation include cellular atypia, infiltrative margins, increased mitosis, tumor necrosis, and satellite nodules.²⁰ Adequate surgery with clear margins, along with regular and long term follow-ups are essential to monitor for recurrence and optimal outcome.

4. Conclusion

Pleomorphic adenoma of ceruminous glands is a rare benign tumor of the external auditory canal. Although being slow growing in nature, correct diagnosis is mandatory for optimum management. Multidisciplinary collaboration between otorhinolaryngologists, radiologists and pathologists is essential for correct diagnosis. Histopathological examination along with Immunohistochemistry staining remains the gold standard for the accurate diagnosis of PA EAC. Continuous research efforts are warranted for better understanding of the pathogenesis, optimal treatment strategies and long term outcomes of this rare tumor entity.

5. Source of Funding

None.

6. Conflict of Interest

None.

References

1. Auclair PL, Ellis GL. Major salivary glands. In: Silverberg SG, Delellis R, Frable WJ, editors. Principles and Practice of Surgical Pathology and Cytopathology. Edinburgh, UK: Churchill Livingstone; 1997. p. 1461–1515.
2. Chadha S, Pannu KK, Gill KS. Pleomorphic adenoma of external auditory canal. *Indian J Otolaryngol Head Neck Surg.* 2011;63:61–3.
3. Rabinov R, Canalis RF, Alavi S, Lee EJ. Recurrent pleomorphic adenoma of the parotid gland involving the osseous external auditory canal: with a note on the foramen of Huschke. *Ann Otol Rhinol Laryngol.* 1997;106(7):589–93.
4. Saade RE, Bell DM, Hanna EY. Benign neoplasms of the salivary gland. In: Flint PW, Haughey BH, editors. Cummings otolaryngology-head & neck surgery. Ontario, Canada: Elsevier Inc; 2015. p. 1245.
5. Jaber S, Rudic M, Keogh IJ. Pleomorphic adenoma of the external auditory canal: a rare presentation. *Case Rep Otolaryngol.* 2015;2015:696531.
6. Homer J, Robson A. Benign salivary gland tumours. In: Watkinson JC, Clarke RW, editors. Scott-Brown's Otorhinolaryngology and Head and Neck Surgery. London, UK: CRC Press; 2019. p. 115–30.
7. Pulec JL. Glandular tumors of the external auditory canal. *Laryngoscope.* 1977;87(10):1601–12.
8. Mark I, Rothberg M. Mixed tumor of skin of external auditory canal. *AMA Arch Otolaryngol.* 1951;53(5):556–9.
9. Markou K, Karasmanis I, Vlachtsis K, Petridis D, Nikolaou A, Vital V. Primary pleomorphic adenoma of the external ear canal. *Am J Otolaryngol.* 2008;29(2):142–6.
10. Collins RJ, Yu HC. Pleomorphic adenoma of the external auditory canal: an immunohistochemical and ultrastructural study. *Cancer.* 1989;64(4):870–5.
11. Haug R. Beiträge zur Klinik und mikroskopischen Anatomie der Neubildungen des äusseren und mittleren Ohres. *Eur Arch Otorhinolaryngol.* 1894;36(3):170–206.
12. El-Naggar AK, Chan JK, Grandis JR, Takata T, Slootweg PJ. Pathology and Genetics of Head and Neck Tumors. In: WHO classification of head and neck tumours. France: IARC; 2017.
13. Fletcher CDM. Pathology and Genetics of Head and Neck Tumors. Barnes L, Eveson JW, Reichart P, Sidransky D, editors. Lyon, France: IARC; 2005. p. 330–3.
14. Wetli CV, Pardo V, Millard M, Gerston K. Tumors of ceruminous glands. *Cancer.* 1972;29(5):1169–78.
15. Maruyama A, Tokumaru T, Kitamura K. Pleomorphic adenoma presenting with conductive hearing loss in the ear canal: a case report and review of the literature. *J Med Case Rep.* 2014;8:178.
16. Nandi SP, Shaw HJ. Hidradenoma of the external auditory meatus associated with facial palsy and chronic otitis media. *J Laryngol Otol.* 1961;75:992–6.
17. Saito C, Kanazawa T, Yamaguchi T. Primary pleomorphic adenoma of the external auditory canal: a case report and review of the literature. *Case Rep Otolaryngol.* 2014;2014:975151. doi:10.1155/2014/975151.
18. Markou K, Karasmanis I, Vlachtsis K, Petridis D, Nikolaou A, Vital V. Primary pleomorphic adenoma of the external ear canal. Report of a case and literature review. *Am J Otolaryngol.* 2008;29(2):142–6.
19. Vasileiadis I, Kapetanakis S, Petousis A, Karakostas E, Simantirakis C. Rapidly growing chondroid syringoma of the external auditory canal: report of a rare case. *Case Rep Med.* 2011;2011:589680. doi:10.1155/2011/589680.
20. Botha JB, Kahn LB. Aggressive chondroid syringoma: report of a case in an unusual location and with local recurrence. *Arch Dermatol.* 1978;114(6):954–5.

Author biography

Kavita Somani, Senior Consultant  <https://orcid.org/0009-0004-3109-9346>

Pretty Singh, Consultant  <https://orcid.org/0000-0003-4698-0836>

Sujatha Poduval, Consultant

Cite this article: Somani K, Singh P, Poduval S. Pleomorphic adenoma of external auditory canal: A common tumor at an uncommon site. *Indian J Pathol Oncol* 2024;11(1):90-94.