

Content available at: <https://www.ipinnovative.com/open-access-journals>

Indian Journal of Pathology and Oncology

Journal homepage: [www.ijpo.co.in](http://www.ijpo.co.in)

## Case Report

# An occult leiomyosarcoma in a hysterectomy specimen presumed to be uterine fibroid preoperatively: A case report

Swati Priya<sup>1\*</sup>, Manoj Kumar Paswan<sup>1</sup>, Saurav Banerjee<sup>1</sup>, Arvind Kumar<sup>1</sup>,  
Sunil Mahto<sup>1</sup>

<sup>1</sup>Dept. of Pathology, Rajendra Institute of Medical Sciences, Ranchi, Jharkhand, India



### ARTICLE INFO

#### Article history:

Received 17-01-2024

Accepted 15-03-2024

Available online 17-04-2024

#### Keywords:

Occult

Leiomyosarcoma

Uterus

Incidental

### ABSTRACT

**Background:** Uterine sarcomas account for approximately 1% of all gynecologic neoplasm and 3–7% of all uterine cancers. Approximately 1 in every 800 women believed to have a leiomyoma actually has a sarcoma. Here we discuss a case of occult leiomyosarcoma in a hysterectomy specimen suspected to be uterine fibroid preoperatively along with spectrum of diagnoses of uterine mesenchymal tumours and the differentiating parameters.

**Method:** This is a descriptive study.

**Case Report and Result:** A 48-year-old female with heavy menstrual bleeding since 4-5 years, on USG showed an enlarged uterus containing a fibroid with degenerative changes. Grossly, fibroid is seen (11cm x 8.6cm) greyish white, fleshy, involving more than half of the myometrium. Microscopically, fibroid mass showed highly pleomorphic, hyperchromatic tumour cells with dispersed chromatin and indistinct cytoplasm, arranged in intersecting fascicles. Large areas of coagulative tumour cell necrosis seen, mitotic figures > 10 per 10 HPF, suggesting leiomyosarcoma of uterus.

**Conclusion:** Leiomyosarcomas are diagnosed when a triad of histopathological features is seen - significant atypia, increased mitotic activity and coagulative tumour cell necrosis. These are important in differentiating between variants of leiomyoma, STUMP and leiomyosarcoma. Sometimes a benign fibroid-like mass can incidentally be diagnosed as leiomyosarcoma microscopically. It's essential to avert morcellation in routine gynecological practice especially in perimenopausal women with a large fibroid to avoid intra-abdominal dissemination. Precise pre-operative radiological workup by MRI or expert-guided sonogram is also suggested but given the complexities involved, role of histopathology to diagnose leiomyosarcoma is invaluable.

This is an Open Access (OA) journal, and articles are distributed under the terms of the [Creative Commons Attribution-NonCommercial-ShareAlike 4.0 License](https://creativecommons.org/licenses/by-nc-sa/4.0/), which allows others to remix, tweak, and build upon the work non-commercially, as long as appropriate credit is given and the new creations are licensed under the identical terms.

For reprints contact: [reprint@ipinnovative.com](mailto:reprint@ipinnovative.com)

## 1. Introduction

Uterine sarcomas make up about 1% of all female malignancies, tumours of gynecological region and overall 3–7% of uterine cancers.<sup>1</sup> Almost 1 per 800 women who is suspected to have a leiomyoma in reality is diagnosed as a sarcoma.<sup>2</sup> Preoperative diagnosis of leiomyosarcoma is complex and in majority situations it is diagnosed

intraoperatively or postoperatively.<sup>3</sup> At times it may look grossly like benign uterine leiomyomas, also termed as a fibroid, with its common presentation being heavy menstrual bleeding, pain around pelvic region and a palpable mass.<sup>4</sup>

## 2. Aims and Objectives

1. To discuss a case of occult leiomyosarcoma in a hysterectomy specimen suspected to be uterine fibroid

\* Corresponding author.

E-mail address: [sparklingswati806@gmail.com](mailto:sparklingswati806@gmail.com) (S. Priya).

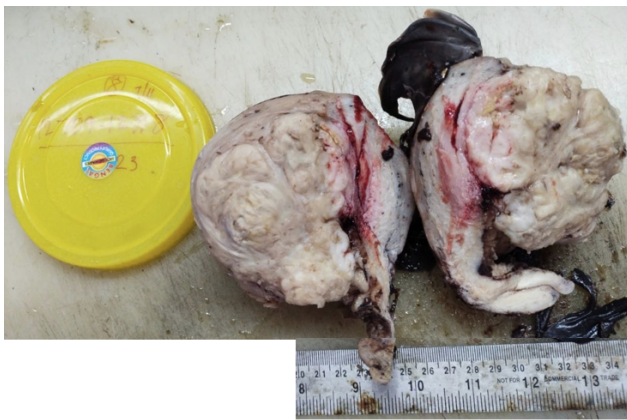preoperatively.

2. To discuss spectrum of diagnoses of uterine mesenchymal tumours and the parameters used to differentiate between them.

### 3. Case Report

A 48-year old multiparous female presented in the gynecology department with heavy menstrual bleeding since 4-5 years and pelvic pain. On abdominal ultrasound an enlarged uterus measuring (13.6 x 7.6) cm containing a single fibroid with degenerative changes measuring (9.7 x 6.2) cm. Total hysterectomy with bilateral salpingo-oophorectomy was done and the specimen was sent to the Pathology department.

Grossly, a solitary fibroid was seen (11cm x 8.6cm) greyish white in colour, homogenous, fleshy, with smooth borders and involving more than half of the myometrium (Figure 1). On initial macroscopic examination due to the benign features only two sections were taken from the suspected fibroid mass which on microscopic evaluation showed features of malignancy. Regrossing of the specimen was done and tissue sample from the mass was taken extensively. Microscopically, fibroid mass showed tumour cells arranged in intersecting fascicles which are highly pleomorphic, hyperchromatic with dispersed chromatin and indistinct cytoplasm.(Figure 2) Large areas of coagulative tumour cell necrosis seen which are abrupt.(Figure 3) The mitotic figures were more than 10 per 10 HPF, suggesting leiomyosarcoma of uterus. (Figure 4)

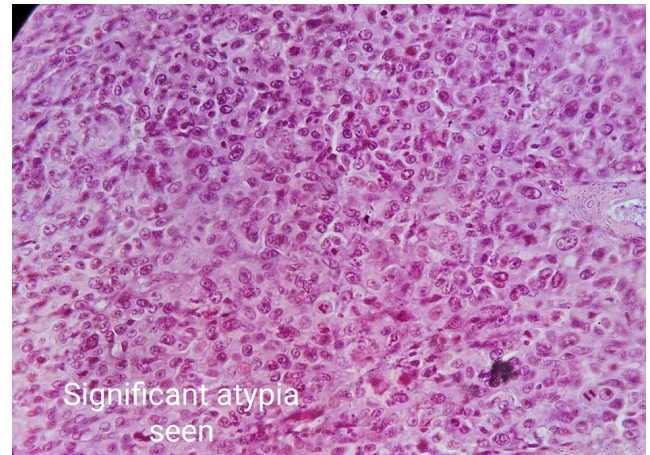


**Figure 1:** Gross image of the sample of uterus

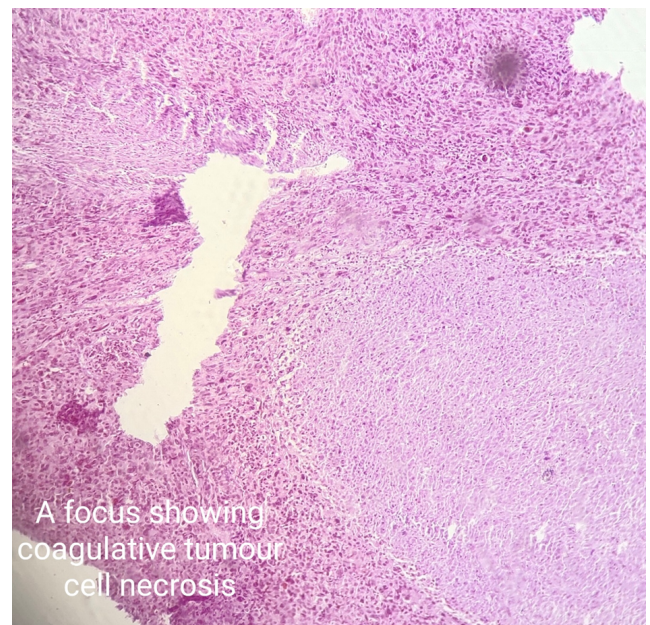
Endometrium, uterine serosa, cervix, bilateral adnexae were not involved. Although cervix showed chronic cervicitis with mild to moderate dysplasia.

No lymph nodes were identified.

TNM staging was T<sub>1c</sub>N<sub>x</sub>M<sub>x</sub>. FIGO staging was 1<sub>c</sub>.



**Figure 2:** Significant atypia seen



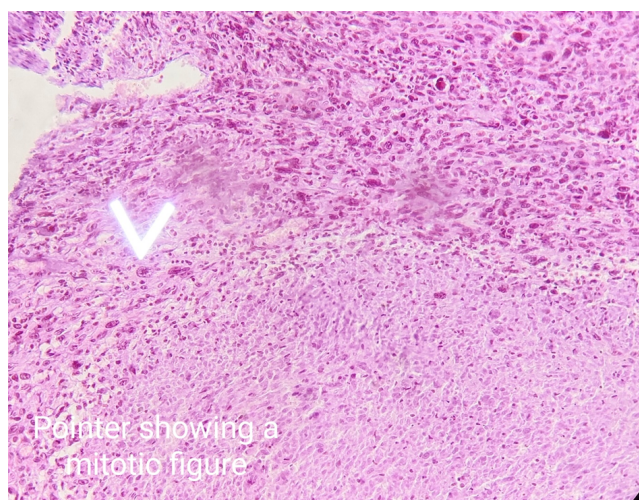
**Figure 3:** A focus showing coagulative tumour cell necrosis

### 4. Discussion

Uterine leiomyosarcoma is a malignant tumor not commonly diagnosed. It originates from the myometrial tissue.

The diagnosis of leiomyosarcoma is made on the basis of a triad of histopathological features - notable atypia, raised mitotic activity and coagulative tumour cell necrosis.<sup>5</sup>

The triad mentioned above plays a pivotal role in inferring the diagnosis of uterine smooth muscle tumours which show typical smooth muscle differentiation and include specific subtypes of leiomyoma like mitotically active leiomyoma, cellular leiomyoma, apoplectic leiomyoma, fumarate dehydrogenase-deficient leiomyoma, leiomyoma with bizarre nuclei,



**Figure 4:** Pointer showing amitotio

epithelioid leiomyoma, myxoid leiomyoma, smooth muscle tumour of uncertain/low malignancy potential (STUMP) and leiomyosarcoma. Leiomyosarcoma also needs to be differentiated from endometrial stromal sarcoma (especially those variants that have spindle cells), Inflammatory myofibroblastic tumour, undifferentiated sarcoma, sarcomatous component of adenocarcinoma or carcinosarcoma, malignant solitary fibrous tumour and extension of gastrointestinal tumour from the rectum.<sup>6</sup> Patterns of necrosis seen in uterine smooth muscle tumours are coagulative tumour cell necrosis and hyalinizing necrosis. While coagulative tumour cell necrosis presents with an abrupt transition between preserved and necrotic cells, the hyalinizing necrosis features a distinct zonal pattern with peripheral zone of granulation tissue and even more peripheral variable amount of hyaline eosinophilic collagen.<sup>7</sup>

Coagulative tumour cell necrosis may be confused with acute ischemic necrosis but the presence of hyperchromasia and nuclear pleomorphism in the shadow cells of the necrotic tumour points toward the former. Neoplasms with moderate to severe atypia often display enlarged and occasionally abnormal mitotic figures. Also, more than one or two enlarged abnormal mitotic figures are sufficient to classify a tumour's atypia as moderate to severe.

In case of uterine smooth muscle tumours with standard smooth muscle differentiation, presence of Tumour cell necrosis narrows down the diagnosis to STUMP and Leiomyosarcoma, where atypia may be either diffuse moderate to severe or none to mild.

If the atypia is none to mild and mitotic figures are less than 10 per high power field, the diagnosis points towards STUMP. If the atypia is none to mild and the mitotic figures are more than 10 it is more indicative of leiomyosarcoma, furthermore if the atypia is diffuse

moderate to severe, any level of mitotic figures indicate a diagnosis of leiomyosarcoma. Also, in the absence of tumour necrosis factor and diffuse moderate to severe atypia, less than 10 mitotic figures per 10 high power field the diagnosis is STUMP and more than 10 mitotic figures per 10 high power field is diagnosed as leiomyosarcoma.<sup>6</sup>

In the case presented the presence of coagulative tumour cell necrosis was distinctly seen abruptly transitioning with the preserved cells and the cellular atypia was ascertained to be moderate to severe. The mitotic figures too were easily visualised. On sectioning of uterine leiomyosarcoma, a fleshy, variegated cut surface with common hemorrhage and/or necrosis can be noted. Alternatively if a smooth muscle tumor on gross examination has the typical white, firm, and whorl cut surface, it is often benign.<sup>8</sup> But in the given case the cut surface was fleshy, homogenous, with no visible hemorrhage or necrosis.

The molecular basis of development of uterine leiomyosarcoma are incompletely known, recently chromosomal realignment has been recognized as an oncogenic mechanism by genome-wide studies. p16 and p53 which act as cell cycle regulators are often overexpressed in these cases and appear to be linked with the major alterations of the sarcomagenesis.<sup>9</sup>

Regarding treatment of the uterine sarcomas, surgery is the ultimate solution and provides a leverage in survival. Disease should ideally be resected unaccompanied by fragmentation with negative surgical margins.<sup>10,11</sup> Following points should be considered in daily gynecological practice specially in the perimenopausal women presenting with a large uterine mass: i) morcellation should be averted when malignancy is suspected owing to the likelihood of intra-abdominal disease dissemination; ii) a precise pre-operative workup should be done to reduce the risk of an undiagnosed occult malignancy by using MRI and/or an expert guided sonogram.<sup>12</sup>

## 5. Conclusion

Uterine leiomyosarcoma is a rare malignant tumour which is difficult to diagnose on imaging modalities. At times, it is difficult to ascertain the malignant nature of a uterine mass intra-operatively or during grossing due to its benign macroscopic appearance. In such cases incidental diagnosis through histopathological analysis is the only possibility. Differentiating leiomyosarcoma is important from other uterine smooth muscle tumours which show standard smooth muscle differentiation, like various subtypes of leiomyoma and smooth muscle tumour of uncertain/low malignancy potential (STUMP). The triad of cellular atypia, mitotic figures and coagulative tumour cell necrosis plays a pivotal role in doing so.

Care should be taken in routine gynecological practice to avoid morcellation, specially in a perimenopausal woman presenting with a large fibroid to avoid intra-abdominal

dissemination of the tumour.

## 6. Source of Funding

None.

## 7. Conflict of Interest

None.

## References

- Cao S, Liu Y, Bai X, Wang L. A Case Report of Uterine Leiomyosarcoma. *Onco Targets Ther.* 2019;12:8583–6.
- nappi L, Mele G, Angioni S, Sardo ADS, Cicinelli E, Greco P. Uterine leiomyosarcoma: report of three cases and review of the literature. *Eur J Gynaecol Oncol.* 2014;35(3):328–31.
- Roberts ME, Aynardi JT, Chu CS. Uterine leiomyosarcoma: A review of the literature and update on management options. *Gynecol Oncol.* 2018;151(3):562–72.
- Dunphy L, Sheridan G. Uterine leiomyosarcoma: a rare clinical entity. *BMJ Case Rep.* 2021;14(8):e244233.
- Ganesan R. Uterine smooth muscle tumour of uncertain malignant potential (STUMP): Where are we now? *Case Rep Womens Health.* 2020;26:e00176.
- Blaustein A, Kurman RJ. Blaustein's pathology of the female genital tract. New York: Springer; 2011.
- kempson RL, Hendrickson MR. Smooth Muscle, Endometrial Stromal, and Mixed Müllerian Tumors of the Uterus. *Mod Pathol.* 2000;13(3):328–42.
- Oliva E. Practical issues in uterine pathology from banal to bewildering: the remarkable spectrum of smooth muscle neoplasia. *Mod Pathol.* 2015;29(1):104–20.
- paudel P, Dhungana B, Shrestha E, Verma D. Leiomyosarcoma of the Uterus: A Rare Diagnosis. *Cureus.* 2021;13(8):e17418.
- Ricci S, Stone RL, Fader AN. Uterine leiomyosarcoma: Epidemiology, contemporary treatment strategies and the impact of uterine morcellation. *Gynecol Oncol.* 2017;145(1):208–16.
- Wui WJ, Greer BE, Abu-Rustum NR, Apte SM, Campos SM, Cho KR, et al. Uterine Sarcoma, Version 1.2016: Featured Updates to the NCCN Guidelines. *J Natl Compr Canc Netw.* 2015;13(11):1321–31.
- Bogani G, Chiappa V, Ditto A, Martinelli F, Signorelli M, Lorusso D. Morcellation of apparent benign uterine myoma: assessing risk to benefit ratio. *J Gynecol Oncol.* 2016;27(4):e37.

## Author biography

**Swati Priya**, Junior Resident  <https://orcid.org/0009-0006-0649-3231>

**Manoj Kumar Paswan**, Associate Professor

**Saurav Banerjee**, Tutor

**Arvind Kumar**, Tutor

**Sunil Mahto**, Associate Professor

**Cite this article:** Priya S, Paswan MK, Banerjee S, Kumar A, Mahto S. An occult leiomyosarcoma in a hysterectomy specimen presumed to be uterine fibroid preoperatively: A case report. *Indian J Pathol Oncol* 2024;11(1):73-76.