



Case Report

Anaplastic multiple myeloma- A diagnostic dilemma

Sulagna Giri^{1*}, Rajarshi Aich², Atoshi Basu¹

¹Dept. of Pathology, Apollo Multispeciality Hospital, West Bengal, India

²Dept. of Pathology, Chittaranjan National Cancer Institute, West Bengal, India



ARTICLE INFO

Article history:

Received 11-02-2024

Accepted 28-03-2024

Available online 17-04-2024

Keywords:

Anaplastic

Myeloma

Lymphoma

Immunophenotyping

ABSTRACT

Anaplastic myeloma (AM) represents a rare and aggressive variety of multiple myeloma (MM) which is morphologically composed mainly of immature plasma cells with nuclear enlargement and multilobulation. This variant can be confused with high grade lymphoma, metastatic carcinoma or even with dysplastic megakaryocytes in bone marrow study, posing a diagnostic challenge. Here, we present a case of a 71 years old male with complaints of body ache, progressive weakness for a month and a recent history of fall causing 7th and 10th rib fractures. Biochemical examination revealed raised serum calcium, LDH, 24 hour urinary protein, raised lambda on serum free light chain assay and marginally high serum creatinine. PET- CTS revealed lytic lesions involving multiple long and flat bones. Bone marrow aspirate showed 81% large anaplastic cells with marked nuclear convolution. Immunophenotyping showed positivity for CD38, CD138, CD56 along with lambda restriction. Composite consideration of clinical features, biochemical investigations, hematological workup and immunophenotyping led to a final diagnosis of anaplastic multiple myeloma.

This is an Open Access (OA) journal, and articles are distributed under the terms of the [Creative Commons Attribution-NonCommercial-ShareAlike 4.0 License](https://creativecommons.org/licenses/by-nc-sa/4.0/), which allows others to remix, tweak, and build upon the work non-commercially, as long as appropriate credit is given and the new creations are licensed under the identical terms.

For reprints contact: reprint@ipinnovative.com

1. Introduction

Anaplastic variant of plasma cell myeloma or anaplastic myeloma (AM) represents a rare and aggressive variety of multiple myeloma (MM) which is also known to be more treatment resistant leading to poorer prognosis than conventional myeloma.^{1,2} Morphologically AM is composed mainly of immature plasma cells with nuclear enlargement, high nuclear pleomorphism and lobulation and also tend to occur more in extra medullary tissues like liver, lung, spleen, lymph node etc.¹⁻³ The anaplastic and highly variable morphology of this variant can be confused with anaplastic large cell lymphoma or other high grade lymphoma, metastatic carcinoma or even dysplastic megakaryocytes which can pose a diagnostic challenge leading to diagnostic delay unless there is high

clinical suspicion.¹⁻³ In addition, to bone marrow study, flowcytometry (FCM) and immunohistochemistry (IHC) is required for confirmative diagnosis. Anaplastic myeloma is rarely described with only a few reported cases available in the literature.² We present a case of anaplastic myeloma in an elderly male which posed a diagnostic challenge.

2. Case Report

A 71 years old male presented with complaints of body ache, bone pain and progressive weakness of one month duration. He had a recent history of fall with 7th and 10th rib fracture. Physical examination was unremarkable except for mild tenderness over spine and joints of extremities. There was no organomegaly or lymphadenopathy. His complete hemogram showed Hb- 9.1 gm/ dl, Total Leucocyte Count- 4900/ cumm with a differential count of neutrophils- 59%, lymphocytes- 23%, monocytes- 05%,

* Corresponding author.

E-mail address: giri.sulagna@gmail.com (S. Giri).

eosinophil- 01%, myelocytes- 05%, metamyelocytes- 07%, 4NRBCs/ 100WBC and platelet count- 35,000/cumm. Peripheral blood smear showed leucoerythroblastic picture with predominantly normocytic normochromic anaemia and thrombocytopenia with no abnormal cells. No rouleaux formation was seen. ESR was 52 mm for 1st hour.

Biochemical study revealed total protein of 6.0 gm/dl, albumin 3.5 gm/ dl with A: G ratio of 1.4:1. Serum calcium was raised (12.0 mg/ dl) and serum creatinine was marginally high (1.3mg/ dl). Serum LDH was markedly elevated (5123 U/ L). 24 hrs urinary protein was also raised (1421 mg/ 24hrs). Viral serology for HIV, hepatitis B & C was negative. PET- CT Scan with contrast revealed multiple lytic lesions and bilateral marrow deposits involving B/ L femora, innominate bones, sacrum, all cervico-dorso- lumbar vertebrae, sternum, multiple ribs, scapulae, clavicles, mandible and sphenoid. Radiological study didn't show any evidence of an occult primary malignancy. Serum protein electrophoresis showed no 'M' spike. However, lamda free light chain was raised (466 mg/ L) with low serum free light chain (kappa/ lamda) ratio (0.025).

Bone marrow aspirate showed 81% of large anaplastic cells with marked nuclear convolutions, multilobations and pleomorphism, condensed chromatin with abundant basophilic cytoplasm. Many cells also showed multinucleation.

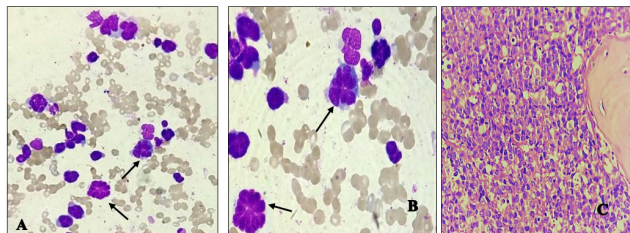


Figure 1: Bone marrow aspirate demonstrating atypical cells with multiple lobulations (arrows) at x 400 (A) and x 1000; (B): Magnifications. Bone marrow biopsy; (C): Showing sheets of atypical cells at x 400 magnification

Bone marrow biopsy was hypercellular with interstitial infiltration by undifferentiated large malignant cells with similar morphology like bone marrow aspiration. Overall bone marrow picture was suggestive of involvement of bone marrow by malignant cells. Possibility of anaplastic large cell lymphoma- leukaemia/ other high grade lymphoma/ metastasis were considered.

Next flowcytometry (FCM) was done to confirm the lineage of the malignant cells. On FCM 52.4% cells were gated with low forward and moderate side scatter and expressed dim to negative CD 45 positivity. Other positive markers on FCM were CD 38(99.00%), CD 56 (45.00%), HLA- DR (34.70%), CD 117(32.00%) & CD 15(41.00%).

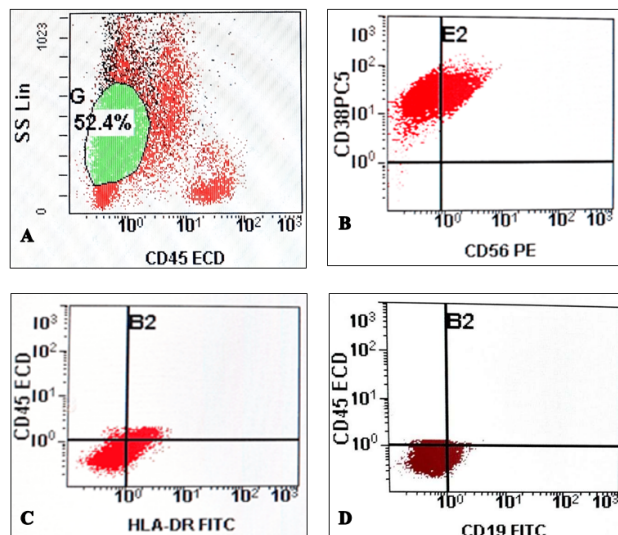


Figure 2: Immunophenotype of the atypical cells on Flowcytometry. (A): Moderate side scatter with dim to negative CD45. (B): CD38 (99%) and CD56 (45%) positive. (C): HLA DR positive (34.7%). (D): The gated cells were negative for CD19

All other myeloid, erythroid, megakaryocytic and lymphoid markers and immaturity markers were negative. In view of dim to negative CD 45, negative CD 19 with CD56/ CD38 co positivity, a possibility of plasma cell neoplasm was raised. IHC study was carried out on the bone marrow biopsy with CD20, CD 30, CD45, CD 138, CK-HMW, Kappa- Lambda and Ki- 67, which showed CD 138 positivity and clonal lambda light chain restriction with 20% Ki-67 positivity.

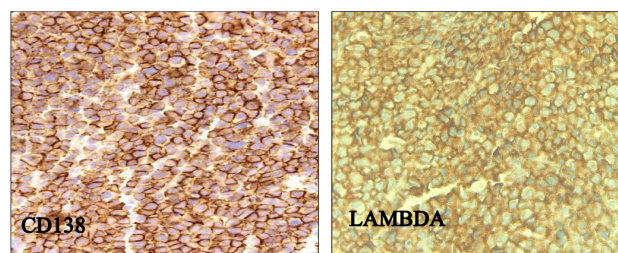


Figure 3: Immunohistochemistry on bone marrow biopsy: Positive for CD138 and Lambda, respectively (x 400 magnification)

Other markers came out to be negative which further indicated towards diagnosis of plasma cell neoplasm. Composite consideration of clinical features (CRAB features +), raised ESR, bone marrow study impression (presence of large anaplastic plasma cells) along with characteristic FCM and IHC studies (CD38+, CD138+, CD 56+, HLA- DR+, LAMDA+, CD 45 dim- negative, CD 19 -, CD20-, CK-), led to a final diagnosis of anaplastic variant of plasma cell myeloma. Cytogenetics study wasn't carried out in our case. The patient was started on VRd (Bortezomib,

Lenalidomide and Dexamethasone) for multiple myeloma with initial good response.

3. Discussion

Myeloma cells are well known for their variable morphology, which range from mature looking plasma cells to anaplastic form.^{4,5} Anaplastic myeloma is an uncommon variant of plasma cell neoplasm (PCN), the true incident of which is largely uncommon and it may raise a diagnostic dilemma.^{1,2,5} Anaplastic plasma cells can be present at the time of initial diagnosis or can evolve in the process of disease progression.^{1,4,6} Some salient characteristics of AM as observed by many authors include a relatively younger age of presentation, cytopenias, extramedullary involvement and aggressive clinical course than conventional myeloma.^{3,4,6,7} In our case, patient presented in his early 70's with bone pain, bicytopenia and presence of anaplastic cells in his bone marrow at the time of initial diagnosis but there was no extramedullary involvement. As most of his presenting symptoms and some hematological and serological investigation findings were favouring multiple myeloma, serum electrophoresis study was carried out which showed absence of 'M' band. The absence of 'M' band in multiple myeloma has also been reported by Singh et al. in their case report.⁸ Bone marrow examination in our case showed large immature cells with marked nuclear convolution, lobulation and multinucleation with absence of typical morphological feature of plasma cells, led to wide range of differential diagnosis, specially anaplastic large cell lymphoma or other high grade lymphomas. There was low suspicion of PCN in our case due to absence of 'M' band and conventional multiple myeloma morphology in bone marrow study. In many studies, authors have mentioned about the diagnostic difficulties they have faced for this variant due to its variable and bizarre morphology.^{1,2,5} To arrive at a definite diagnosis, both immunophenotyping by FCM and IHC were done which showed positivity for CD38, CD138, CD56, CD117 and lamda restriction favouring plasma cell neoplasm. All other myeloid, lymphoid and epithelial markers came out negative which ruled out possibilities of other malignancies. Foucar et al. has stated that the morphologic and flowcytometric feature in view of DNA/RNA content of anaplastic myeloma are different from typical MM and extramedullary plasmacytoma.⁶ The association of cytologic atypia with increased DNA content has also been reported.⁶ Anaplastic variant of MM is associated with complex karyotyping with significantly higher frequencies of 1q21 amplification, 17p(p53) deletion, deletion t(4;14) and/or chromosome 13 anomalies and near tetraploidy.^{3,7-9} Most cases of this variant follow a aggressive disease course with poor prognosis mainly due to poor treatment outcome.^{1,9,10} Few recent studies has revealed better and sustained response with triple drug regimens.^{7,10}

4. Conclusion

To conclude, a high degree of clinical suspicion, clinical association and knowledge of such rare morphological variations, proper application of ancillary techniques along with relevant biochemical and immunological investigations are essential to confirm the diagnosis of anaplastic myeloma as morphology can be quite variable and peculiar for this type. In a case of undifferentiated hematolymphoid malignancy having bizarre nuclear morphology, one should include both CD 38 and CD 138 in the extended panel of antibodies to exclude plasma cell neoplasm.

5. Source of Funding & Conflict of Interest

None.

References

1. Shivangi H, Ruchi G, Khaliqur R. Pleomorphic multinucleated plasma cells simulating megakaryocytes in an anaplastic variant of myeloma. *Turk J Haematol.* 2018;35(2):150–1.
2. Rao S, Kar R, Pati HP. Anaplastic myeloma: a morphological diagnostic dilemma. *Indian J Hematol Blood Transfus.* 2008;24(4):188–9.
3. Sethi S, Miller I. Plasma cell myeloma with anaplastic transformation. *Blood.* 2016;128(16):2106.
4. Suchman AL, Coleman M, Mouradian JA, Wolf DJ, Saletan S. Aggressive plasma cell myeloma: A terminal phase. *Arch Intern Med.* 1981;141(10):1315–20.
5. Vasnik GK, Venkatesan S, Sharma S, Malik A. Plasma cell neoplasm with varied morphology: A report of two cases. *J Lab Physicians.* 2019;11(3):281–3.
6. Foucar K, Raber M, Foucar E, Barlogie B, Sandler CM, Alexanian R. Anaplastic myeloma with massive extra- medullary involvement. *Cancer.* 1983;51(1):166–74.
7. Chang H, Kajal B. Anaplastic variant of plasma cell myeloma with Dutcher bodies. *Blood.* 2016;127(25):3291.
8. Singh N, Agrawal N, Mehta A, Panaych A, Sekhri R. CD38-Negative Myeloma with Anaplastic Morphology at Presentation: A Case Report. *Indian J Hematol Blood Transfus.* 2018;34(2):362–4.
9. Ammannagari N, Celotto K, Neppalli V, Lee K, Holstein SA. Anaplastic Multiple myeloma: an aggressive variant with a poor response to novel therapies. *Clin Lymphoma Myeloma Leuk.* 2016;16(9):129–31.
10. Agarwal M, Kanakry J, Arnold CA, Suzman DL, Mathieu L, Kasamon YL, et al. Sustained remission and reversal of end-organ dysfunction in a patient with anaplastic myeloma. *Ann Hematol.* 2014;93(7):1245–6.

Author biography

Sulagna Giri, Associate Consultant

Rajarshi Aich, Senior Resident

Atoshi Basu, Senior Consultant

Cite this article: Giri S, Aich R, Basu A. Anaplastic multiple myeloma-A diagnostic dilemma. *Indian J Pathol Oncol* 2024;11(1):67-69.