

Content available at: <https://www.ipinnovative.com/open-access-journals>

Indian Journal of Pathology and Oncology

Journal homepage: [www.ijpo.co.in](http://www.ijpo.co.in)

## Case Report

# Malignant epithelial neoplasm of adnexal origin: Hidradenocarcinoma of breast: A rare case report

Viral Bharatkumar Suthar<sup>1</sup>, Pragati Atulbhai Shah<sup>1</sup>, Isha Sharad Pathak<sup>1</sup>,  
Minesh Biharilal Gandhi<sup>1\*</sup>

<sup>1</sup>Dept. of Pathology, Smt. NHL Municipal Medical College, Ahmedabad, Gujarat, India



### ARTICLE INFO

#### Article history:

Received 30-01-2024

Accepted 07-03-2024

Available online 17-04-2024

#### Keywords:

Sweat gland tumor

Breast

Hidradenocarcinoma

Malignant

### ABSTRACT

Hidradenocarcinoma is rare sweat gland tumor of skin which may have both apocrine and eccrine variants. We report a case of 27 year old postpartum female patient presented with complain of swelling over right breast since 8 months with pain on and off. The ultrasonography report revealed possibility of fibroadenoma (BIRADS CATEGORY -II). The patient underwent FNAC which was reported as fibroproliferative breast disease with atypia. Then wide local excision of mass was performed, the pathological report stated the tumor as a malignant epithelial neoplasm of adnexal origin – hidradenocarcinoma type and Immunohistochemical analysis revealed negative staining for ER, PR, HER2. This case represent difficulty in diagnosis of tumor. Histopathological features are main key to distinguish it from other entities.

This is an Open Access (OA) journal, and articles are distributed under the terms of the [Creative Commons Attribution-NonCommercial-ShareAlike 4.0 License](https://creativecommons.org/licenses/by-nc-sa/4.0/), which allows others to remix, tweak, and build upon the work non-commercially, as long as appropriate credit is given and the new creations are licensed under the identical terms.

For reprints contact: [reprint@ipinnovative.com](mailto:reprint@ipinnovative.com)

## 1. Introduction

Hidradenocarcinoma is very rare and slow growing tumor of sweat gland.<sup>1</sup> Most commonly it involves scalp (40%) followed by face (30%) and rarely present on extremities.<sup>2</sup> Most of the cases arises de novo, in rare condition it may arises from preexisting hidroadenoma.<sup>3,4</sup> It is locally aggressive and can recur after complete excision. The written consent was taken from patient.

## 2. Case Report

A 27-year old postpartum female patient presented with complain of swelling over right breast since 8 months with increasing in size associated with pain on and off. On physical examination, 2 x 1 cm sized swelling in inner lower quadrant of right breast, irregular in shape, smooth margin, firm to hard on palpation with normal overlying skin.

Ultrasonography of breast showed, well defined hypoechoic lesion with minimum internal vascularity and posterior acoustic enhancement at lower inner quadrant of right breast with possibility of fibroadenoma (BIRADS II). Patient underwent a diagnostic fine needle aspiration cytology and it shows Category-III: Atypical [The International Academy of cytology Yakohama system for reporting for Breast FNAC (2020)] and biopsy was advised.

### 2.1. Gross

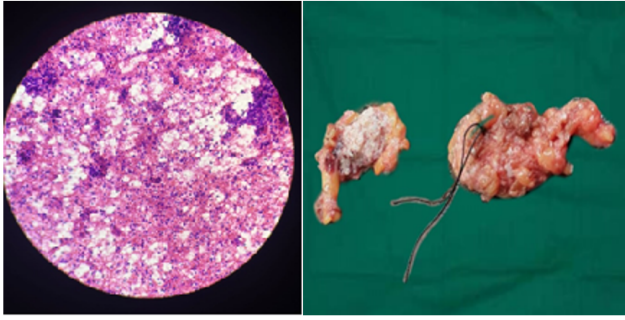
The specimen measures 4.3 x 3.6 x 1.4 cm with one friable nodule measuring 2 x 1.6 cm. On cut section from nodular area whitish growth measuring 1.7 x 1.1 cm identified.

### 2.2. Microscopic examination

Histopathological sections from right breast mass show neoplastic cells arranged in solid sheets and variably sized nodules in infiltrative growth pattern. There is a presence of microscopic heterogeneity in both its cellular composition

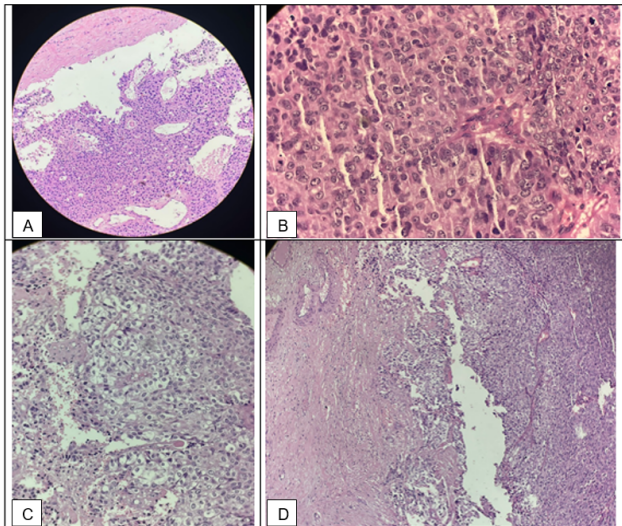
\* Corresponding author.

E-mail address: [viral\\_suthar68@gmail.com](mailto:viral_suthar68@gmail.com) (M. B. Gandhi).

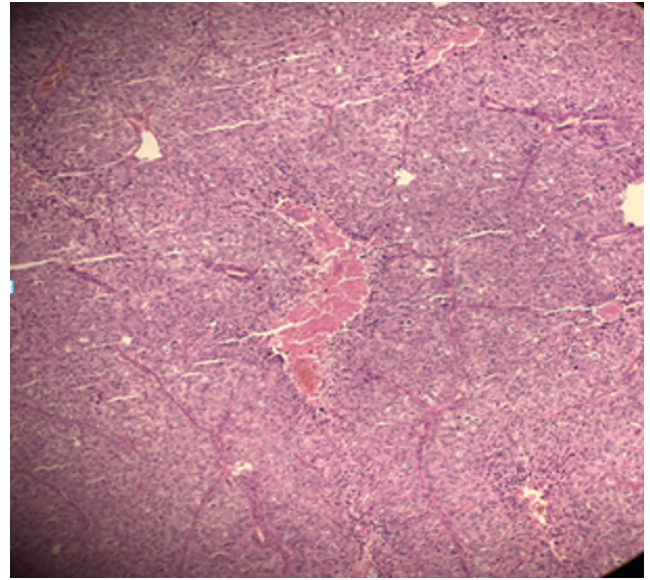


**Figure 1:** Left: Fine needle cytology. Right: Gross picture of breast tissue

and cytological grade. The cellular composition shows neoplastic cells composed of squamoid cells, transitional elements and at places clear cells. There is a presence of glandular component recognized by having round glands devoid of epithelial cells with intracytoplasmic lumina. With regard to cytological grade, both low and high grade tumor cells recognized. Focal duct formation, sclerosis of stroma and entrapped hyalinized vascular structure are evident.<sup>5</sup> Atypical mitosis are also seen (22/10 HPF). Surgical margins are free from tumor. No evidence of ductal carcinoma insitu identified. Surrounding breast shows lactational changes. Overall findings reported as a Malignant epithelial neoplasm, adnexal origin – Hidradenocarcinoma type. Separately received total 11 lymphnodes were free from tumor. Immunohistochemistry was advised to confirm the diagnosis.



**Figure 2:** A): Focal duct formation, sclerosis of stroma and entrapped hyalinized vascular structure. (H & E,20x); B): Atypical mitosis.(H &E,40x); C,D): Neoplastic cells composed of squamoid appearing, transitional like and at places clear cells (H &E,40x)



**Figure 3:** Neoplastic cells with area of central necrosis. (H &E,40x)

### 2.3. Immunohistochemistry Report

Estrogen receptor: Negative

Progesteron receptor: Negative

HER2: Negative

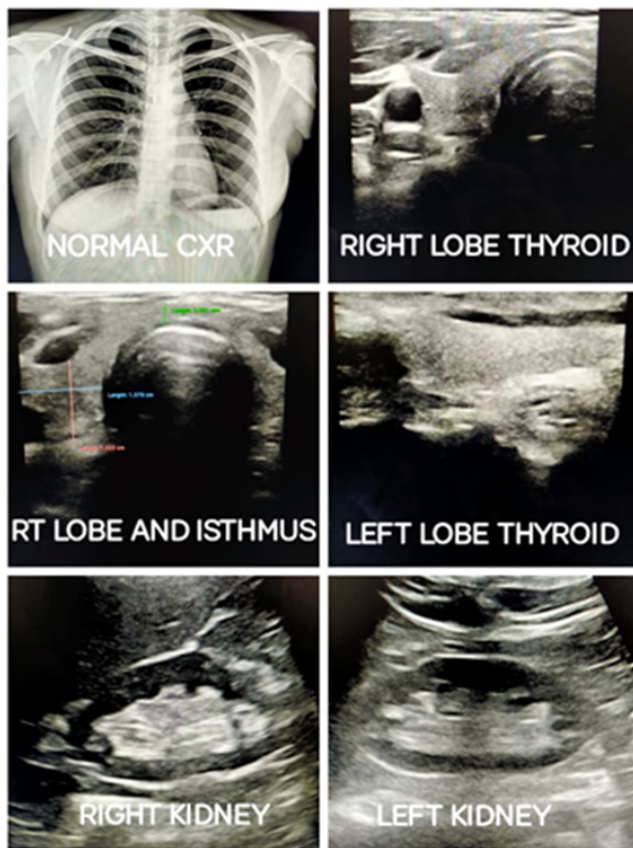
Overall findings were reported as malignant epithelial neoplasm – Hidradenocarcinoma type.

### 3. Discussion

Hidradenocarcinoma is very rare malignant intradermal tumor of breast having equal incidence in male and female of 5<sup>th</sup> to 7<sup>th</sup> decade. It mimics to breast carcinoma clinically and radiologically. It is diagnostic challenging and confirmed only after complete excision. It is slow growing solitary painless nodule with or without overlying skin changes.<sup>6,7</sup>

It shows distant metastasis to regional lymphnode, lung, bone, brain, viscera, skin.<sup>8</sup> Hidradenocarcinoma are usually larger, asymmetric, and show infiltrative growth pattern into surrounding tissue.<sup>9</sup> Histologically, it shows lobulated mass with solid, cystic areas, cytological atypia with solid papillary architecture along with benign counterpart. The tumor is composed of polyhedral, squamoid, clear, poroid / transitional and rarely mucinous cells.<sup>10</sup> To diagnose malignancy, there should be infiltrative growth pattern, deep extension, nuclear pleomorphism, necrosis, vascular or perineural invasion, Mitosis of 4 or more/ 10 HPF, Ki-67 > 11%, PHH3 > 0.7% reported in malignant cases.<sup>11</sup> Immunohistochemistry studies are usually positive for cytokeratins, CEA, EMA, GCDPF-15 and p63, but negative for vimentin. Screening for HER2 overexpression and estrogen receptors should be considered in the tumor sample





**Figure 4:** Normal chest radiograph of PA view, Normal ultrasound of both kidneys and thyroid

due to its potential usefulness.<sup>12</sup> Hidradenocarcinoma stains with AE1/ AE3, CK5, and CK6 with high Ki-67 expression helps to distinguish it from atypical hidradenoma. Metastatic clear cell carcinoma of thyroid, lung and kidney mimics to clear cell hidradenocarcinoma; TTF – 1 may be useful to differentiate hidradenocarcinoma from thyroid and lung carcinomas.<sup>13</sup> Early diagnosis and treatment are the two variables which influence long-term prognosis. Survival depends on the size and the systemic dissemination of the tumor. The only treatment that has been shown to positively influence survival is extensive surgical resection of the tumor (margins between 3 and 5cm are recommended to ensure negativity). Diagnostic surgery is usually performed, requiring a second intervention to extend margins and study the lymph nodes once the tumor type has been determined.<sup>14</sup> The study of the sentinel lymph node is recommended<sup>4</sup> requiring lymphadenectomy associated with radiotherapy in case of involvement.

Adjuvant treatment with chemotherapy and radiotherapy should only be considered in cases of large tumor size, high-risk histopathological characteristics or metastasis at the time of diagnosis.<sup>3</sup>

#### 4. Conclusion

Hidradenocarcinoma breast is uncommon malignant tumor of skin may mimics to breast carcinoma. Due to its rarity and atypical presentation it is difficult to diagnose. Early diagnosis and management improve patient's outcome.

#### 5. Source of Funding

None.

#### 6. Conflict of Interest

None.


#### Acknowledgments

The authors thank Dr. Cherry K Shah and Dr. Nanda N Jagrit for guidance.

#### References


1. Avraham JB, Villines D, Maker VK, August C, Maker AV. Survival after resection of cutaneous adnexal carcinomas with eccrine differentiation: risk factors and trends in outcomes. *J Surg Oncol.* 2013;108(1):57–62.
2. Tolkachjov SN, Hocker TL, Hochwalt PC, Camilleri MJ, Arpey CJ, Brewer JD, et al. Mohs micrographic surgery for the treatment of hidradenocarcinoma: the Mayo Clinic experience from 1993 to 2013. *Dermatol Surg.* 2015;41(2):226–31.
3. Soni A, Bansal N, Kaushal V, Chauhan AK. Current management approach to hidradenocarcinoma: a comprehensive review of the literature. *Ecancermedalscience.* 2015;9:517.
4. Mote DG, Ramamurti T, Babu BN. Nodular hidradenoma of the breast: A case report with literature review. *Indian J Surg.* 2009;71(1):43–5.
5. Kazakov DV, Michal M, Kacerovska D, Mckee PH. Cutaneous adnexal tumors. Philadelphia, Pa, USA: Wolters Kluwer Health; 2012.
6. Gao T, Pan S, Li M, Su R. Prognostic analysis of hidradenocarcinoma: a SEER-based observational study. *Ann Med.* 2022;54(1):454–63.
7. Chambers I, Rahal AK, Reddy PS, Kallail KJ. Malignant clear cell hidradenoma of the breast. *Cureus.* 2017;9(3):e1064.
8. Gauerke S, Driscoll JJ. Hidradenocarcinomas: a brief review and future directions. *Arch Pathol Lab Med.* 2010;134(5):781–5.
9. Nazarian RM, Kapur P, Rakheja D, Piris A, Duncan LM, Mihm MC, et al. Atypical and malignant hidradenomas: a histological and immunohistochemical study. *Mod Pathol.* 2009;22(4):600–10.
10. Al-Adawi SS, Al-Qasabi B, Al-Bahri M, Aljarrah A, Al-Aghbari S. Clear Cell Hidradenoma of the Breast Diagnosed on a Core Needle Biopsy: A case report and review of the literature. *Sultan Qaboos Univ Med J.* 2020;20(3):357–61.
11. Nazarian RM, Kapur P, Rakheja D, Piris A, Duncan LM, Mihm MC, et al. Atypical and malignant hidradenomas: a histological and immunohistochemical study. *Mod Pathol.* 2009;22(4):600–10.
12. Giorgini E, Tugnoli G, Aprile S, Collina G, Villani S, Biscardi A. Malignant nodular hidradenocarcinoma arising on the areola of a male patient: case report of an “orphan disease” and review of the literature. *J Carcinogene Mutagene.* 2012;3:2157–518.
13. Obaidat NA, Alsaad KO, Ghazarian D. Skin adnexal neoplasms-part 2: an approach to tumours of cutaneous sweat glands. *J Clin Pathol.* 2007;60(2):145–59.
14. Gauerke S, Driscoll JJ. Hidradenocarcinomas: a brief review and future directions. *Arch Pathol Lab Med.* 2010;134(5):781–5.

**Author biography**

**Viral Bharatkumar Suthar**, Resident  <https://orcid.org/0009-0001-3109-7023>

**Pragati Atulbhai Shah**, Resident  <https://orcid.org/0009-0004-1039-4338>

**Isha Sharad Pathak**, Resident  <https://orcid.org/0000-0001-5997-3286>

**Minesh Biharilal Gandhi**, Associate Professor  <https://orcid.org/0009-0001-7888-3347>

**Cite this article:** Suthar VB, Shah PA, Pathak IS, Gandhi MB. Malignant epithelial neoplasm of adnexal origin: Hidradenocarcinoma of breast: A rare case report. *Indian J Pathol Oncol* 2024;11(1):63-66.