

Content available at: <https://www.ipinnovative.com/open-access-journals>

Indian Journal of Pathology and Oncology

Journal homepage: [www.ijpo.co.in](http://www.ijpo.co.in)

## Case Report

# A curious case of benign ovarian teratoma with multiple malignant transformations: A histopathologists quagmire

Ruchi Rastogi<sup>1\*</sup>, Gunmala Bhatnagar<sup>1</sup>, Dipti Kalita<sup>1</sup>

<sup>1</sup>Dept. of Histopathology and Cytopathology, Batra Hospital and Medical Research Centre, New Delhi, India



### ARTICLE INFO

#### Article history:

Received 04-09-2023

Accepted 14-11-2023

Available online 11-12-2023

#### Keywords:

Malignant transformation

Mature cystic teratoma

Mucinous cystadenocarcinoma

Strumal carcinoid

### ABSTRACT

Mature cystic teratomas of ovary are common benign germ cell tumors that constitute about 20% of all the ovarian tumors. These tumors however have a rare potential for malignant transformation 0.17-2% and therefore there is a requirement for intraoperative diagnosis to establish an appropriate line of treatment. Incidence of mature cystic teratoma undergoing multiple types of malignant transformation in the same patient is extremely rare and only a small number of such cases have been published in literature. Histopathology and immunohistochemistry are the gold standard for diagnosis and remains the mainstay for defining the treatment course and prognosis.

This is an Open Access (OA) journal, and articles are distributed under the terms of the [Creative Commons Attribution-NonCommercial-ShareAlike 4.0 License](https://creativecommons.org/licenses/by-nc-sa/4.0/), which allows others to remix, tweak, and build upon the work non-commercially, as long as appropriate credit is given and the new creations are licensed under the identical terms.

For reprints contact: [reprint@ipinnovative.com](mailto:reprint@ipinnovative.com)

## 1. Introduction

Mature cystic teratomas (MCT) of ovary are common benign germ cell tumors that constitute about 20% of all the ovarian tumors.<sup>1</sup> Although these tumors are usually benign, an infrequent risk of malignant transformation is warranted especially with menopause and increasing age and is estimated to be about 0.17 to 2%.<sup>2</sup> Amongst the cases with malignant transformation, squamous cell carcinoma is the most common type (80%)<sup>3</sup> and the remaining 20% comprises of thyroid carcinomas, adenocarcinomas, carcinoid tumors, transitional cell carcinoma and malignant melanoma.<sup>3-5</sup> Incidence of MCT undergoing multiple types of malignant transformation in the same patient is extremely rare and only a small number of such cases have been published in literature.

Here, we present a case of MCT undergoing malignant transformation to mucinous cystadenocarcinoma and strumal carcinoid which is an extremely rare occurrence.

\* Corresponding author.

E-mail address: [dr.ruchibansal@rediffmail.com](mailto:dr.ruchibansal@rediffmail.com) (R. Rastogi).

## 2. Case Report

A 53-year-old female patient presented to the OPD of our institute for complaint of pain abdomen associated with intermittent urinary obstruction along with history of mild on and off fever for past one and a half month. Initially, the patient was diagnosed with urinary tract infection based on the report of urine routine and microscopic examination and was treated for the same. However, her symptoms worsened and she presented with features of subacute intestinal obstruction and acute urinary retention and required urgent catheterization to relieve the same.

On ultrasonography, a large mass was visualized in the left ovary measuring 16x12x10 cms, abutting and compressing the urethra. Serological evaluation revealed normal CA-19.9 and CA 125 levels. The mass was suspected to be malignant and so a surgery followed by primary diagnosis on frozen section was planned to identify the nature of lesion. An ovarian mass measuring 16x12.5x12 cm was received for frozen diagnosis. On gross examination, the mass was lobulated externally and solid cystic filled with brownish and hemorrhagic fluid on cut

surface. Yellow to tan white areas were also noted along with a multiloculated solid area measuring 4x3x4 cm.

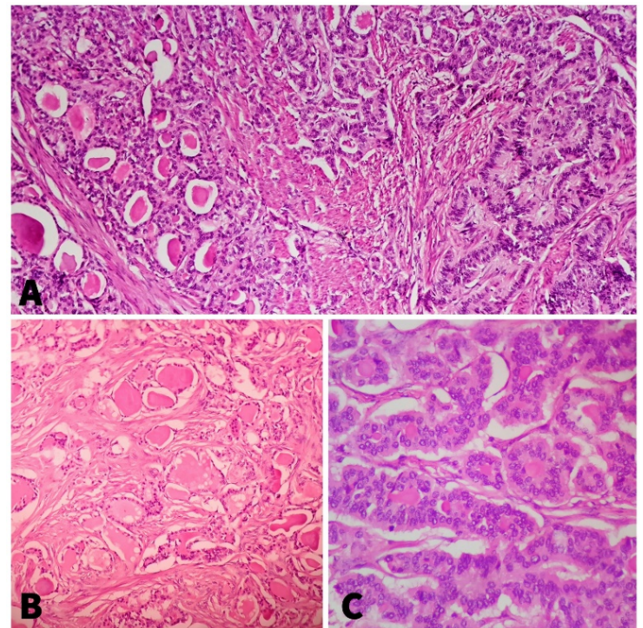
On microscopy of frozen sections, infiltrating neoplastic glands along with a mucinous tumor were seen in a sclerotic stroma and thus a diagnosis of a mucinous adenocarcinoma was suggested. However, few areas with sheets of cells in trabecular and glandular pattern were also seen in the mass suggesting the presence of another component possibly carcinoid. Subsequently, following the frozen section report, a radical surgery was performed excavating the left ovarian mass, omentum, appendix, left and right pelvic nodes and uterus cervix with bilateral adnexa.

Thereafter, detailed microscopic examination of the paraffin sections showed a MCT with strumal carcinoid and mucinous cystadenocarcinoma. Focal areas of calcification, bone formation, keratin deposition and fat were noted indicating reminiscent of a teratoma. Two different areas of malignant transformation were seen. Firstly, a multilobulated mucinous neoplasm lined by variable sized cuboidal cells with stratification, focal loss of polarity, high nuclear cytoplasmic ratio and hyperchromasia; goblet cells and stroma showing extravasated mucin along with invasive glands was seen. On immunohistochemistry these glands were positive for CK7 and CK20 indicating a primary mucinous adenocarcinoma of intestinal type. The second malignant transformation was seen in the solid nodule at one side measuring 4 cm in diameter. This nodule was composed of thyroid tissue with eosinophilic colloid in the lumen and sheets of tumour cells arranged in trabecular and glandular arrangement intimately mixed with each other. Morphologically, the tumor cells were monomorphic with granular salt and pepper like nuclear chromatin and abundant granular cytoplasm and showed nuclear overlapping and hyperchromasia along with infiltration into the stroma. Immunostains revealed these cells to be diffusely positive for synaptophysin and focally for chromogranin. The intermixed thyroid tissue was positive for TTF1. These findings were consistent with the diagnosis of strumal carcinoid. The uterus, cervix, right ovary and bilateral fallopian tubes did not reveal any significant lesion. The appendix was also free of malignancy.

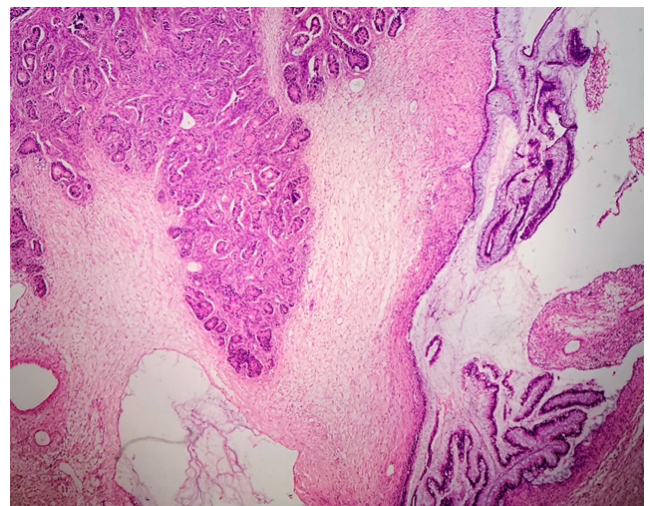
The final diagnosis of MCT with malignant transformation into mucinous cyst adenocarcinoma and strumal carcinoid stage I was made.

### 3. Discussion

Ovarian tumors are commonly seen in Gynecological practice. Histopathological diagnosis after surgery is the gold standard for their typing. Teratomas are common germ cell tumors and are derived from at least two of the three germ cell layers (i.e., Ectoderm, mesoderm and endoderm). They are classified as either mature or immature teratomas. Whereas mature teratomas presents as cystic lesions and are usually benign, immature teratomas are

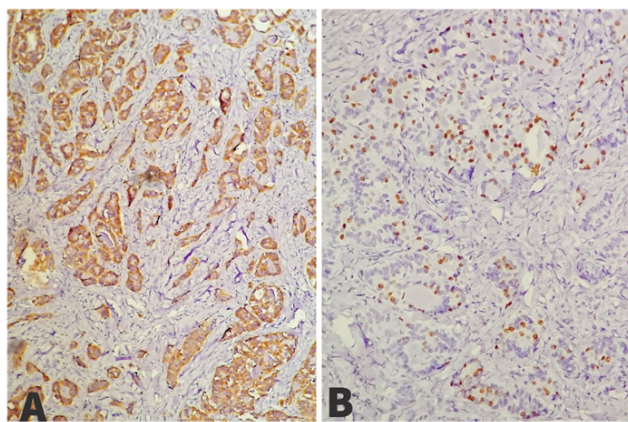


**Figure 1:** A): Sheets of tumour cells with granular salt and pepper like nuclear chromatin admixed with thyroid tissue with eosinophilic colloid in lumen. 10x, H&E. B): Strumal component. 40x, H&E. C): Carcinoid component. 40X, H&E



**Figure 2:** Mucinous cystadenocarcinoma component. 10x H&E

usually solid and malignant in nature. MCT are bilateral in 8-14% of cases.<sup>6</sup> They can present in all ages from children to post-menopausal women. A preoperative diagnosis is usually made on imaging and surgery remains the main stay for treatment of these tumors. These tumors however have a rare potential for malignant transformation and therefore there is a requirement for intraoperative diagnosis to establish an appropriate line of treatment. In our case, diagnosis of complex cystic mass was made on radiology and an intraoperative frozen was done which revealed



**Figure 3:** A): Carcinoid tumour cells showing positivity for synaptophysin. 40x; B): Thyroid tissue showing positivity for TTF1, 40X

the presence of mucinous cystadenocarcinoma. Due to limitation in sampling on the frozen samples all the malignant components were not reported. The presence of neoplastic glands, extravasated mucin in a sclerotic stroma along with areas showing sheets of cells in trabecular and glandular pattern created a dilemma for typing the malignant component. Detailed examination on paraffin sections however brought forth a clear picture.

Primary ovarian carcinoid is very rare and accounts for less than 0.1% of ovarian malignancies.<sup>7</sup> They are presumed to be derived from neuroendocrine cells of the gastrointestinal or respiratory epithelium.<sup>8</sup> They are of 4 types: -insular, strumal, trabecular and mucinous, however occurrence of mixed types is known. Insular type is most common and is accompanied by clinical features of carcinoid syndrome which may raise a suspicion of carcinoid tumour during preoperative investigations. Our patient however had no symptoms of carcinoid syndrome. Strumal carcinoid is the uncommon type and is composed of mixture of trabecular carcinoid and struma ovarii. Ovarian strumal carcinoid rarely metastasizes and such type of neoplasm are considered to be of low malignant potential. The treatment for such tumors includes hysterectomy with bilateral salpingo-oophorectomy and surgically debulking the metastasis or extra ovarian spread. These tumors are associated with virilism, post operative thyroid storm and hypothyroidism and therefore their management requires a postoperative thyroxin supplementation.

Mucinous tumors are associated with 2-11% of teratomas. They can be benign, borderline and malignant and are difficult to interpret. Malignant transformation to mucinous adenocarcinoma occurs in 6.8% of the cases.<sup>9</sup> It is important to note that most of the primary mucinous surface epithelial tumors show diffuse positivity for CK7 and variable expression of CK20 in contrast to secondary metastasis from the lower gastrointestinal tract like

colorectal or appendix, where the immunohistochemical profile is positive for CK20 but negative for CK7.<sup>10</sup> In our case also CK20 as well as CK7 were positive. There was no evidence of another malignant tumor elsewhere in the Gastrointestinal tract. Appendix was also normal. Therefore, the diagnosis of mucinous cystadenocarcinoma of the intestinal type arising from MCT was made.

Nine months post-operatively our patient is doing well with no evidence of disease and is under close surveillance.

#### 4. Conclusion

An accurate preoperative diagnosis of this unconventional tumour is difficult and technically demanding due to low specificity and sensitivity of the various preoperative diagnostic tools. Hence, histopathology which includes careful grossing, extensive sampling, detailed microscopic examination by experienced histopathologists and immunohistochemistry is the gold standard for diagnosis and remains the mainstay for defining the treatment course and prognosis. Teratomas are common but a suspicion for malignant transformation although very rare should always be kept in mind while dealing with these patients.

#### 5. Source of Funding

None.

#### 6. Conflicts of Interest

There are no conflicts of interest.

#### References

- Makani S, Kim W, Gaba AR. Struma ovarii with a focus of papillary thyroid cancer: a case report and review of literature. *Gynecol Oncol.* 2004;94(3):835–9.
- Hindshaw HD, Smith AL, Desouki MM, Olawaiye AB. Malignant transformation of a mature cystic ovarian teratoma into thyroid carcinoma, mucinous adenocarcinoma, and strumal carcinoid: a case report and literature review. *Case Rep Obstet Gynecol.* 2012;2012:269489. doi:10.1155/2012/269489.
- Hackethal A, Brueggmann D, Bohlmann MK, Franke FE, Tinneberg HR, Munstedt K. Squamous-cell carcinoma in mature cystic teratoma of the ovary: systematic review and analysis of published data. *Lancet Oncol.* 2008;9(12):1173–80.
- Kim SM, Choi HS, Byun JS, Kim YH, Kim KS, Rim SY, et al. Mucinous adenocarcinoma and strumal carcinoid tumor arising in one mature cystic teratoma of the ovary with synchronous cervical cancer. *J Obstet Gynaecol Res.* 2003;29(1):28–32.
- Rathore R, Sharma S, Agarwal S. Malignant transformation in mature cystic teratoma of the ovary: a retrospective study of eight cases and review of literature. *Prz Menopauzalny.* 2008;17(2):63–8.
- Lao M, Koike J, Chauhan S, Schiano M, Plata M. Struma ovarii with a focus of follicular variant of papillary thyroid cancer: a case report. *W V Med J.* 2008;104(4):12–4.
- Lenicek T, Tomas D, Solijacic-Vranes H, Kraljevic Z, Klaric P, Kos M, et al. strumal carcinoid of the ovary: report of two cases. *Acta Clin Croat.* 2012;51(4):649–53.
- Yamasaki T, Yagihashi Y, Shirahase T, Hashimura T, Watanabe C. Primary Carcinoid tumor arising in a retroperitoneal mature teratoma in an adult. *Int J Urol.* 2004;11(10):912–5.

9. Ueda G, Fujita M, Ogawa H, Swada M, Inoue M, Tanizawa O. Adenocarcinoma in a benign cystic teratoma of the ovary: report of a case with a long survival period. *Gynecol Oncol.* 1993;48(2):259–63.
10. Roy S, Mukhopadhyay S, Gupta M, Chandramohan A. Mature cystic Teratoma with Co-existent Mucinous Cystadenocarcinoma in the same ovary- A diagnostic dilemma. *J Clin Diagn Res.* 2016;10(12):11–3.

**Gunmala Bhatnagar**, Senior Consultant, Histopathology and Cytopathology

**Dipti Kalita**, Senior Consultant, Histopathology and Cytopathology

### Author biography

**Ruchi Rastogi**, Consultant Histopathology and Cytopathology

**Cite this article:** Rastogi R, Bhatnagar G, Kalita D. A curious case of benign ovarian teratoma with multiple malignant transformations: A histopathologists quagmire. *Indian J Pathol Oncol* 2023;10(4):406-409.