



## Case Report

# Plexiform fibrohistiocytic tumor of elbow: A rare case report

Syeda Iqra Usman<sup>1\*</sup>, Avadh Vihari Lal Sharma<sup>1</sup>, Veena Maheshwari<sup>1</sup>,  
Murad Ahmad<sup>1</sup>, Zeeshan Nahid<sup>1</sup>

<sup>1</sup>Dept. of Pathology, Jawaharlal Nehru Medical College, AMU, Aligarh, Uttar Pradesh, India



### ARTICLE INFO

#### Article history:

Received 22-09-2023

Accepted 07-10-2023

Available online 11-12-2023

#### Keywords:

Dermal or subcutaneous mass  
Plexiform fibrohistiocytic tumor  
Histiocyte  
Spindle cell

### ABSTRACT

Plexiform fibrohistiocytic tumor is a very rare tumor of soft tissue that affects usually adolescents and children. On histopathological examination it shows multiple small nodules or fascicles that are arranged in plexiform pattern, hence its name. Here we are presenting a case of occurrence of PFT in bilateral elbows. Patient presented with gradually increasing in size and painless swellings for 7 years. Excision was done and on the basis of histopathological and immunohistochemical examination diagnosis of PFT was reached.

This is an Open Access (OA) journal, and articles are distributed under the terms of the [Creative Commons Attribution-NonCommercial-ShareAlike 4.0 License](https://creativecommons.org/licenses/by-nc-sa/4.0/), which allows others to remix, tweak, and build upon the work non-commercially, as long as appropriate credit is given and the new creations are licensed under the identical terms.

For reprints contact: [reprint@ipinnovative.com](mailto:reprint@ipinnovative.com)

## 1. Introduction

Plexiform fibrohistiocytic tumor is a vary rare tumor of soft tissue that affects usually adolescents and children. It's main site of occurrence is upper extremities.<sup>1</sup> Fingers, wrist and hand are commonly affected. It presents as a slow growing painless mass involving subcutaneous adipose tissue with dermal or skeletal muscle involvement or both.<sup>2</sup> It predominantly affects females with no racial predominance.<sup>3</sup>

## 2. Case Report

A 25 years old male patient presented to plastic surgery OPD with complaints of swelling in bilateral elbow region for 7 years. Swellings were gradually increasing in size, painless with no history of discharge or associated symptoms. There was no complaint in hindrance of movement of elbow. No history of fever or trauma was present. On clinical examination swellings were 5x3cm in right elbow and 3x2 cm in left elbow. There

was no tenderness. Swellings were mobile and firm in consistency. Both the swellings were excised and sent for histopathological examination with neurofibroma as the clinical provisional diagnosis.

On gross examination two partially skin covered, creamish white firm globular tissue pieces, each measuring 5.3x5.0x2.0 cm and 2.5x1.5x0.5 cm were noted.(Figure 1) The specimens were photographed and cut surface showed multiple nodules and areas of haemorrhage, representative sections taken from all the specimens and examined.

On microscopic examination of H and E stained sections showed overlying epidermis was unremarkable. Deep dermis shows multiple nodules of fibrohistiocytic cells separated by thin fibrous septa.(Figure 2) There was dense lymphocytic infiltrate in the septa. Nodules and clusters were in a plexiform arrangement with numerous prominent dilated vessels. Mitotic activity was absent.

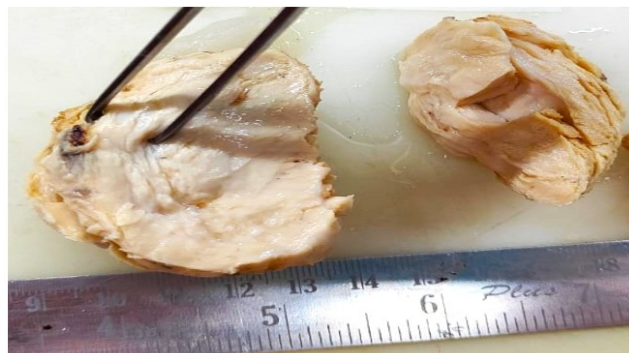
Immunohistochemistry was done and tumor cells showed diffuse positivity for CD 34 while they were negative for S100.(Figure 3)

On the basis of clinical history, gross, microscopy and immunostains, we made the final diagnosis of plexiform

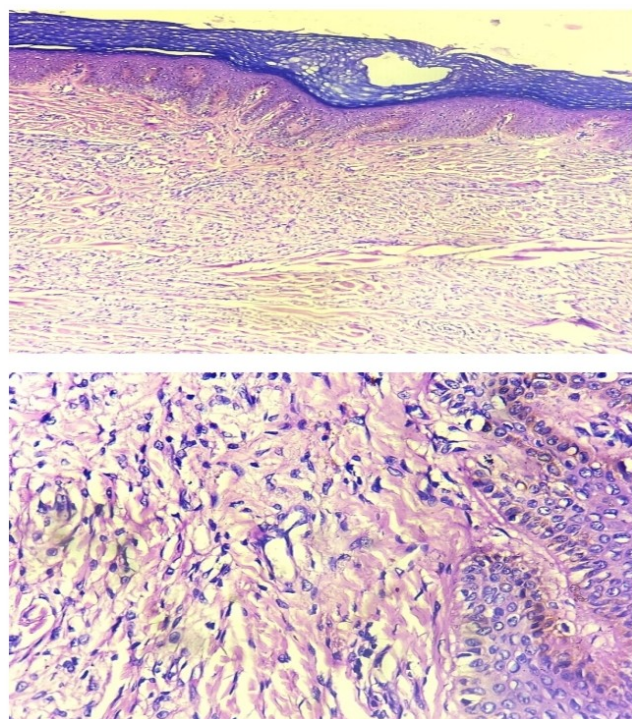
\* Corresponding author.

E-mail address: [s.iqra.u@gmail.com](mailto:s.iqra.u@gmail.com) (S. I. Usman).

fibrohistiocytic tumour.



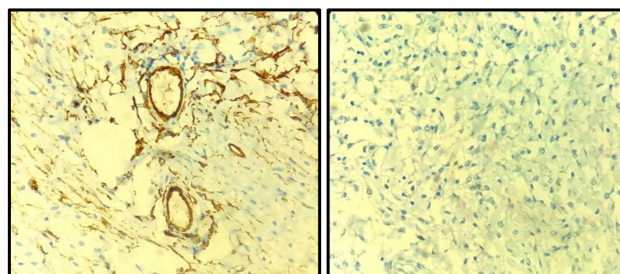
**Figure 1:** 5.3x5x2 cm, poorly circumscribed, globular, firm, creamish white. On cut section multiple nodules are seen



**Figure 2:** Normal overlying epidermis, deep dermis shows multiple nodules arranged in plexiform pattern of fibrohistiocytic cells separated by thin fibrous septa. Mitotic activity is absent

### 3. Discussion

Plexiform Fibrohistiocytic tumor was first described in 1988 by Enzinger et al. in a series of 65 cases demonstrating tumors having features of both a fibrous histiocytoma and fibromatosis.<sup>4</sup> It is a rare mesenchymal tumor of low to intermediate malignant potential that can be misdiagnosed easily as sebaceous/epidermal cyst on clinical



**Figure 3:** Immunohistochemistry of CD34 showed patchy positivity in tumor cells and S100 was negative

and histological basis.<sup>5</sup>

On histopathological examination it shows multiple small nodules or fascicles that are arranged in plexiform pattern, hence its name.<sup>3</sup> Major three histopathological patterns are fibrohistiocytic type that contains clusters of mononuclear histiocyte-like cells and multinucleated giant cells in a plexiform arrangement, fibroblastic type that shows elongated clusters and short fascicles of spindle fibroblast-like cells and a third that shows mixed pattern.<sup>6,7</sup> Differential diagnoses of PFT chiefly include plexiform neurofibroma, plexiform schwannoma, cellular neurothekeoma, fibrous hamartoma of infancy, deep benign fibrous histiocytoma, dermatofibroma, benign and malignant soft tissue giant cell tumor, and myofibromatosis.<sup>8</sup> In our case main differentiation was to be made from neurofibroma which was the clinical provisional diagnosis. Immunohistochemical stains are useful for ruling the differential diagnosis. Negative S100 protein stain helps to differentiate PFT from plexiform neurofibroma, plexiform schwannoma, and cellular neurothekeoma.<sup>4</sup> Treatment mainly relies on wide local excision with recurrence seen in 20-30% cases with very rare chance of nodal or distant metastasis.<sup>9</sup> In our case also mainstay of treatment was excision and patient is doing well on follow up.

### 4. Conclusion

Plexiform fibrohistiocytic tumor is a very rare occurrence. It affects predominantly females in their second or third decade. But we have presented here a male patient with bilateral occurrence of PFT which is even more rare finding. Since this tumor has many differentials both on clinical and histological grounds so excision with immunohistochemical examination should always be performed to avoid misdiagnosis.

### 5. Source of Funding

None.

## 6. Conflict of Interest

None.

## References

1. Naoum C, Trennheuser L, Krahl D, Toberer F. Plexiformer fibrohistiozytärer Tumor [Plexiform fibrohistiocytic tumor]. *Dermatologie (Heidelb)*. 2023;74(6):453–6.
2. Remstein ED, Arndt CA, Nascimento AG. Plexiform fibrohistiocytic tumor: clinicopathologic analysis of 22 cases. *Am J Surg Pathol*. 1999;23(6):662–70.
3. Taher A, Pushpanathan C. Plexiform fibrohistiocytic tumor: a brief review. *Arch Pathol Lab Med*. 2007;131(7):1135–8.
4. Enziger FM, Zhang RY. Plexiform fibrohistiocytic tumor presenting in children and young adults: an analysis of 65 cases. *Am J Surg Pathol*. 1988;12(11):818–26.
5. Thirumala S, Rhyne CD, Bodhireddy S. Plexiform fibrohistiocytic tumor. *Indian J Pathol Microbiol*. 2008;51(2):245–6.
6. Jafarian F, Mccuaig C, Kokta V, Hatami A, Savard P. Plexiform fibrohistiocytic tumor in three children. *Pediatric Dermatol*. 2006;23(1):7–12.
7. Bridge JA, Hogendoorn P, Mertens F. World Health Organisation Classification of Tumours. In: Pathology and Genetics Tumours of Soft Tissue and Bone. Lyon: IARC; 2013.
8. Zelger B, Weinlich G, Steiner H, Zelger BG, Egarter VE. Dermal and Subcutaneous Variants of Plexiform Fibrohistiocytic Tumor. *Am J Surg Pathol*. 1997;21(2):235–41.
9. Brahim BE, Khayat O, Labenne N, Chadli-Debbiche A, Krichen H, Romdhane BK, et al. Tumeur fibrohistiocytaire plexiforme: lesion a la limite de la malignite. *Tunis Med*. 2003;81(9):751–4.

## Author biography

**Syeda Iqra Usman**, Junior Resident  <https://orcid.org/0000-0003-2978-880X>

**Avadh Vihari Lal Sharma**, Junior Resident

**Veena Maheshwari**, Professor

**Murad Ahmad**, Assistant Professor

**Zeeshan Nahid**, Senior Resident

**Cite this article:** Usman SI, Sharma AVL, Maheshwari V, Ahmad M, Nahid Z. Plexiform fibrohistiocytic tumor of elbow: A rare case report. *Indian J Pathol Oncol* 2023;10(4):401-403.