



## Original Research Article

## Concordance between core needle biopsy and surgical excision specimen in the diagnosis of malignancy and benignity for patients with breast tumours

Mbessoh Kengne Ulrich Igor<sup>1\*</sup>, Balde Salif<sup>1</sup>, Ndiaye Mamadou<sup>1</sup>, Sow Amadou Amadi<sup>1</sup>, Ka Sidy<sup>1</sup>, Dem Ahmadou<sup>1</sup>

<sup>1</sup>Dept. of Oncology, Faculty of Medicine, Pharmacy, Odontostomatology of Cheikh Anta Diop University and Dalal Jamm University Hospital, Dakar, Senegal



## ARTICLE INFO

## Article history:

Received 18-10-2023

Accepted 13-11-2023

Available online 11-12-2023

## Keywords:

Breast tumors

Breast malignancy

Concordance

Needle biopsy

Surgical specimen

## ABSTRACT

**Background:** Core Needle Biopsy (CNB) has been widely used as a diagnostic tool for breast tumors. However, this technique involves tissue sampling as opposed to complete surgical lesion excision, introducing the possibility of underestimation of disease. The purpose of this study was to assess the reliability of CNB in breast tumors.

**Materials and Methods:** This was a retrospective cross-sectional study from January 2023 to July 2023. All included patients underwent Core Needle Biopsy (CNB) and subsequent Surgical Excision (SE) of a breast tumor.

**Results:** One hundred fifty patients were assessed. All patients were female. The median age for malignancies was 45 years and 31 years for benign tumors. Concordance regarding the tumor type was globally moderate ( $k=0.67$ ;  $p<0,001$ ) with a rate of 97.6% for CNB-diagnosed malignant tumors and 62.5% for CNB-diagnosed benign tumors. Concordance for histological types was perfect for CNB-diagnosed ILC (rate= 100%;  $k=1$ ;  $p<0,001$ ) and almost perfect for IDC (rate= 96.7%;  $k=0.94$ ;  $p<0,001$ ).

**Conclusion:** The concordance between Core Needle Biopsy (CNB) and surgical excision specimen in the diagnosis of malignancy and benignity of breast tumors is almost perfect for CNB-diagnosed malignancies and moderate for benign tumors.

This is an Open Access (OA) journal, and articles are distributed under the terms of the [Creative Commons Attribution-NonCommercial-ShareAlike 4.0 License](https://creativecommons.org/licenses/by-nc-sa/4.0/), which allows others to remix, tweak, and build upon the work non-commercially, as long as appropriate credit is given and the new creations are licensed under the identical terms.

For reprints contact: [reprint@ipinnovative.com](mailto:reprint@ipinnovative.com)

### 1. Introduction

Breast lesions constitute a heterogeneous group of diseases, with aetiologies ranging from inflammatory, benign tumors, to malignancies.<sup>1</sup> Although a lot of studies have been conducted on breast malignancies, the benign breast diseases have been somewhat neglected. In addition, a breast lump is a source of great anxiety due to the fear of malignancy.<sup>1</sup> Core needle biopsy (CNB) has been widely used as a diagnostic tool for breast lesions to provide information not only on the histological diagnosis but also on various predictive factors because

such information is very important when deciding the therapeutic strategy.<sup>2,3</sup> However, this technique involves tissue sampling as opposed to complete surgical lesion excision, introducing the possibility of underestimation of disease.<sup>(3,4)</sup> Thereby, it sometimes happens in oncological daily practice that breast lesions diagnosed as benign on CNB-histological examination appear to be malignancies at surgical excision (SE) and vice versa.<sup>4</sup> This underestimation has a remarkable impact on the management and overall prognosis of the patient. The purpose of this study was to assess the reliability of CNB in breast tumors by analyzing concordance between CNB and SE specimen in the diagnosis of malignancy and benignity of those lesions.

\* Corresponding author.

E-mail address: [mbessohulrich@yahoo.com](mailto:mbessohulrich@yahoo.com) (M. K. U. Igor).

## 2. Materials and Methods

### 2.1. Study design

From January 2023 to July 2023, we retrospectively collected data from patients affected by breast tumor presenting to the surgical oncology unit of the Dalal Jamm University Hospital. In that retrospective cross-sectional study, all patients underwent core needle biopsy (CNB) and subsequent surgical excision (SE). The local institutional review board approved this retrospective analysis, which waived the requirement to obtain written informed consent from patients.

### 2.2. Inclusion criteria

The inclusion criteria for the study were histological diagnosis of Breast tumor (benign or malignant) on 14 Gauge (14-G) CNB, and available complete histological reports of CNB and SES. Patients who received primary chemotherapy were also included, due to its no influence on the histological type of the tumor.

### 2.3. Sampling procedure

Percutaneous CNB were performed under local anesthesia with a 14-gauge semi-automated biopsy device with a 10 cm long needle. An average of 4 core samples per lesion (range 3 – 6) were obtained. In cases of both tumor size less than 3 × 3 cm long or early inflammatory swelling, an ultrasonography guidance was used. The specimens were fixed in 10% formalin for 24h.

### 2.4. Data collection

Data were collected from medical records of patients. Variables of interest were patients age and gender; administration of primary chemotherapy, nature (benign or malignant) of the tumor and histological type in both CNB and surgical excision specimen (SES).

### 2.5. Statistical analysis

All statistical tests were carried out using the SPSS statistical software package version 25.0 (Statistical Package for Social Sciences). Age of patients was described by median, interquartile range and age groups. Gender and other categorical variables were presented by effectives and percentages in frequency tables. The concordance or discordance between core biopsy and surgical specimen was analyzed using Cohen's kappa (k) statistics. Cohen's kappa coefficient value must be interpreted as follows: A k value of less than zero is considered poor, 0–0.20 slight, 0.21–0.40 fair, 0.41–0.60 moderate, 0.61–0.80 substantial and 0.81–1.00 almost perfect agreement.<sup>5</sup> The relation between categorical variables was tested using Chi-2 and Fischer Exact tests and a p-value less than 0.05 was

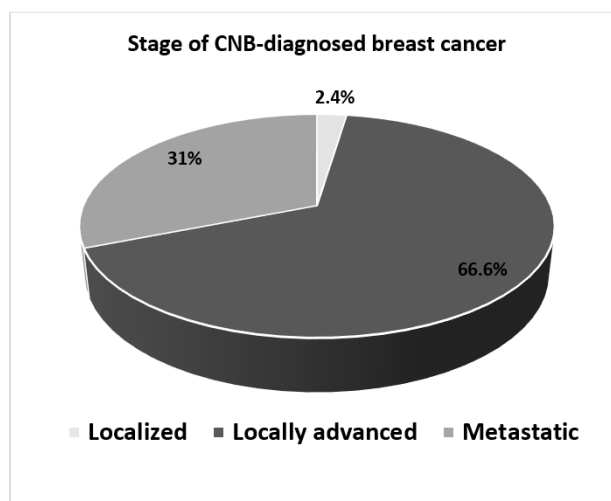
considered as statistically significant.

## 3. Results

One hundred fifty patients with a breast tumor (both benign and malignant) diagnosed following core needle biopsy and surgical excision were assessed. All patients were female. The median age for malignant tumors was 45 years and 59.1% were under 50 years old. For benign tumors, the median age was 31 years and 50% were under 30 years old (Table 1).

With CNB, 84% of breast tumors was diagnosed as malignancies while this rate was upgraded to 88% after SES histological examination. Invasive ductal carcinoma (IDC), invasive lobular carcinoma (ILC) and mucinous carcinoma (MC) were the major histological types with 72.7%, 4.5% and 2.3% respectively, while fibroadenoma (FA), fibrocystic changes (FC) and benign phyllodes tumor (BPT) were the major benign tumors with 66.6%, 16.7% and 16.7% respectively (Table 2).

The majority of patients presented with locally advanced stage breast cancer (66.6%) or metastatic disease (31%) (Figure 1).



**Figure 1:** Patients rate who received a neoadjuvant chemotherapy

After breast neoplasms diagnosed by CNB, 79% of patients received preoperative chemotherapy, among which all patients with stage 3 and stage 4 disease and 22.2% of patients with stage 2 disease (Figure 2).

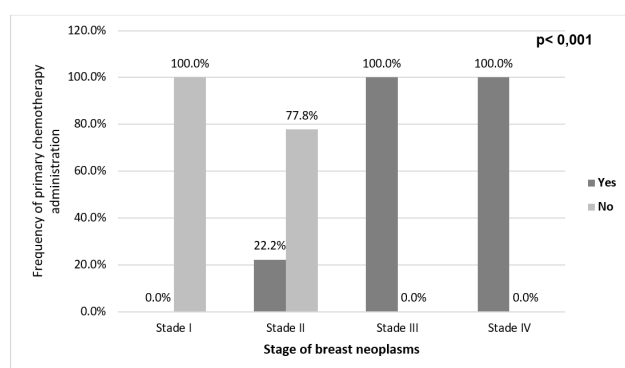
Concordance regarding the tumor type was globally substantial ( $k=0.67$ ;  $p<0.001$ ) with a rate of 97.6% for CNB-diagnosed malignant tumors and 62.5% for CNB-diagnosed benign tumors. Regarding females under 40 years of age, the concordance was almost perfect ( $k=0.86$ ;  $p<0.001$ ) with a rate of 100% for CNB-diagnosed malignant tumors and 80% for CNB-diagnosed benign tumors. Nevertheless, for females over 40 years of age the

**Table 1:** Patients features

Age groups	Malignant tumor	Benign tumor	Total
<b>Age groups</b>			
[18 – 30]	9 (6.8%)	9 (50%)	18 (12%)
[30 – 40]	36 (27.3%)	3 (16.7%)	39 (26%)
[40 – 50]	33 (25%)	0 (0%)	33 (22%)
[50 – 60]	30 (22.7%)	6 (33.3%)	36 (24%)
[60 – 70]	6 (4.5%)	0 (0%)	6 (4%)
[70 – 80]	18 (13.6%)	0 (50%)	18 (12%)
<b>Total</b>	<b>132 (88%)</b>	<b>18 (12%)</b>	<b>150 (100%)</b>
<b>Age statistics</b>			
Median age	45	31	
Interquartile range	(37 – 54)	(19 – 51)	
Minimal age	21	18	
Maximal age	74	55	
<b>Gender</b>			
Female	132 (88%)	18 (12%)	150 (100%)
Male	0 (0)	0 (0)	

**Table 2:** Histopathological features of breast tumors

Histopathological features	Core needle biopsy N (%)	Surgical excision specimen N (%)
<b>Tumor type</b>		
Malignant tumor	126 (84.0)	132 (88.0)
Benign tumor	24 (16.0)	18 (12.0)
<b>Histological types for malignant tumors</b>		
Invasive ductal carcinoma (IDC)	117 (92.9)	96 (72.7)
Invasive lobular carcinoma (ILC)	6 (4.8)	6 (4.5)
Mucinous carcinoma (MC)	3 (2.4)	3 (2.3)
Fibrosis (after chemotherapy)	0 (0.0)	27 (20.5)
<b>Histological types for benign tumors</b>		
Fibroadenoma (FA)	9 (37.5)	12 (66.6)
Fibrocystic changes (FC)	6 (25.0)	3 (16.7)
Benign phyllodes tumor (BPT)	3 (12.5)	3 (16.7)
Conjunctival epithelial hyperplasia (CEH)	3 (12.5)	0 (0.0)
Granulation tissue (GT)	3 (12.5)	0 (0.0)

**Figure 2:** Administration of preoperative chemotherapy according to the stage of malignant breast tumor

concordance was fair ( $k=0.35$ ;  $p=0.011$ ) with a rate of 66.7% for CNB-diagnosed benign tumors (Table 3).

Concordance assessment for histological types (Table 4) shows a perfect concordance for CNB-diagnosed ILC (rate=100%;  $k=1$ ;  $p<0.001$ ), an almost perfect concordance for IDC (rate=96.7%;  $k=0.94$ ;  $p<0.001$ ), a substantial concordance for FA (rate=66.7%;  $k=0.79$ ;  $p<0.001$ ) as well as for FC (rate=50%;  $k=0.66$ ;  $p<0.001$ ).

The comparison of histological type of breast tumors between CNB and SES (Table 5) shows that 3.3% of CNB-diagnosed IDC were FA, 50% of CNB-diagnosed FC were IDC, 100% of CNB-diagnosed GT were IDC, 33.3% of CNB-diagnosed FA were MC and 100% of CNB-diagnosed MC were IDC.

#### 4. Discussion

Breast lesions constitute a heterogeneous group of diseases, with etiologies ranging from inflammatory, benign lesions, to malignancies.<sup>1</sup> A lot of studies have been conducted on breast malignancies while benign breast diseases have

**Table 3:** Concordance analysis table for nature of tumor

Core needle biopsy	Surgical excision specimen		Kappa Value	P value
	Concordance rate	Discordance rate		
<b>All patients</b>				
Malignant tumor	97.6%	2.4%	0.67	<0.001
Benign tumor	62.5%	37.5%	0.67	<0.001
<b>Females &lt; 40 ans</b>				
Malignant tumor	100%	0%	0.86	<0.001
Benign tumor	80%	20%	0.86	<0.001
<b>Females ≥ 40 ans</b>				
Malignant tumor	96.4%	3.6%	0.35	0.011
Benign tumor	66.7%	33.3%	0.35	0.011

**Table 4:** Concordance analysis table for Histological types

Core needle biopsy	Surgical excision specimen		Kappa Value	P Value
	Concordance rate	Discordance rate		
Invasive lobular carcinoma	100%	0%	1	<0.001
Invasive ductal carcinoma	96.7%	3.3%	0.94	<0.001
Fibroadenoma	66.7%	33.3%	0.79	<0.001
Fibrocystic changes	50%	50%	0.66	<0.001
Conjunctival epithelial Hyperplasia	0%	100%	-	-
Benign Phyllods tumor	0%	100%	-	-
Granulation tissue	0%	100%	-	-
Mucinous carcinoma	0%	100%	-	-

**Table 5:** Comparison of histological type in CNB and surgical excision

Core Needle Biopsy	Surgical Excision Specimen					
	IDC	ILC	FC	BPT	FA	MC
IDC	96.7%	0	0	0	3.3%	0
ILC	0	100%	0	0	0	0
FC	50%	0	50%	0	0	0
CEH	0	0	0	100%	0	0
BPT	0	0	0	0	100%	0
GT	100%	0	0	0	0	0
FA	0	0	0	0	66.7%	33.3%
MC	100%	0	0	0	0	0

been somewhat neglected.<sup>1</sup> The purpose of this study was to assess the reliability of CNB in breast tumors by analyzing concordance between CNB and SE specimen in the diagnosis of malignancy and benignity of those lesions.

All the patients in this study were females. This finding is in agreement with most studies available in the recent literature, which reveal that lesions of the breast are predominantly confined to females.<sup>1,6-9</sup> In males, the breast is a rudimentary structure, relatively insensitive to endocrine influences. This may be the reason for the strong affinity between breast lesions and females.<sup>1</sup> The peak incidence age range for breast benign tumors in various African studies is the second and third decade with most patients aged under 30 years old.<sup>7,9,10</sup> Those reports are consistent with our findings. Indeed, in this study, the median age was 31 years and 50% were under 30 years old. Breast cancer patients in black African populations present at a relatively

younger age compared to white-skinned populations.<sup>11</sup> In this study as well as other sub-Saharan Africa series, the mean age of breast cancer is around 45 years.<sup>6,11,12</sup> Yet, In white-skinned populations, this age is around 52 years old.<sup>8,13,14</sup> This finding highlights an interracial difference in populations at risk for breast cancer.

The incidence of benign breast diseases (BBDs) is far more common than malignancies and also the most common cause of breast problems in females.<sup>1</sup> Uwaezuoke et al reported in Nigeria that on out of 334 histopathologically diagnosed breast lesions, 228 (68.3%) were benign in nature and the ratio of benign to malignant lesions was 2.2:1.<sup>7</sup> However, in our study, malignancies were far more common (88%) than benign tumors. This may be due to the fact that the study was conducted in a surgical oncology department.

After CNB and surgical excision, fibroadenoma was the most common BBD in this study, accounting for

67% of all the cases. Our finding was in agreement with most of the studies in the available literature on benign breast lumps.<sup>1,7,9,10</sup> Regarding malignancies, after final diagnosis by surgical excision, invasive ductal carcinoma was the most common breast cancer followed by invasive lobular carcinoma, accounting for 72.7% and 4.5% of all cases respectively. Note that 20.5% of CNB-diagnosed invasive ductal carcinoma which received neoadjuvant chemotherapy have presented fibrosis after surgical excision. These findings are concordant with numerous studies in the literature.<sup>2,6,8,12,13,15</sup>

In low- to middle-income countries (LMIC), 50%-70% of patients present with advanced-stage disease, contributing to high mortality rates.<sup>11</sup> Publications on breast cancer in Africa start by describing a large number of patients presenting with advanced disease.<sup>16</sup> We found in this study that the majority of patients with CNB-diagnosed malignancy presented with locally advanced stage breast cancer (66.6%) and metastatic disease (31%). Vanderpuye et al reported that 89.6% and 72.8% of breast patients in Kenya and Nigeria respectively presenting with advanced stage disease.<sup>16</sup> Ranaivomanana et al in Madagascar reported that 55% of breast neoplasms were diagnosed at stage 3 and 32% at stage 4.<sup>14</sup> In our cohort, 79% of patients with CNB-diagnosed malignancy received preoperative chemotherapy and all patients with stage 3 and stage 4 advanced-disease received neoadjuvant chemotherapy. Similarly, Vanderpuye et al reported that for locally advanced breast cancer, 95% of institutions implemented neoadjuvant chemotherapy.<sup>11</sup>

Core needle biopsy (CNB) specimens provides adequately sized samples permitting a histological diagnosis.<sup>13</sup> The diagnoses obtained from the pathologic examination of CNB and surgically excised specimens have been shown to be similar, with a sensitivity of 90% to 100% for the detection of breast cancer in several studies.<sup>2,13</sup> This observation is consistent with that of our study in which the concordance rate between CNB and SES was of 97.6% for breast cancers. Nevertheless, this concordance was moderate for CNB-diagnosed benign tumors with a rate of 62.5%, revealing an upgrade rate of 37.5% to malignancy after surgical excision. This upgrade rate is 8.2 to 25.6% in the literature depending on the studies.<sup>4,17,18</sup> This difference may be explained both by inter-observer variability and the quality level of materials used for histological diagnosis in this low-income country.

For breast neoplasms, the histological type on CNB was almost perfectly correlated with that of SES. The rates were 100% and 96.7% for invasive lobular carcinoma and invasive ductal carcinoma respectively. Ricci et al. as well as Usami et al found similar results in their studies.<sup>2,13</sup> Studies on concordance between CNB and SES for patients with breast lumps are rare in the available literature. Choi et al. made a comparative study of histological features between CNB and SES on 90 cases of benign phyllodes tumor in which they demonstrated that the concordant rate

of diagnosis between CNB and surgical excision was about 60%.<sup>19</sup> In this study, we found no concordance probably because the number of phyllodes tumor cases was very limited in our cohort. Additionally, a global comparison of histological type of breast tumors between CNB and SES in this study found that 3.3% of CNB-diagnosed IDC were FA at SES, 50% of CNB-diagnosed FC were IDC, 100% of CNB-diagnosed GT were IDC, 33.3% of CNB-diagnosed FA were MC and 100% of CNB-diagnosed MC were IDC.

## 5. Limitations

This study has few potential limitations. First, it was retrospective in design, and therapy or lack of therapy was not determined on a randomized basis. Next, any discordance between CNB and surgically resected specimens may be due to various factors, including tumor sampling, technical preparation, fixation time, or inter-observer variability.

## 6. Conclusion

The concordance between core needle biopsy (CNB) and surgical excision specimen in the diagnosis of malignancy and benignity of breast tumors is almost perfect for CNB-diagnosed malignancies and moderate for benign tumors. Nevertheless, physicians should be cautious about both a CNB-diagnosed benign tumor in women over 40 years and a histological diagnosis of fibrocystic mastopathy on core needle biopsy.

## 7. Funding Support

No specific funding was disclosed.

## 8. Conflict of Interest

Authors declared no conflict of interest in relation to this article.

## Acknowledgements

1. To consultant pathologists of the Anatomical pathology department of Dalal Jamm University Hospital, Dakar, Senegal.
2. To all residents in surgical oncology at the oncology department of Dalal Jamm University Hospital, Dakar, Senegal.
3. To the medical and nurse staff of the Oasis Clinic of Dakar, Senegal.

## References

1. Boral S, Jagtap SV. Clinicohistopathological study of benign breast lesions in surgically excised specimens in a tertiary care hospital. *J Cancer Res Ther.* 2023;19:116–20.

2. Usami S, Moriya T, Amari M, Suzuki A, Ishida T, Sasano H, et al. Reliability of Prognostic Factors in Breast Carcinoma Determined by Core Needle Biopsy. *Jpn J Clin Oncol*. 2007;37(4):250–5.
3. Ibrahim N, Bessissow A, Lalonde L, Mesurolle B, Trop I, Lisbona A, et al. Surgical outcome of biopsy-proven lobular neoplasia: is there any difference between lobular carcinoma in situ and atypical lobular hyperplasia? *AJR Am J Roentgenol*. 2012;198(2):288–91.
4. Cha E, Ambinder EB, Oluymi ET, Mullen LA, Panigrahi B, Rossi J, et al. High-risk lesions in the breast diagnosed by MRI-guided core biopsy: upgrade rates and features associated with malignancy. *Breast Cancer Res Treat*. 2022;196(3):517–25.
5. McHugh ML. Interrater reliability: the kappa statistic. *Biochem Med (Zagreb)*. 2012;22(3):276–82.
6. Engbang JPN, Essome H, Koh VM, Simo G, Essam JDS, Mouelle AS. Cancer du sein au Cameroun, profil histo-épidémiologique: à propos de 3044 cas. *Pan Afr Med J*. 2015;21:242.
7. Uwaezuoke SC, Udoye EP. Benign breast lesions in Bayelsa State, Niger Delta Nigeria: a 5 year multicentre histopathological audit. *Pan Afr Med J*. 2014;19:394.
8. Fouhi ME, Benider A, Gaëtan KZA, Mesfioui A. Profil épidémiologique et anatomopathologique du cancer de sein au CHU Ibn Rochd, Casablanca. *Pan Afr Med J*. 2020;37:41. doi:10.11604/pamj.2020.37.41.21336.
9. Kamate B, Traore CB, Diallo D, Foko I, Sangare F, Malle B, et al. Epidemiology and morphology of breast benign tumors in Mali: about 186 cases. *Mali Med*. 2008;23(3):36–9.
10. Gueye SMK, Gueye M, Coulibaly MT, Coulibaly MT, Mahtouk D, Moreau JC. Tumeurs bénignes du sein à l'unité de sénologie du Centre Hospitalier Universitaire Aristide Le Dantec de Dakar (Sénégal). *Pan Afr Med J*. 2017;27:251.
11. Vanderpuye V, Dadzie MA, Huo D, Olopade OI. Assessment of Breast Cancer Management in Sub-Saharan Africa. *JCO Glob Oncol*. 2021;7:1593–1601.
12. Zingue S, Atenguena EO, Zingue LL, Tueche AB, Njamen D, Nkoum AB, et al. Epidemiological and clinical profile, and survival of patients followed for breast cancer between 2010 and 2015 at the Yaounde General Hospital, Cameroon. *Pan Afr Med J*. 2021;39:182.
13. Ricci MD, Filho C, Filho HRO, Filassi JR, Pinotti JA, Baracat EC, et al. Analysis of the concordance rates between core needle biopsy and surgical excision in patients with breast cancer. *Rev Assoc Med Bras (1992)*. 2012;58(5):532–6.
14. Ranaivomanana M, Hasiniatsy NRE, Rakotomahenina H, Rafaramino F. Aspects épidémiocliniques des cancers du sein au Service d'Oncologie de Fianarantsoa, Madagascar de 2011 à 2018. *Pan Afr Med J*. 2011;38:264.
15. Aka E, Horo A, Koffi A, Fanny M, Didi-Kouko C, Nda G. Management of breast cancer in Abidjan: A single center experience. *Gynécol Obstét Fertil Sérol*. 2021;49(9):684–90.
16. Vanderpuye V, Grover S, Poojaprabhakar HN, Simonds H, Olopade F. An update on the management of breast cancer in Africa. *Infect Agent Cancer*. 2017;12:13.
17. Michaels AY, Ginter PS, Dodelzon K, Naunheim MR, Abbey GN. High-Risk Lesions Detected by MRI-Guided Core Biopsy: Upgrade Rates at Surgical Excision and Implications for Management. *AJR Am J Roentgenol*. 2021;216(3):622–32.
18. Willers N, Neven P, Floris G, Colpaert C, Oldenburger E, Han S, et al. The Upgrade Risk of B3 Lesions to (Pre)Invasive Breast Cancer After Diagnosis on Core Needle or Vacuum Assisted Biopsy. A Belgian National Cohort Study. *Clin Breast Cancer*. 2023;23(4):273–80.
19. Choi J, Koo JS. Comparative study of histological features between core needle biopsy and surgical excision in phyllodes tumor. *Pathol Int*. 2012;62(2):120–6.

### Author biography

**Mbessoh Kengne Ulrich Igor**, Consultant

**Balde Salif**, Consultant

**Ndiaye Mamadou**, Consultant

**Sow Amadou Amadi**, Consultant

**Ka Sidy**, Professor

**Dem Ahmadou**, Professor

**Cite this article:** Igor MKU, Salif B, Mamadou N, Amadi SA, Sidy K, Ahmadou D. Concordance between core needle biopsy and surgical excision specimen in the diagnosis of malignancy and benignity for patients with breast tumours. *Indian J Pathol Oncol* 2023;10(4):376-381.