

Content available at: <https://www.ipinnovative.com/open-access-journals>

Indian Journal of Pathology and Oncology

Journal homepage: www.ijpo.co.in**Short Communication****Lichen planus pigmentosus (LPP) versus erythema dyschromicum perstans (ashy's dermatosis): A diagnostic dilemma!- Letter to editor**Ekta Mishra¹, Ajit Surya Mohapatra², Arti Nial², Shushruta Mohanty^{1,2,*}¹Dept of Skin & VD, M.K.C.G Medical College and Hospital, Brahmapur, Odisha, India²Dept. of Pathology, M.K.C.G Medical College and Hospital, Brahmapur, Odisha, India**ARTICLE INFO***Article history:*

Received 13-06-2023

Accepted 19-08-2023

Available online 27-09-2023

This is an Open Access (OA) journal, and articles are distributed under the terms of the [Creative Commons Attribution-NonCommercial-ShareAlike 4.0 License](https://creativecommons.org/licenses/by-nc-sa/4.0/), which allows others to remix, tweak, and build upon the work non-commercially, as long as appropriate credit is given and the new creations are licensed under the identical terms.

For reprints contact: reprint@ipinnovative.com

Lichen planus pigmentosus (LPP) is a rare variant of lichen planus that was first reported in India by Bhutani et al. in the year 1974.¹ He later renamed the term giving a distinct nomenclature to it. Commonly it has an actinic pattern of distribution that begins with appearance of brown to gray pigmented macules with ill-defined borders, initially over pre-auricular areas and forehead, which later coalesce to form hyperpigmented patches, occurring in darker skin individuals.² It occurs in middle aged individuals with few studies showing a greater incidence in females.³ It has an insidious onset and is characterized by persistent, asymptomatic or mildly pruritic slate gray pigmentation predominantly over the face and neck (Figure 1) followed by upper extremities and trunk. Commonly a diffuse pattern of pigmentation is encountered, while reticular, blotchy and perifollicular patterns have also been described.² The patches are mostly symmetrical in distribution although various other patterns such as linear,⁴ segmental,⁵ zosteriform⁶ and blaszkoid⁷ have being reported in various literature. The oral mucosa may rarely be involved and there is sparing of palms, soles and nails.⁸ Another important variant of LPP which is rare and needs a special mention is LPP inversus that was reported by Pock et al. in the year 2001,⁹ occurring commonly in photoprotected areas, mostly the flexures and

intertriginous areas. Unlike Lichen planus, in LPP there is no or occasional pruritus and Wickham's striae is absent.² Cases of LPP have been reported from various parts of the country India as well as seen in Japan, Korea, Middle East and Latin America.

Although the etiological factors of LPP still remains a debatable issue, a number of agents have been reported to act as predisposing factors. Its occurrence in photo exposed areas has pointed towards the possibility of sunlight as an etiologic agent.¹⁰ Other possible inciting agents include topical mustard oil containing allyl isothiocyanate and amla oil, a potential photosensitizer.¹¹ LPP is also thought to be a type IV hypersensitivity reaction to some unknown antigen with lichenoid reaction at dermoepidermal junction leading to melanin incontinence and superficial dermal pigmentation. T lymphocyte dysfunction have also been postulated in its etiopathogenesis.²

Histologically LPP shows varied histological features depending on the age of the lesion, with early lesions showing marked inflammation at the interface and older lesions showing less inflammation and prominent dermal pigmentation.¹¹ The findings include atrophic epidermis with apoptosis of keratinocytes, basal layer vacuolar degeneration and dermal pigment incontinence.³ The inflammatory phase is characterized by dense lichenoid (lymphohistiocytic) infiltrates with prominent basal cell vacuolar degeneration and some pigment incontinence. The

* Corresponding author.

E-mail address: sushruta.mohanty@gmail.com (S. Mohanty).

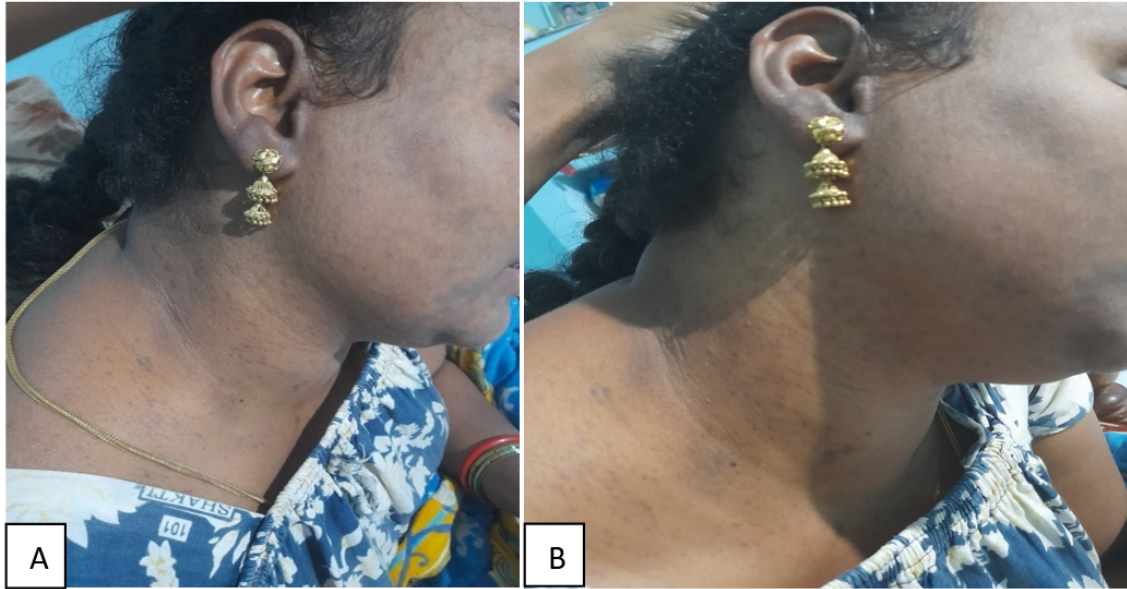

Fig. 1: Clinical Pic of patient (LPP)- Showing ill-deffined, discrete and confluent areas of slate gray pigmentation distributed over face and neck

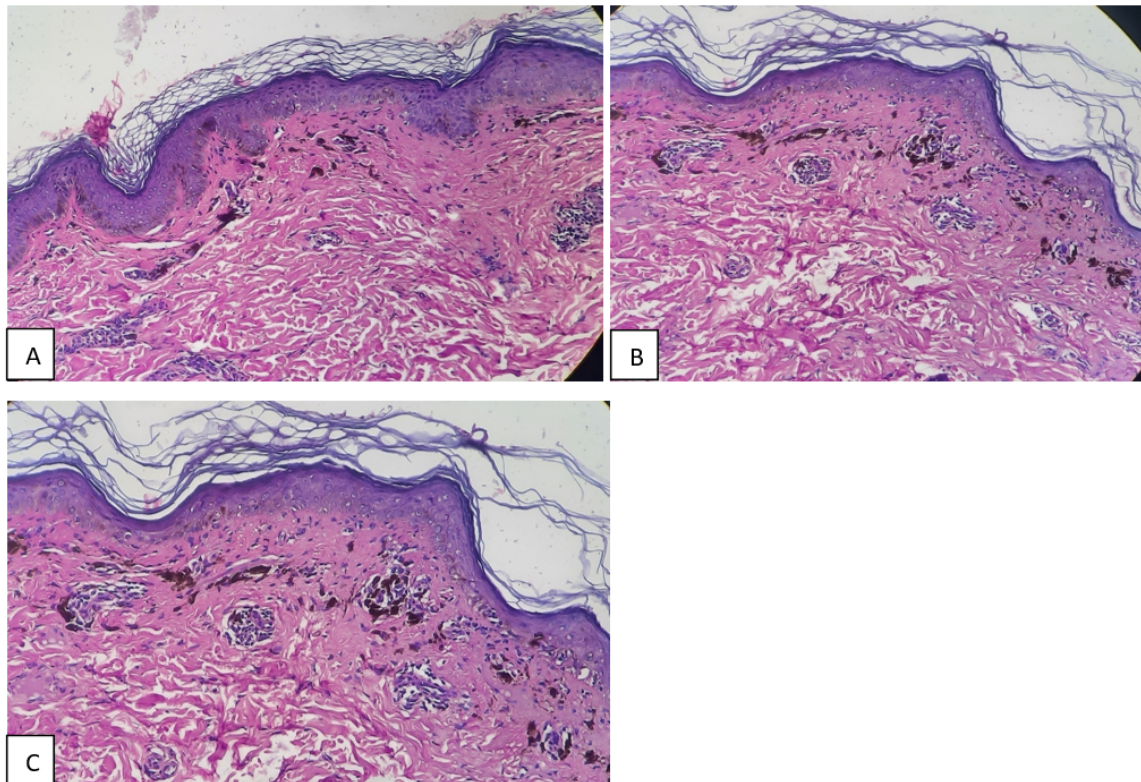


Fig. 2: A): Scanner view 40x; B, C): Low power view 100x; Shows Epidermis is atrophic with basket weave hyperkeratosis and dermis showing a minimal superficial perivascular lymphohistiocytic infiltrate and focal basal vacuolar degeneration with marked melanin incontinence (burnt out inflammation)- Histopathological findings in Lichen planus pigmentosus

second pattern (burnt out inflammation) shows upper dermal perivascular lymphohistiocytic infiltrate and minimal to absent basal cell vacuolar degeneration with significant pigment incontinence³ (Figure 2). Similar to Lichen planus, colloid bodies can be seen in LPP as well.³ The infiltrate is composed of CD8 T-lymphocytes predominantly.³ Immune deposits are more commonly seen in LP in comparison to LPP where it is seen in only 15% of cases. Occasionally DIF maybe positive with IgM, IgG, C3 and fibrinogen deposits in colloid bodies or basement membrane zone.^{2,3}

The closest differential diagnosis posing a diagnostic challenge for a dermatologist is Erythema dyschromicum perstans (EDP) or Ashy's dermatosis. It differs from LPP by extensive involvement over sunexposed as well as covered areas, greyish blue to brownish macules with erythematous, elevated borders in early inflammatory stages.¹² Histologically EDP shows basal cell vacuolar degeneration with dermal mononuclear infiltrate that is periadnexal in location and dermal pigment (melanin) deposition is in deeper dermis compared to superficial dermal deposition in LPP. Second closest differential is pigmented contact dermatitis / Riehl's melanosis, which has similar features as that of LPP both clinically and histopathologically. Clinically its characterized by hyperpigmentation of face and neck due to ingredients in cosmetic products.¹³ Histological features causing a diagnostic overlap with LPP includes interface dermatitis, lichenoid infiltrates and melanin incontinence.³ A definitive diagnosis however is established only after positive patch test identifying the allergen and by eliciting an adequate history of prior application of topical agents such as cosmetics and dyes.³ Other differentials include drug induced pigmentation, post inflammatory pigmentation, macular amyloidosis, frictional melanosis and idiopathic eruptive macular pigmentation.³

LPP has been reported in various literatures to be associated with disorders like scarring alopecia and circulating antinuclear antibodies,¹⁴ frontal fibrosing alopecia¹⁵, acrokeratosis of Bazex and head and neck carcinoma (paraneoplastic LPP),¹⁶ hepatitis C infection¹⁷ and nephrotic syndrome.¹⁸

The natural course of disease in LPP is variable with some cases showing spontaneous resolution while certain cases are refractory to treatment with persistence of pigmentation over years. Review of literature have suggested various treatment modalities for LPP. Use of vit A was recommended by Bhutani et al.¹⁹ while Al Mutairi and El Khalawany found tacrolimus ointment to be effective in 53.8% of patients.²⁰ The use of oral dapsone along with topical tacrolimus may halt the progression of pigmentation as suggested by Sehgal et al.⁹ Few cases also responded well low fluence Q switched Nd-YAG laser.²¹ An open label, non-randomized, prospective study by Muthu et al. showed improvement with oral isotretinoin at a dose of 20mg/day for 6 months.²² Other treatment

modalities include photoprotection, oral tranexamic acid (250mg/day for 4-6 months), topical and oral steroids, topical 5% azelaic acid, oral acitretin (25mg) and Narrow band ultraviolet B phototherapy.²³ The response rates showed moderate to good improvement in most of the studies.²³ The limitations of the studies include their small sample size, low levels of evidence and absence of specific assessment tools for evaluation of treatment outcomes.²³ In EDP, again topical tacrolimus and narrow band ultraviolet light have shown promising results whereas oral isotretinoin and dapsone showed recurrence and lasers have shown to be ineffective.²⁴ A case series by Aisleen et al. have reported resolution of lesions of EDP with a combination therapy of oral prednisolone and isotretinoin if initiated at early stage of the disease.²⁵ Availability of few studies and case series as well as lack of randomized clinical trials have accounted to absence of any standard therapeutic modality in its treatment.²⁵

1. Source of Funding

None.

2. Conflict of Interest

None.

References

- Bhutani LK, Bedi TR, Pandhi RK, Nayak NC. Lichen planus pigmentosus. *Dermatologica*. 1974;149(1):43–50.
- Kanwar AJ, Dogra S, Handa S, Parsad D, Radotra BD. A study of 124 Indian patients with lichen planus pigmentosus. *Clin Exp Dermatol*. 2003;28(5):481–5.
- Mathews I, Thappa DM, Singh N, Gochhait D. Lichen planus pigmentosus A short review. *Pigment Int*. 2016;3:5–10.
- Hong S, Shin JH, Kang HY. Two cases of lichen planus pigmentosus presenting with a linear pattern. *J Korean Med Sci*. 2004;19(1):152–4.
- Kumar YH, Babu AR. Segmental lichen planus pigmentosus: An unusual presentation. *Indian Dermatol Online J*. 2014;5(2):157–9.
- Cho S, Whang KK. Lichen planus pigmentosus presenting in zosteriform pattern. *J Dermatol*. 1997;24(3):193–7.
- Akarsu S, Ilknur T, Özer E, Fetil E. Lichen planus pigmentosus distributed along the lines of Blaschko. *Int J Dermatol*. 2013;52(2):253–4.
- Ghosh A, Coondoo A. Lichen planus Pigmentosus: The controversial consensus. *Indian J Dermatol*. 2016;61(5):482–6.
- Pock L, Jelínková L, Drlík L, Ahrhánová S, Vojtechovská S, Sezemská D, et al. Lichen planus pigmentosus-inversus. *J Eur Acad Dermatol Venereol*. 2001;15(5):452–4.
- Rieder E, Kaplan J, Kamino H, Sanchez M, Pomeranz MK. Lichen planus pigmentosus. *Dermatol Online J*. 2013;19(12):20713.
- Sehgal VN, Verma P, Bhattacharya SN, Sharma S, Rasool F. Lichen planus pigmentosus. *Skinmed*. 2013;11(2):96–103.
- Numata T, Harada K, Tsuboi R, Mitsuhashi Y. Erythema Dyschromicum Perstans: Identical to Ashy Dermatitis or not? *Case Rep Dermatol*. 2015;7(2):146–50.
- Tienthavorn T, Tresukosol P, Sudtikoonaseth P. Patch testing and histopathology in Thai patients with hyperpigmentation due to erythema dyschromicum perstans, lichen planus pigmentosus, and pigmented contact dermatitis. *Asian Pac J Allergy Immunol*. 2014;32(2):185–92.


14. Parodi G, Parodi A, Guarrera M, Cannata G, Piccardo G. Lichen pigmentosus with scarring alopecia and circulating antinuclear antibodies. *Int J Dermatol*. 1990;29(3):227–8.
15. Dlova NC. Frontal fibrosing alopecia and lichen planus pigmentosus: Is there a link? *Br J Dermatol*. 2013;168:439–42.
16. Sassolas B, Zagnoli A, Leroy JP, Guillet G. Lichen planus pigmentosus associated with acrokeratosis of Bazex. *Clin Exp Dermatol*. 1994;19(1):70–3.
17. Vachiramon V, Suchonwanit P, Thadanipon K. Bilateral linear Lichen planus pigmentosus associated with hepatitis C virus infection. *Case Rep Dermatol*. 2010;2(3):169–72.
18. Mancuso G, Berdondini RM. Coexistence of lichen planus pigmentosus and minimal change nephrotic syndrome. *Eur J Dermatol*. 2009;19(4):389–90.
19. Bhutani LK, George M, Bhate SM. Vitamin A in the treatment of lichen planus pigmentosus. *Br J Dermatol*. 1979;100(4):473–4.
20. Al-Mutairi N, El-Khalawany M. Clinicopathological characteristics of lichen planus pigmentosus and its response to tacrolimus ointment: An open label, non-randomized, prospective study. *J Eur Acad Dermatol Venereol*. 2010;24:535–40.
21. Han XD, Goh CL. A case of lichen planus pigmentosus that was recalcitrant to topical treatment responding to pigment laser treatment. *Dermatol Ther*. 2014;27(5):264–7.
22. Muthu SK, Narang T, Saikia UN, Kanwar AJ, Parsad D, Dogra S. Low-dose oral isotretinoin therapy in lichen planus pigmentosus: an open-label, non-randomized prospective pilot study. *Int J Dermatol*. 2016;55(9):1048–54.
23. Syder N, Sicco K, Gutierrez D. Updates In Therapeutics for Lichen Planus Pigmentosus. *J Drugs Dermatol*. 2022;21(3):324–30.
24. Leung N, Oliveira M, Selim MA, Mckinley-Grant L, Lesesky E. Erythema dyschromicum perstans: A case report and systematic review of histologic presentation and treatment. *Int J Dermatol*. 2018;27(4):216–22.
25. Diaz A, Gillihan R, Motaparthy K, Rees A. Combination therapy with prednisone and isotretinoin in early erythema dyschromicum perstans: A retrospective series. *JAAD Case Rep*. 2020;6(3):207–13.

Author biography

Ekta Mishra, Tutor, Skin & VD

Ajit Surya Mohapatra, Assistant Professor

Arti Nial, PG Student

Shushruta Mohanty, Assistant Professor  <https://orcid.org/0000-0002-3122-6892>

Cite this article: Mishra E, Mohapatra AS, Nial A, Mohanty S. Lichen planus pigmentosus (LPP) versus erythema dyschromicum perstans (ashy's dermatosis): A diagnostic dilemma!- Letter to editor. *Indian J Pathol Oncol* 2023;10(3):328-331.