



## Case Report

# A rare case report of familial multiple lipomatosis and its diagnostic approach with review of literatures

Kartavya Kumar Verma <sup>1,\*</sup>

<sup>1</sup>Dept. of Pathology and Lab Medicine, All India Institute of Medical Sciences, Raipur, Chhattisgarh, India



### ARTICLE INFO

#### Article history:

Received 08-04-2023

Accepted 15-06-2023

Available online 27-09-2023

#### Keywords:

Familial multiple lipomatosis

FNAC

Histopathology

Pathology

Diagnosis

### ABSTRACT

Lipoma is a well-known and most common soft tissue tumor. But multiple lipomatosis are rare. Also, syndromic associations were documented. Familial multiple lipomatosis (FML) is an autosomal dominant disorder. It presents as multiple lipomas in the body at specific sites. In presenting case 26-year-old patient complained of multiple swellings in his forearms, both thigh, and anterior abdominal wall for 5 years. A diagnosis of multiple lipomatosis is made by Fine needle aspiration cytology and confirmed by histopathological examination.

This is an Open Access (OA) journal, and articles are distributed under the terms of the [Creative Commons Attribution-NonCommercial-ShareAlike 4.0 License](https://creativecommons.org/licenses/by-nc-sa/4.0/), which allows others to remix, tweak, and build upon the work non-commercially, as long as appropriate credit is given and the new creations are licensed under the identical terms.

For reprints contact: [reprint@ipinnovative.com](mailto:reprint@ipinnovative.com)

## 1. Introduction

Lipoma is a solitary tumour but cases of multiple lipomatosis have been rarely reported. Lipomas are the commonest soft tissue benign tumours occurring generally between the age group of 40-60 years. In some cases, there can be multiple lipomas involving several members of a family or associated with other systemic manifestations as in some syndromes. Cases of iatrogenic lipomatosis have been reported only rarely.<sup>1,2</sup> It is sporadic or familial with a prevalence of 2.1 per 1000 individuals.<sup>3</sup>

## 2. Case Report

A 26 years old patient presented with gradually progressive swellings in his both forearms, left thigh, and anterior abdominal wall for 5 years. The patient gives a history of rapidly increasing the size of swellings after taking Ayurvedic medication for the swellings and a family history of lipomas is present. On general examination multiple swellings are seen in different body parts, the patient was

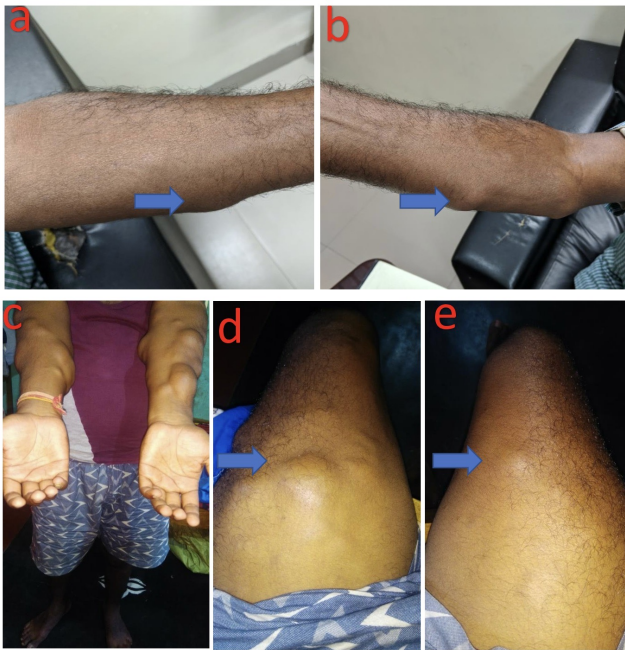
well oriented to time place and person, normotensive, pulse was normal, heart rate 80/min. On systemic examination cardiovascular system, respiratory system, and central nervous system are normal. On per abdominal examination, multiple anterior abdominal wall swellings are palpated largest measures 1x1 cm, painless, soft in consistency, movable not related to any skin changes at the site of the lesion. Swellings on both hands are larger than abdominal and thigh swellings (Figure 1 d, e). Largest measuring 6x3 cm on the dorsal aspect of the left forearm near the elbow joint, freely movable, painless, firm to soft, and not related to any skin changes at the site of the lesion (Figure 1 c). A mildly deranged lipid profile was observed. Familial history was also obtained which revealed that the same type of lesions was present in his father's forearm and thighs also (Figure 1 a, b). His elder brother also has similar complaints.

On fine needle aspiration cytology (FNAC), we found fat fragments have mature adipose tissue with clear cytoplasm and peripherally situated nuclei (Figure 3 a, b). A benign lipomatous lesion consistent with multiple lipomatosis is the impression in the cytological report.

Grossly multiple yellowish soft tissue pieces were received largest measuring 5 cm in size (Figure 2). On

\* Corresponding author.

E-mail address: [dr.kartavya123@gmail.com](mailto:dr.kartavya123@gmail.com) (K. K. Verma).

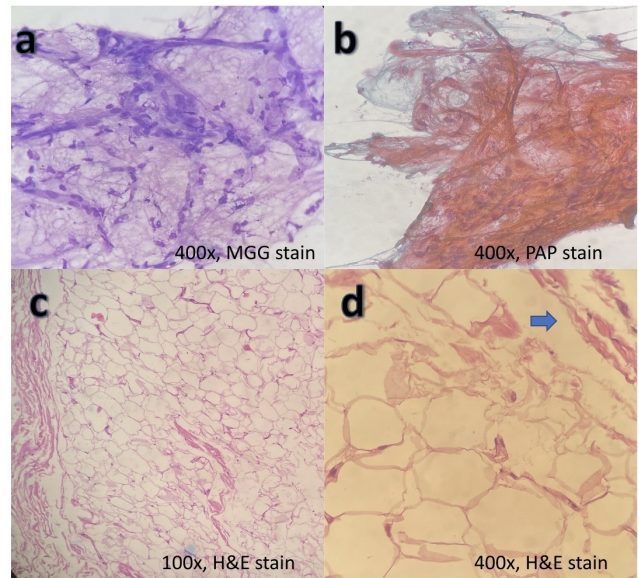


**Fig. 1:** a & b showing patient’s father lesion on bilateral forearms; (c, d & e) showing patient’s lesion predominantly in bilateral forearms with bilateral thigh

Microscopy with Hematoxylin & Eosin stain show a well-defined lesion comprised of lobules of mature adipocytes (Figure 3 c,d). There is no increase in vascularity and thick fibrous septa are present. No evidence of malignancy or cellular atypia was documented.



**Fig. 2:** Gross photograph of lipoma. Each lesion have its own fibrous capsule (marked by arrow) and cut surface is yellowish in colour



**Fig. 3:** Photomicrograph of Fine needle aspiration cytology (a & b) show benign adipose tissue with clear cytoplasm and peripherally shifted nuclei [x400, May Grunwald-Giemsa (MGG) & Papanicolaou (PAP) stain, respectively]; Photomicrograph of biopsy (c & d) show well-defined lesion comprised of lobules of mature adipocytes [x100 & x400, Hematoxylin & eosin stain, respectively]. Fibrous capsule present (marked by arrow).

### 3. Discussion

There were two lipomatosis described in literature one of them was Familial multiple lipomatosis (FML) and another was multiple symmetric lipomatosis (MSL). In 1970, Das Gupta.<sup>4</sup> divided benign fatty tumours into three categories: sporadic lipoma, FML, and MSL. FML is close to decrum’s disease and MSL is also known as Madelung disease. FML has lipomas with genetic history. On the other hand, MSL lacks genetic predisposition. Iatrogenic forms are also described in which the patient has a history of trauma at the lesion site.

In FML lipomas are predominantly confined to extremities and lacking in areas like the nape of the neck, and shoulder.<sup>5</sup> MSL is characterized by the collection of large non-encapsulated lipomas mainly located in the subcutaneous tissues of the cervical, deltoid, thoracic, abdominal and pelvic areas.<sup>6</sup> In presenting case, the lipomas are predominantly confined to the forearm, thigh and abdomen. Which favours the diagnosis towards FML over MSL.

The aetiology of this condition is unknown though some researchers have attributed it to mitochondrial disorders, alcohol consumption and abnormal liver functions. MSL is associated with alcoholism, while FML is not.<sup>5</sup> This condition is also found associated with idiopathic syndromes like Madelung’s, Cowden and Decum, or they can be familial also. Cowden syndromic lesions have more

changes to change into sarcomas.

Best of our knowledge, no definitive diagnostic modality to differentiate between FML and MSL were described till now.<sup>7</sup> Diagnostic is more oriented toward suspicion and clinical presentation with genetic history. Fine needle aspiration cytology is the preferable lesser invasive modality as compared to excision. Excision is only recommended when there are cosmetic challenges. Also when the sarcomatous transformation is suspected. Fine needle aspiration cytology (FNAC) gives a clue to its benign and malignant natures as well as confirmative for cells of origin of these tumours. The histomorphological examination is used for confirmative diagnosis. Tumour morphology in FML is discrete, and mobile with a fibrous capsule. MSL is nonencapsulated and diffuse and may infiltrate deep tissue. The findings of the capsule in the present case were more in concordance with FML.

Nilesh Reddy et al. suggest that mutation of gene PALB2 is associated with familial lipomatosis syndrome.<sup>8</sup> Unfortunately, molecular facilities were not available in our institution. They also suggest that this gene mutation is related to sarcomatous changes also.

Due to lack of data availability confirmative genetic alteration is debatable till now. The diagnostic approach is based on familial history, clinical history and invasive procedures like FNAC or biopsy. They can often progress to sarcomas as in the case of Cowden syndrome. The only treatment for multiple lipomatosis is surgical removal.

#### 4. Conclusion

The importance of specifically emphasizing this case is to stress the fact that negligence on the part of the patient due to lack of alarming symptoms, other than cosmetic only and that on the part of the clinician due to lack of thorough examination may lead to progression of this benign condition into a more aggressive tumour. Future research on these cases is recommended for early diagnosis

and correct treatment modality.

#### 5. Source of Funding

None.


#### 6. Conflict of Interest

None.

#### References

1. Bracaglia R, D'Etto M, Gentileschi S, Mingrone G, Tambasco D. Multiple lipomatosis after stem cell trasplant and chemotherapy: a case report. *Eur Rev Med Pharmacol Sci*. 2014;18(3):413–5.
2. Femia A, Klein PA. Letter: Iatrogenic lipomatosis: a rare manifestation of treatment with a peroxiso- me proliferator-activated receptor gamma ago- nist. *Dermatol Online J*. 2010;16(4):15.
3. Ronan SJ, Broderick T. Minimally invasive ap- proach to familial multiple lipomatosis. *Plast Reconstr Surg*. 2000;106(4):878–80.
4. Gupta TKD. Tumors and tumor-like conditions of the adipose tissue. *Curr Probl Surg*. 1970;7(3):1–60.
5. Ware R, Mane A, Saini S, Saini N. Familial multiple lipomatosis- a rare syndrome diagnosed on FNAC. *Int J Med Sci Public Health*. 2016;5(2):367–9.
6. Lomartive N, Ciocca F, Distanislaio C, Bologna G, Giuliani M. Multiple symmetrical lipomatosis (MSL): a clinical case and a review of the literature. *Ann Ital Chir*. 1999;70(2):259–62.
7. Gologorsky Y, Gologorsky D, Yarygina AS, Surti U, Zirwas MJ. Familial multiple lipomatosis: report of a new family. *Cutis*. 2007;79(3):227–32.
8. Reddy N, Malipatil B, Kumar S. A rare case of familial multiple subcutaneous lipomatosis with novel PALB2 mutation and increased predilection to cancers. *Hematol Oncol Stem Cell Ther*. 2016;9(4):154–6.

#### Author biography

**Kartavya Kumar Verma**, Senior Resident  <https://orcid.org/0000-0002-0642-2437>

**Cite this article:** Verma KK. A rare case report of familial multiple lipomatosis and its diagnostic approach with review of literatures. *Indian J Pathol Oncol* 2023;10(3):300-302.