



Case Report

Synchronous presentation of borderline phyllodes tumour and tubular adenoma in a background of fibrocystic disease - A case report

Vishnusri R^{1,*}, Luck C P¹, Sangeetha B S¹, Sarah Kuruvilla¹

¹Dept. of Pathology, Tagore Medical College and Hospital, Chennai, Tamil Nadu, India



ARTICLE INFO

Article history:

Received 10-06-2023

Accepted 17-08-2023

Available online 27-09-2023

Keywords:

Fibroepithelial lesion

Phyllodes tumour

Tubular adenoma

ABSTRACT

Mammary fibroepithelial lesions encompass a wide spectrum of tumours ranging from an indolent fibroadenoma to potentially fatal malignant phyllodes tumour. Here, we report a case of 22-year-old unmarried girl with bilateral breast lump for one month who underwent wide local excision which on histopathological examination revealed borderline phyllodes tumour and tubular adenoma in a background of fibrocystic disease with adenosis, marked epithelial hyperplasia, fibro adenomatoid change and apocrine metaplasia a rare occurrence which can be confused with benign and malignant lesions of the breast.

This is an Open Access (OA) journal, and articles are distributed under the terms of the [Creative Commons Attribution-NonCommercial-ShareAlike 4.0 License](https://creativecommons.org/licenses/by-nc-sa/4.0/), which allows others to remix, tweak, and build upon the work non-commercially, as long as appropriate credit is given and the new creations are licensed under the identical terms.

For reprints contact: reprint@ipinnovative.com

1. Introduction

Mammary fibroepithelial tumours exhibit abnormal growth of intralobular stromal cells accompanied by proliferation of epithelial cells. The specific entities include fibroadenoma (adult, myxoid, juvenile, complex), benign, borderline and malignant phyllodes tumour and peri ductal stromal tumour. Hamartoma are not strictly fibroepithelial tumours, but are included as they are circumscribed lesions with lobular glands and fibroadipose stroma.¹ Epithelial changes include usual ductal hyperplasia, Atypical ductal hyperplasia, lobular neoplasm and ductal carcinoma in situ.² These changes occur commonly in phyllodes tumour, where stromal components are considered the biological driver of behaviour of the tumour.

Here we report a case of complex fibroepithelial tumour of breast with borderline phyllodes tumour, tubular adenoma in a background of fibrocystic disease with adenosis, fibrosis, marked epithelial hyperplasia, fibro adenomatoid change and apocrine metaplasia which is a rare occurrence.

* Corresponding author.

E-mail address: srivishnusri730@gmail.com (Vishnusri R).

2. Case History

21 year old unmarried girl with negative family history of breast cancer presented with lump in both breasts for a duration of one month. Bilateral ultrasonogram (USG) breasts showed features suggestive of fibro adenomatous lesions. Fine needle aspiration cytology of lesions from both breasts showed features suggestive of benign fibroadenoma.

Core needle biopsy from left breast lesion on microscopy study showed breast tissue with proliferation of epithelial and stromal components. Epithelial component consists predominantly of intracanalicular ductal pattern with inner cuboidal and outer myoepithelial cells. There was focal epithelial hyperplasia and the stroma appeared edematous in foci with slight increase in cellularity. There is no obvious increase in mitosis. In other areas the stroma appears fibro collagenous with focal myxoid change with no evidence of any atypia. A final impression of fibroepithelial tumor was considered with a differential diagnosis of benign phyllodes tumor or giant fibroadenoma.³

With this preoperative tissue diagnosis, she underwent wide local excision of left breast and lumpectomy of the right breast lesion.

Gross Examination of Left breast tissue showed a globular grey brown mass measuring 6.5 x 6 x 3cm with external surface showing lobulations and the cut section showed grey white firm bulging areas with slit like spaces (Figure 1 A).

Histopathological examination of multiple sections of left breast showed a biphasic fibroepithelial tumour, a portion of which had exaggerated intracanalicular pattern with stromal hypercellularity and overgrowth. The stromal cells are spindle with mild to moderate atypia exhibiting mitotic figures 4-6\HPF. Another portion of the tumour showed sheets of closely packed round to oval tubules lined by epithelial and myoepithelial cells with scant intervening stroma showing features of tubular adenoma.⁴ The adjacent areas showed a background of extensive fibrocystic change with adenosis, fibrosis, marked epitheliosis, fibro adenomatoid change and apocrine metaplasia (Figure 1 B-F).

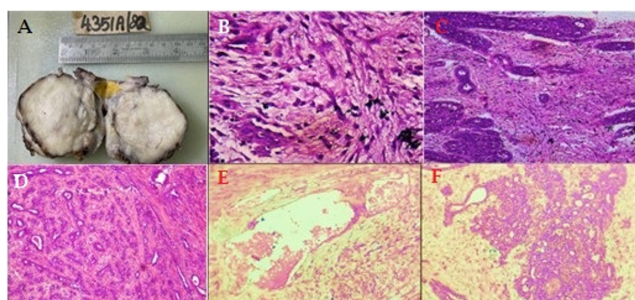


Fig. 1:

Gross examination of the right breast showed a grey brown nodular mass measuring 2 x 2 x 1 cm. with cut section having a grey white, firm slit like spaces. On microscopy there was a well encapsulated fibroepithelial neoplasm with proliferation of duct epithelial and stromal components showing predominantly an intracanalicular pattern of fibroadenoma (Figure 2 A). The ducts are lined by inner epithelial cells and outer myoepithelial cells surrounded by fibrous stroma. Adjacent area shows normal breast parenchyma.

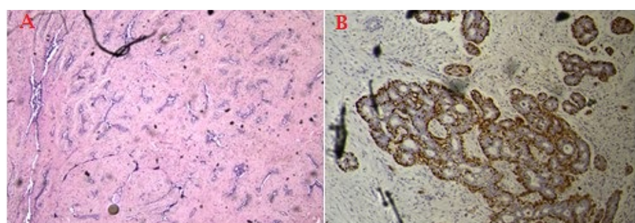


Fig. 2:

With this microscopic picture, diagnosis of a complex fibroepithelial tumor of the breast with borderline phyllodes tumor along with tubular adenoma in a background of

fibrocystic disease in the left breast and fibroadenoma of right breast was made. This positivity for S100 (Figure 2 B) in the myoepithelial cells showing features suggestive of tubular adenoma ruling out ductal carcinoma in situ.

3. Discussion

Complex fibroepithelial lesion comprises of heterogenous group of biphasic tumours with proliferation of epithelial and mesenchymal structure along with distortion of the lobulocentric architecture. Exhibiting fibroadenoma, phyllodes tumour and periductal stromal tumour.

Fibroadenoma is the most common benign lump in the breast which may be single or multiple and unilateral or bilateral which arises as a result of hyperplasia of normal lobules. They are cellular, complex, juvenile and myxoid types. The pathogenesis is MED12 mutations associated with dysregulated oestrogen signalling and extracellular matrix organisation except myxoid type which shows PRKAR1A gene mutation.⁵ On external appearance fibroadenoma are well circumscribed ovoid nodules which on cut section exhibit white whorled fibrous appearance. On microscopic examination of fibroadenoma there is proliferation of loose cellular stromal connective tissue, with variable number of ductular structures. Stromal nuclei are spindle shaped and normally exhibit mild pleomorphism with infrequent mitosis. The two classic pattern are intracanalicular and peri canalicular pattern.

Phyllodes tumor are rare and accounts for less than 1% of all mammary neoplasms and 2.5% of fibroepithelial lesions in the breast. They are classified into benign, borderline and malignant phyllodes. Phyllodes tumor mainly originates from intralobular and periductal stroma, with epithelial-stromal interactions contributing to its pathogenesis.⁶ Recurrent MED12 mutations in stromal cells present in phyllodes tumor, supporting a shared pathogenesis with fibroadenoma. Malignant phyllodes have lower rate of MED12 mutations than benign and borderline phyllodes and shows more alterations in cancer-related genes. On microscopic examination there is prominent intracanalicular architectural pattern with leaf-like stromal fronds. Lined by luminal epithelial and myoepithelial cell layers accompanied by increased stromal cellularity. Most phyllodes tumors are benign. Local recurrences usually occur within 2-3 years of diagnosis. Margin status at excision is the most reliable predictor of recurrence, except in benign tumors, where it seems to be less relevant. Axillary lymph node metastases are rare and distant metastases occur in about 2% of tumors and are seen almost exclusively in malignant phyllodes tumors.

Tubular adenoma is a pure mammary adenoma. On Gross visualisation they have a well circumscribed, finely nodular structure. On microscopic examination they consist of closely packed tubular structures which are lined by bilayered ductal and scant flattened myoepithelial cells with a

small amount of fine connective tissue stroma.

Periductal stromal tumour is a rare biphasic tumour of the breast that exhibits low grade malignancy and intermediate behaviour. It is characterized by proliferation of atypical spindle cells surrounding benign mammary ducts and infiltrating adjacent adipose tissue.

4. Conclusion

In conclusion the spindle cell neoplasm of the breast deserves a special mention due to its rarity.⁷ Extensive sampling must be done to rule out epithelial entrapment and malignant heterologous component. The margin status at excision appears to be the most reliable predictor of recurrence. An algorithm approach is crucial for pathologists as these neoplasms show morphological overlap.⁸ Immunohistochemistry is the frequently warranted ancillary technique, which when coupled with histopathological finding helps in accurate diagnosis. Core needle biopsy poses a risk of sampling error in this case and upgrading at the time of excision of the specimen can frequently occur. Hence, knowledge of the complex fibroepithelial lesion is needed for defining management and to prevent local recurrences. Given the significant clinical differences in various subtypes although IHC markers are useful in differential diagnosis. Histomorphology still remains the gold standard for accurate pathological classification and management.

5. Source of Funding

None.

6. Conflicts of Interest

There are no conflicts of interest.

References

1. Krings G, Bean GR, Chen YY. Fibroepithelial lesions; The WHO spectrum. *Semin Diagn Pathol.* 2017;34(5):438–52.
2. Tan PH. Fibroepithelial lesions revisited: implications for diagnosis and management. *Mod Pathol.* 2021;34(1):15–37.
3. Yasir S, Gamez R, Jenkins S, Visscher DW, Nassar A. Significant histologic features differentiating cellular fibroadenoma from phyllodes tumor on core needle biopsy specimens. *Am J Clin Pathol.* 2014;142(3):362–9.
4. Ibisevic N, Bajrovic J, Saranovic E, Spiritovic D, Skenderi F, Vranic S. A Giant, Complex Fibroepithelial Tumor of the Breast: Borderline Phyllodes Tumor Combined with Tubular Adenoma - a Rare Clinical Presentation of a Fibroepithelial Tumor of the Breast. *Acta Med Acad.* 2021;50(1):218–20.
5. Lozada JR, Burke KA, Maguire A, Pareja F, Lim RS, Kim J, et al. Myxoid fibroadenomas differ from conventional fibroadenomas: a hypothesis-generating study. *Histopathology.* 2017;71(4):626–34.
6. Tummidi S, Kothari K, Agnihotri M, Naik L, Sood P. Fibroadenoma versus phyllodes tumor: a vexing problem revisited! *BMC Cancer.* 2020;20(1):648. doi:10.1186/s12885-020-07129-0.
7. Li JJ, Tse GM. Spindle cell lesions of the breast: diagnostic issues. *Diagn Histopathol.* 2020;26(2):76–87.
8. Tse GMK, Tan PH, Lui PCW, Putti TC. Spindle cell lesions of the breast—the pathologic differential diagnosis. *Breast Cancer Res Treat.* 2008;109(2):199–207.

Author biography

Vishnusri R, Junior Resident

Luck C P, HOD

Sangeetha B S, Associate Professor

Sarah Kuruvilla, Professor

Cite this article: Vishnusri R, Luck C P, Sangeetha B S, Kuruvilla S. Synchronous presentation of borderline phyllodes tumour and tubular adenoma in a background of fibrocystic disease - A case report. *Indian J Pathol Oncol* 2023;10(3):294–296.