



## Case Series

# Morphological perspective of skin adnexal tumours: A case series

Sarbashis Hota<sup>1,\*</sup>, Sukanya Ghosh<sup>1</sup>, Sneha Jha<sup>1</sup>, Tushar Kanti Das<sup>1</sup>

<sup>1</sup>Dept. of Pathology, R G Kar Medical College & Hospital, Kolkata, West Bengal, India



### ARTICLE INFO

#### Article history:

Received 02-07-2023

Accepted 24-08-2023

Available online 27-09-2023

#### Keywords:

Skin tumour

Sebaceous carcinoma

Histopathology

### ABSTRACT

Adnexal or appendageal tumours of skin comprise an important subcategory of cutaneous neoplasms, although thorough understanding of this entity is still in its early stages. The role of immunohistochemistry in diagnosis is particularly limited, and, it is morphology that actually guides pathologists for clinching diagnosis. Here, we present three uncommon cases of skin adnexal tumours- a case of retiform trichoblastoma, trichilemmal carcinoma and sebaceous carcinoma; especially highlighting the morphological approach of diagnosis and the associated clinical implications based on literature review.

This is an Open Access (OA) journal, and articles are distributed under the terms of the [Creative Commons Attribution-NonCommercial-ShareAlike 4.0 License](https://creativecommons.org/licenses/by-nc-sa/4.0/), which allows others to remix, tweak, and build upon the work non-commercially, as long as appropriate credit is given and the new creations are licensed under the identical terms.

For reprints contact: [reprint@ipinnovative.com](mailto:reprint@ipinnovative.com)

## 1. Introduction

Adnexal or Appendageal tumours of skin comprise an important subcategory of cutaneous neoplasms, although thorough understanding of this entity is still in its early stages.<sup>1</sup> Owing to the relative rarity, authentic epidemiological data is scarce in the existing literature when both benign and malignant categories are combined. A well acknowledged treatment protocol is yet to come, as available data is sparse in existing literature. Moreover, the role of immunohistochemistry in diagnosis is particularly limited in this scenario,<sup>2</sup> and, it is morphology that actually guides pathologists for clinching diagnosis. Even the clinically significant distinction between benign and malignant may not be possible always; hence, recent WHO classification even recommends that a report of skin adnexal tumour of uncertain malignant potential may be despatched in such cases, if necessary.<sup>3</sup>

Here, we present three uncommon cases of skin adnexal tumours, highlighting the morphological approach of diagnosis and the associated clinical implications based

on literature review.

## 2. Case 1

History: A small tumour from back of the neck, in a 50 years old male, persisting for last 6 years, measuring 1 cm in maximum dimension was resected and submitted for histopathological examination.

Microscopy (Figure 1): Sections showed an adnexal tumour localised in dermis comprising cords and columns of neoplastic bland basaloid cells creating a net like pattern amidst a characteristic stroma. Histomorphological features were suggestive of a Benign adnexal tumour of hair follicle differentiation-Retiform Trichoblastoma.

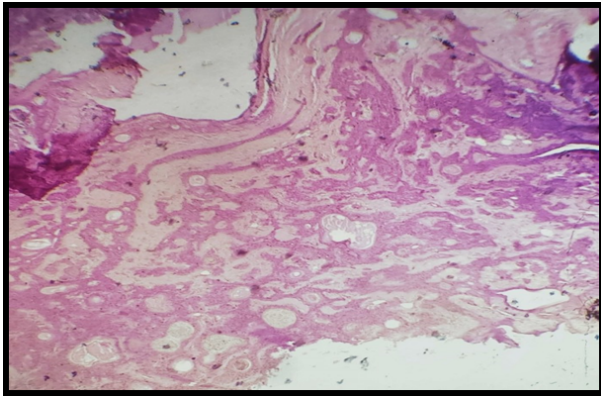
The closest differential diagnosis were basal cell carcinoma but circumscribed nature of the lesion, lack of ulceration spoke against it.

## 3. Case 2

History: A 66 years old male presented with a 3x2 cm ulcerated nodule on arm, of 6 months duration with aggravation of recent onset. The lesion had irregular borders with fixity to underlying structures and local induration. A

\* Corresponding author.

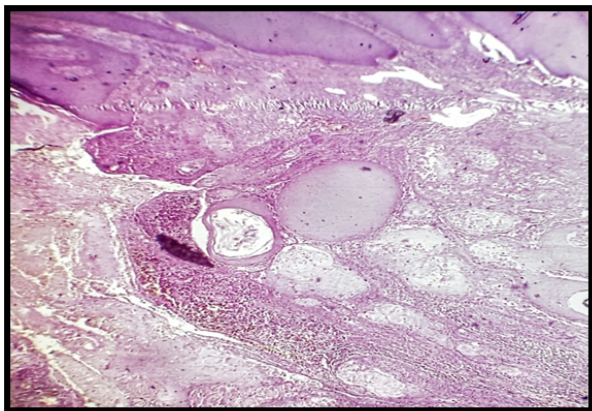
E-mail address: [sarbashishota94@gmail.com](mailto:sarbashishota94@gmail.com) (S. Hota).



**Fig. 1:** Retiform Trichoblastoma- adnexal tumour localised in dermis comprising cords and columns of neoplastic bland basaloid cells creating a net like pattern amidst a characteristic stroma (100X)

wide local excision was performed and the resected tumour was sent for histopathological examination.

Microscopy (Figure 2): Sections showed a dermis based neoplasm with connection to epidermis, invading the underlying tissues. Individual cells are highly atypical with hyperchromatic, pleomorphic nuclei and brisk mitotic activity. Multiple foci of trichilemmal type keratinisation (abrupt keratinisation without any intervening granular cell layer) are noted, as well as necrosis and occasional areas of cytoplasmic clearing. Histomorphological features were suggestive of Trichilemmal carcinoma.



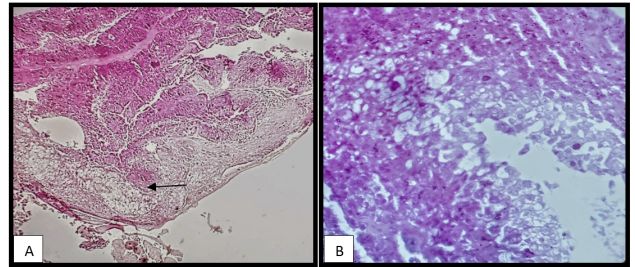
**Fig. 2:** Trichilemmal carcinoma- Sub-epidermal sheets of atypical epithelial cells with necrosis and trichilemmal type keratinization (100X)

The closest differential diagnoses were clear cell variant of squamous cell carcinoma and proliferating trichilemmal tumour. Trichilemmal type of keratinisation is not found in the first entity, where as marked nuclear atypia is unusual in the later case.

#### 4. Case 3

History: A small ulcerated swelling in the peri-ocular region of a 70 years old male of 1 month duration was resected and the sample was sent for histopathological examination.

Microscopy (Figure 3): Sections showed a neoplastic lesion centred on dermis having sheets and lobules of poorly differentiated cells having high N: C ratio, nuclear pleomorphism, prominent nucleoli and high mitotic activity. However, more differentiated areas showed polygonal cells with abundant amphophilic cytoplasm and vesicular nucleus having distinct nucleolus.



**Fig. 3:** Sebaceous carcinoma- **A):** Poorly differentiated sheets of cells encroaching pilo-sebaceous units (40X); **B):** Multi-vesicular, bubbly cytoplasm of tumour cells in the background of necrosis (400X)

Multivesicular cytoplasmic clearing with scalloping of nucleus are apparent in these regions imparting a bubbly appearance on the cells. Encroachment of pilo-sebaceous units is noted in the sections. The histomorphological features are in favour of malignant adnexal tumour of sebaceous differentiation- Sebaceous carcinoma.

The closest differential diagnoses were basal cell carcinoma and sebaceoma. The characteristic multivesicular bubbly cytoplasm goes against BCC where as frank invasive features with presence of necrosis rule out the diagnosis of sebaceoma. IHC for EMA, showing membranous positivity in tumour cells, were corroborative of the diagnosis, however the location and characteristic morphology were sufficient to clinch a diagnosis.

#### 5. Discussion

The adnexal tumours are primarily classified based on their modes of differentiation- Eccrine-apocrine, Sebaceous or hair follicular type.<sup>3</sup> The problem is, not only each entity shows remarkable variability of histological appearance, there is considerable overlap among them (Even neoplastic entity showing multilineage differentiation is also evident).<sup>3</sup> This reflects the common embryological origin of different adnexal structures; although many a times, they are characterized by the particular embryological event of development they recapitulate.

The basic approach relies on identification of the lineage of differentiation, which are solely based on morphological traits. The location of the tumour, connection with epidermis and other cyto-architectural findings will help it further. However, exact categorization of skin adnexal tumours is often important, based on their association with rare familial syndromes of autosomal dominant inheritance.<sup>3</sup> Well, of course, they are more commonly sporadic in nature;- presence of multiple lesions in young age should always raise suspicion about this.

Trichoblastoma is a benign adnexal neoplasm, usually biphasic in appearance showing dual differentiation towards follicular germinative epithelium as well as the specific follicular stroma.<sup>3</sup> Based on architectural types, they may be Large nodular, small nodular, adamantinoid, retiform and racemiform. Cribriform and columnar trichoblastoma (otherwise known as conventional and desmoplastic Trichoepithelioma) are also included. Multiple lesions are associated with Familial disorder of Brooke-Spigliers syndrome.<sup>1</sup>

Trichilemmal carcinoma is a malignant adnexal tumour showing outer root sheath differentiation. It is regarded as a low grade malignancy with good prognosis. The patient underwent wide local excision.

Variants of Sebaceous carcinoma (like Basaloid, Squamous, cases with pseudo-neuroendocrine, myoepithelial and apocrine differentiation) may mimic other cutaneous neoplasms. The hall marks of sebaceous differentiation can be totally missed in these cases, if not actively searched for. 25% cases of sebaceous carcinoma are associated with Muir-Torre syndrome.<sup>2</sup>

Rajalakshmi V et al,<sup>4</sup> Kaur K et al,<sup>5</sup> Manjunath H K et al<sup>6</sup> studied 21, 110 and 52 cases of skin adnexal tumours respectively over different time interval and underscored the role of histomorphology in correct diagnosis of this group of tumours.

In the review article, Crowson A et al<sup>7</sup> has elaborated the diagnostic challenges associated with malignant adnexal tumours. Waqas O et al<sup>8</sup> and Oyasiji T et al<sup>9</sup> reported the cases of malignant adnexal tumours from Pakistan and USA respectively. According to them, younger patients had better overall survival and recurrence free survival. Presence of nodal metastasis was found to be a poor prognostic factor. Plachta I et al<sup>10</sup> have discussed the management approach of skin adnexal tumours, after summarizing the key points of diagnosis.

In the present case series, the first case of Retiform Trichoblastoma responded well with the surgical procedure, and no evidence of recurrence is there till date. There was a local recurrence in the case of Trichilemmal carcinoma, for which the patient underwent a second wide local excision. But on clinical work up, multiple metastatic deposits were found in the case of Sebaceous Carcinoma, hence, the patient was referred for consideration of adjuvant chemotherapy.

## 6. Conclusion

The basic approach relies on identification of the lineage of differentiation, which are solely based on morphological traits. The location of the tumour, connection with epidermis and other cyto-architectural findings will help it further. The role of Immunohistochemistry is still rudimentary sparing a few specific cases, however molecular genetic studies may be instrumental for diagnosis of familial syndromes. Newer informations gathered from ongoing research are likely to improve our understanding of this neoplastic entity in near future.

## 7. Source of Funding

None.

## 8. Conflict of Interest

None.

## References

1. Goldblum JR, Lamps LW, Mckenney JK, Myers JL. Rosai & Ackermann's surgical pathology. 11th ed. Philadelphia: Elsevier; 2018.
2. Elder DE, Elenitsas R, Rosenbach M, Murphy GF, Rubin AI, Xu X. Lever's Dermatopathology Histopathology of the skin. 11th ed. Philadelphia: Wolters Kluwer; 2015.
3. Elder DE, Massi D, Scolyer RA, Willemze R. WHO classification of skin tumours. International Agency for Research on Cancer. 4th ed. Lyon: IARC; 2018.
4. Rajalakshmi V, Selvakumar S, Rajeswari K, Meenakshisundaram K, Veena G, Ramachandran P. Case series of skin adnexal tumours. *J Clin Diagn Res.* 2014;8(9):7–10.
5. Kaur K, Gupta K, Hemrajani D, Yadav A, Mangal K. Histopathological analysis of skin adnexal tumours: A three year study of 110 cases at a tertiary care centre. *Indian J Dermatol.* 2017;62(4):400–6.
6. Manjunath HK, Mohan B, Dharani VC, Thej MJ, Sushma TA, Rai H. Histomorphological pattern of analysis of skin adnexal tumours- a retrospective study. *Natl J Lab Med.* 2020;9(4):39–42.
7. Crowson A, Margo C, Mihm M. Malignant adnexal neoplasms. *Mod Pathol.* 2006;19:93–126.
8. Waqas O, Faisal M, Haider I, Amjad A, Jamshed A, Hussain R. Retrospective study of rare cutaneous malignant adnexal tumors of the head and neck in a tertiary care cancer hospital: a case series. *J Med Case Rep.* 2017;11(1):67.
9. Oyasiji T, Tan W, Kane J. Malignant adnexal tumours of the skin: a single institution experience. *World J Surg Oncol.* 2018;16(1):99.
10. Plachta I, Kleibert M, Czarnicka AM, Spalek M, Szumera-Ciekievicz A, Rutkowski P. Current diagnosis and treatment options for cutaneous adnexal neoplasms with apocrine and eccrine differentiation. *Int J Mol Sci.* 2021;22(10):5077. doi:10.3390/ijms22105077.

## Author biography

**Sarbashis Hota**, Senior Resident

**Sukanya Ghosh**, Senior Resident

**Sneha Jha**, Senior Resident

**Tushar Kanti Das**, Professor and Head

**Cite this article:** Hota S, Ghosh S, Jha S, Das TK. Morphological perspective of skin adnexal tumours: A case series. *Indian J Pathol Oncol* 2023;10(3):274-277.