



Case Report

Biphasic synovial sarcoma with squamous differentiation in the thigh – A case report

Akanksha Hegde^{1,*}, Sindhoor¹, Vijaya Mysorekar¹

¹Dept. of Pathology, M.S Ramaiah Medical College, Bengaluru, Karnataka, India



ARTICLE INFO

Article history:

Received 26-03-2023

Accepted 11-04-2023

Available online 17-06-2023

Keywords:

Biphasic synovial sarcomas

Spindle cell component

Epithelial component

Squamous differentiation

Lymph node metastasis

Immunohistochemistry

Molecular techniques

ABSTRACT

Synovial sarcoma (SS) is a rare type of high-grade soft tissue sarcoma that accounts for 5% to 10% of all soft tissue tumors. It primarily affects the soft tissue of the arms and legs. The rate of lymph node metastases in synovial sarcoma is 3% to 7%.

They are locally aggressive and have a higher metastatic potential. The overall prognosis of patients is poor due to systemic metastasis. Immunohistochemistry and molecular studies are indispensable in the diagnosis of these tumors.

We present to you a case of biphasic synovial sarcoma of left thigh in a 70-year-old lady with lymph node metastasis and squamous differentiation.

This is an Open Access (OA) journal, and articles are distributed under the terms of the [Creative Commons Attribution-NonCommercial-ShareAlike 4.0 License](https://creativecommons.org/licenses/by-nc-sa/4.0/), which allows others to remix, tweak, and build upon the work non-commercially, as long as appropriate credit is given and the new creations are licensed under the identical terms.

For reprints contact: reprint@ipinnovative.com

1. Introduction

Synovial sarcoma makes up to 5% to 10% of all soft tissue tumors.¹ The etiology is unknown. Tumor arises from multi-potential stem cells with differentiation into the epithelial or mesenchymal structures.² They typically present in lower extremities (most commonly around the knee) and most commonly in periarticular regions. It may also present in trunk, head and neck, thorax, mediastinum, chest wall, lumbar spine, and heart.³

These tumors present as palpable mass associated with the pain or tenderness.

This tumor is classified histologically into biphasic, monophasic and poorly differentiated types.²

They are characterized by the t(X,18) (p11; q11) chromosomal translocation.²

2. Case Report

A 70-year-old lady came with complaints of swelling in left upper thigh for 3 months which gradually increased in size, not associated with pain.

She is a known case of diabetes mellitus, hypertension and obstructive sleep apnea.

General physical and systemic examination findings were normal. Pulse rate - 78bpm, BP-130/80 mm of Hg, SpO₂ was 88%.

Local examination of left groin and thigh showed a 10 x10 cm globular swelling on antero-medial aspect of left thigh mobile, firm and non-tender.

Also seen was enlarged, mobile left inguinal lymph node measuring 1x1cm. PET CT scan was done on 27/06/22, which showed 12.8 x 11 x 11.6cm metabolically active necrotic mass lesion on left upper thigh in subcutaneous plane, 11 x 7mm enhancing nodule along medial patellofemoral synovial region. Also noted enlarged left external iliac lymph nodes, largest measuring 2.1 x 1.1cm. No lung metastasis was noted.

* Corresponding author.

E-mail address: akankhegde96@gmail.com (A. Hegde).

Tru-cut biopsy of left thigh mass was taken on 28/04/22. Microscopically it showed an invasive tumor composed of malignant tumor cells which were spindle shaped, arranged in diffuse sheets. Individual tumor cells were highly pleomorphic exhibiting hyperchromatic nucleus, indistinct nucleoli and scanty eosinophilic cytoplasm. Many atypical mitoses were also noted. Intervening stroma showed areas of necrosis, fibrosis and congestion.

The final diagnosis was given as high-grade spindle cell sarcoma.

The patient was later taken up for wide local excision of left thigh tumor and lymph node dissection on 20/07/22. Intraoperatively a 12 x 12 cm tumor was noted on the medial aspect of left thigh abutting the femoral vessels. Few enlarged peritumoral inguinal lymph nodes, external iliac and obturator nodes noted. The specimen was sent for histopathological examination and given surgical number S-2228/22.

Grossly noted a specimen consisting of skin covered soft tissue resected mass measuring 20 x 15 x 14cm (Figure 1). Overlying skin measured 20 x 12.5cm. On cut surface noted a cyst measuring 12 x 11.5 x 11cm. 25ml of hemorrhagic fluid oozed out. Also noted a solid area measuring 7 x 6 x 3.5cm. It appears variegated, with hemorrhagic and necrotic areas (Figures 2 and 3).

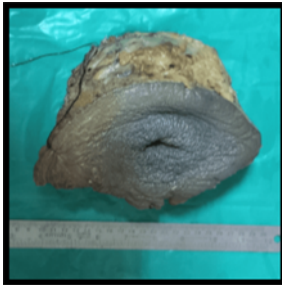


Fig. 1: Showing the external surface of the mass

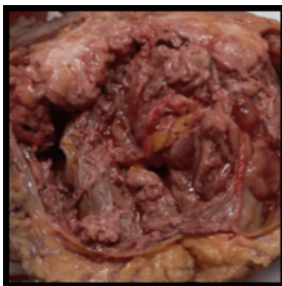


Fig. 2: Showing the cut surface of the mass

Microscopically section studied showed an invasive highly pleomorphic biphasic tumor. Spindle cell component was arranged in fascicles, solid sheets, bundles and nests (Figure 7). The epithelial component was arranged in

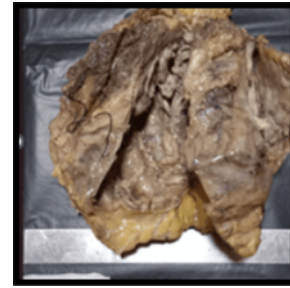


Fig. 3: Showing the cut surface of the mass

solid diffuse sheets and nests composed of abundant pleomorphic cells which showed irregular nuclear membranes, abundant eosinophilic cytoplasm, vesicular nucleus, coarse chromatin, prominent nucleoli. Squamous differentiation was evident (Figures 4 and 5). The spindle cell component showed elongated stout, blunt ends, vesicular nucleus and prominent nucleoli. Few cystic spaces were noted. 5-6 mitosis/Hpf (score 3) was noted. Abundant necrosis (score 2) and desmoplastic stroma noted with dense lymphocytes and neutrophils (Figure 6). Lymphovascular / perineural invasion was absent.

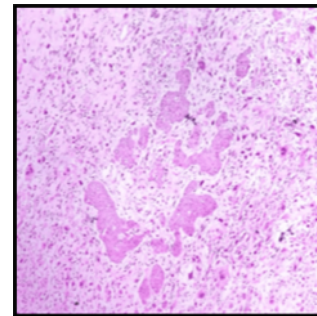


Fig. 4: H&E, X 100 Showing squamous differentiation

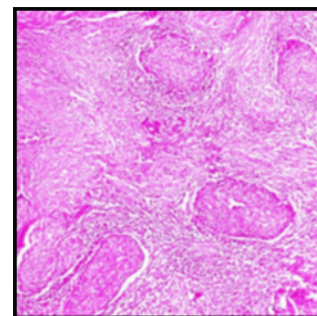


Fig. 5: H&E, X 400 Showing squamous differentiation

Out of 21 lymph nodes 3 left internal iliac nodes showed metastatic deposits.

All margins were free of tumor.

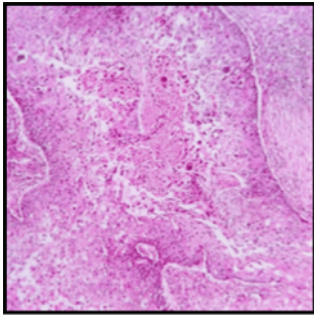


Fig. 6: H&E, X 400 shows necrosis

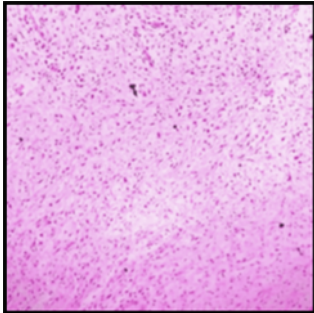


Fig. 7: H&E, X 100 shows spindle cell component

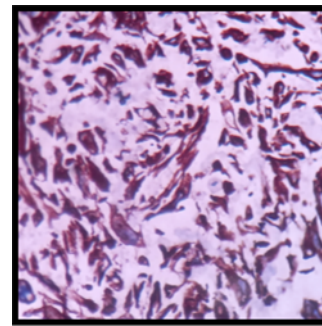


Fig. 9: Vimentin shows membranous positivity in spindle cell, (IHC, X400)

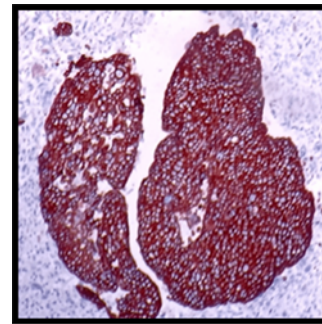


Fig. 10: Pan- CK nuclear expression in epithelial component, (IHC,X100)

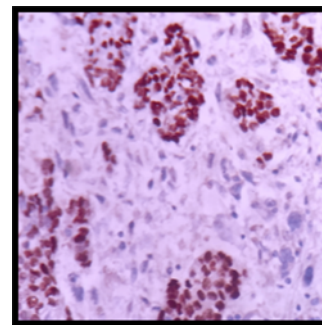


Fig. 11: P63 shows nuclear positivity in epithelial component, (IHC, X400)

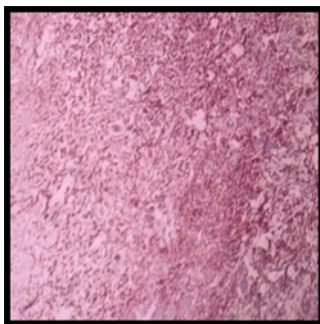


Fig. 8: CD99 shows membranous positivity in spindle cell component, (IHC, X100)

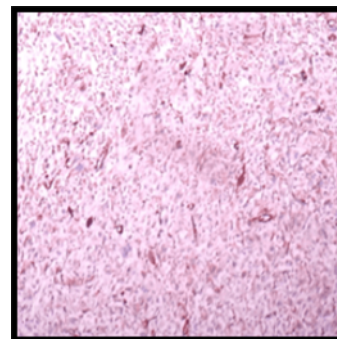


Fig. 12: SMA shows cytoplasmic and membranous positivity in spindle cell component, (IHC, X100)

The final report was given as Biphasic synovial sarcoma, Grade 3, PT3 N1 Mx, AJCC stage - IV.

Immunohistochemistry (IHC) test was done on the excision specimen. SMA (Figure 12), CD 99(Figure 8), Vimentin (Figure 9) showed membranous positivity in spindle cell component. CD68 (Figure 13) showed cytoplasmic / dot like granular positivity in spindle cell component. Bcl-2 (Figure 14) faint cytoplasmic positivity in spindle cell component. Pan CK and p63 showed nuclear expression in epithelial component.

S100 (Figure 15), Myogenin (Figure 16), Desmin (Figure 18), CD34 (Figure 17) were negative in both epithelial and spindle cell components. IHC was also suggestive of Biphasic synovial sarcoma.

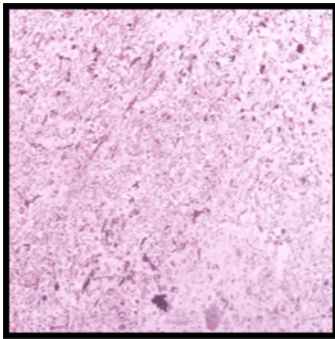


Fig. 13: CD68 Cytoplasmic/ dot like granular positivity in spindle cell component, (IHC, X100)

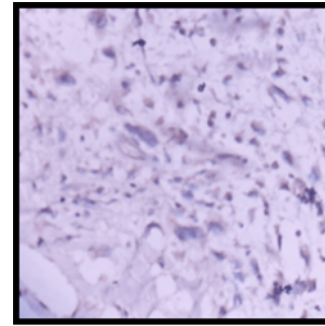


Fig. 17: CD34 is negative in both epithelial and spindle cell components, (IHC,X100)

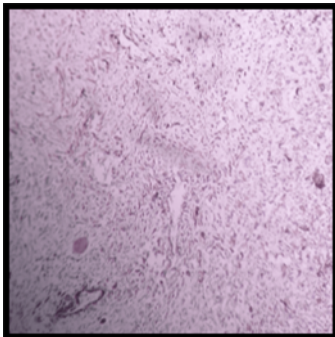


Fig. 14: BCL-2 shows faint cytoplasmic positivity in spindle cell component, (IHC,X100)

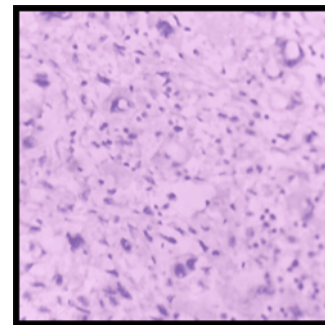


Fig. 18: DESMIN is negative in both epithelial and spindle cell components, (IHC, X100)

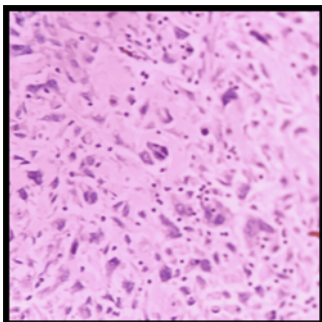


Fig. 15: S-100 is negative in both epithelial and spindle cell components, (IHC, X100)

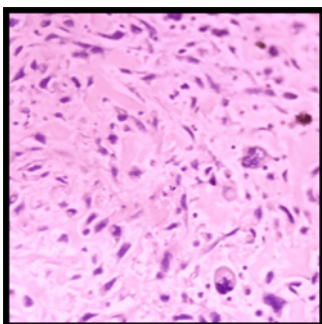


Fig. 16: MYOGENIN is negative in both epithelial and spindle cell components, (IHC, X100)

3. Discussion

Synovial sarcoma is an aggressive neoplasm that usually spread via the hematogenous route.

According to the study done by Woo Ha Young et al., only 3% to 7% of SS patients show lymph node metastases.³

In our case 3 lymph nodes showed this rare finding of tumor metastases.³

Kottu R et al, concluded that aggressive tumors showed high cellularity, cellular anaplasia, necrosis and a high mitosis rate. Necrosis was found to be rare and seen in recurrent or metastatic diseases. Mitoses was also found to be uncommon and seen mostly in poorly differentiated variants.⁴ Our study showed this unique feature of high mitosis and abundant necrosis, making it prognostically poor.

IHC study done by Mirzaian E et al, showed that the glandular components of the tumors expressed pan CK, CK7, CK19 and EMA strongly. Bcl2 was only positive in spindle cells. CD99 and TLE1 (Transducin-Like enhancer of split-1) was positive in both spindle and epithelial components. CD34 was negative in both components.²

Woo Ha Young et al. study, also showed diffuse and strong nuclear staining with TLE1 and focal weak cytoplasmic staining for pan-cytokeratin.³

Kottu R et al, showed positive expression for Cytokeratin and CD34, but S100 was negative.⁴

IHC analysis done by Liang D et al, showed positive expression for CK-pan, vimentin, CD99, TLE1, CD117 and Ki-67(20%+). Whereas myogenin, CK20, PAX-8, WT-1, SMA, S-100, CD34 and desmin were negative.⁵

In support with the above studies the IHC analysis in our case also showed that SMA, CD 99, Vimentin, Bcl-2 and CD 68 were positive in spindle cell component. Pan CK and p63 showed nuclear expression in epithelial component. S100, Myogenin, Desmin, CD34 were negative in both epithelial and spindle cell components. TLE1 was not done due to unavailability of the marker in our laboratory setting.

The studies done by Woo Ha Young et al, Kottu R et al, Liang D et al and Mirzaian E et al. showed the chromosomal translocation t(X;18) (p11.2; q11.2), detected by RT-PCR. The studies concluded that it is an important basis for the diagnosis of synovial sarcoma.⁵ However, we could not do the molecular study since the patient was not affordable.

4. Conclusions

Immunohistochemistry plays a vital role in categorization of the histologic tumor type and molecular pathology is the definitive diagnosis.


5. Conflicts of Interest

The authors declare no conflicts of interest.

References

1. Steintraesser L, Agarwal R, Stricker I, Steinau HU, Al-Benna S. Biphasic synovial sarcoma of the extremity: quadruple approach of isolated limb perfusion, surgical ablation, adipofascial perforator flap and radiation to avoid amputation. *Case Rep Oncol*. 2011;4(1):222–8.
2. Mirzaian E, Tavangar SM, Montazeri S, Yeganeh FE. Biphasic Epithelial Predominant Synovial Sarcoma Presenting as Painful Thigh Mass. *Iran J Pathol*. 2019;14(3):261–4.
3. Woo HY. Biphasic synovial sarcoma with a striking morphological divergence from the main mass to lymph node metastasis: A case report. *Medicine (Baltimore)*. 2022;101(1):e28481.
4. Kottu R, Prayaga AK. Synovial sarcoma with relevant immunocytochemistry and special emphasis on the monophasic fibrous variant. *J Cytol*. 2010;27(2):47–50.
5. Liang D, Meng L, Wang S, Yi D, Liu Y. Biphasic synovial sarcomas of the liver: a case report and literature review. *Diagn Pathol*. 2022;17(1):49.

Author biography

Akanksha Hegde, Post Graduate Student  <https://orcid.org/0009-0008-6426-8395>

Sindhoor, Senior Resident  <https://orcid.org/0009-0008-9333-4902>

Vijaya Mysorekar, Professor

Cite this article: Hegde A, Sindhoor, Mysorekar V. Biphasic synovial sarcoma with squamous differentiation in the thigh – A case report. *Indian J Pathol Oncol* 2023;10(2):177-181.