



## Case Report

# Ibrutinib induced sensorimotor neuropathy: A novel side effect

Disha Tiwari<sup>1</sup>, Dipanjan Panda<sup>1,\*</sup>, Atul Sharma<sup>1</sup>, Dewesh Kishan<sup>1</sup>

<sup>1</sup>Dept. of Medical Oncology, Indraprastha Apollo Hospital, New Delhi, India



### ARTICLE INFO

#### Article history:

Received 26-01-2023

Accepted 01-04-2026

Available online 17-06-2023

#### Keywords:

Chemotherapy-induced

Ibrutinib

Sensorimotor neuropathy

CLL

Side effect

### ABSTRACT

Chemotherapy-induced peripheral neuropathy (CIPN) is a well-documented toxicity leading to dose limitation.

Ibrutinib is an oral Bruton's Tyrosine Kinase (BTK) inhibitor approved for treating chronic lymphocytic lymphoma. The most common neurological side effects of Ibrutinib include headache and dizziness. Herein, we report peripheral neuropathy as a dose-limiting manifestation of Ibrutinib treatment.

This is an Open Access (OA) journal, and articles are distributed under the terms of the [Creative Commons Attribution-NonCommercial-ShareAlike 4.0 License](https://creativecommons.org/licenses/by-nc-sa/4.0/), which allows others to remix, tweak, and build upon the work non-commercially, as long as appropriate credit is given and the new creations are licensed under the identical terms.

For reprints contact: [reprint@ipinnovative.com](mailto:reprint@ipinnovative.com)

## 1. Introduction

Chemotherapy-induced peripheral neuropathy (CIPN) is a well-documented toxicity leading to dose limitation. The most common symptoms mentioned in literature are pain and paresthesia, which are partially reversible.<sup>1</sup> CIPN development may often lead to dose reduction or change in the chemotherapeutic agent from the treatment protocol.<sup>2</sup>

Ibrutinib is an oral Bruton's Tyrosine Kinase (BTK) inhibitor approved for treating chronic lymphocytic lymphoma. Ibrutinib's neurological side effect profile includes headache and dizziness in > 10% of recipients.<sup>3</sup> Herein, we report peripheral neuropathy as a dose-limiting manifestation of Ibrutinib treatment.

## 2. Case Report

A gentleman in his seventh decade, with no prior comorbidities, visited our outpatient department two years back with complaints of weight loss of around 8 kilograms over five months and painless progressive lymphadenopathy on both sides of the neck for three

months. His medical history was negative for fever or drenching night sweats. He was thoroughly investigated, and his complete blood count revealed leucocytosis with lymphocytosis. His initial haemoglobin level was 11.1 gm/dl, total leucocyte count was 2,24,600/mm<sup>3</sup> with a lymphocyte count of 2,09,000/mm<sup>3</sup>, and platelet count was 1,29,000/mm<sup>3</sup>. Both direct and indirect Coomb's tests were negative. His immunoglobulin levels were evaluated, and all three (IgG, IgA, IgM) were within normal limits. Peripheral smear examination showed four smudge cells. On further evaluation, flow cytometry suggested bright positivity for CD19, CD20, and CD200 and moderate for CD5, and CD23. His ZAP 70 was negative (3.1%), and mutation analysis for 17p deletion was negative. Whole body PET-CT evaluation was done, which revealed bilateral cervical lymphadenopathy in all levels, most significant in the left posterior cervical region (2.1x1.2 cm, SUV max 8.32), bilateral supraclavicular lymph nodes, bilateral axillary lymph nodes (largest in the left axilla, 2.4x1.3 cm, SUV max 6.28) conglomerate abdominal lymph nodes (2.2x1.6 cm, SUV max 5.43), diffuse fatty infiltration of liver and splenomegaly (14.9 cm). His viral markers were negative. The size of his neck nodes increased while he was being evaluated. He was then diagnosed with chronic lymphocytic

\* Corresponding author.

E-mail address: [dipanjan.panda@gmail.com](mailto:dipanjan.panda@gmail.com) (D. Panda).

leukaemia (CLL), RAI stage II. He was started on Tab. Ibrutinib 420 mg once daily abd was routinely followed up with blood investigations and clinical examination. On a follow-up visit, after 28 months of taking Tab. Ibrutinib, he complained of difficulty in walking and decreased sensation in both feet. On examination, Romberg test was negative, bilateral ankle reflexes were weak, a light touch sensation was absent over the left sole and lateral aspect of the leg, pain and temperature sensations were intact, and joint position sense was present. An evaluation to rule out metabolic causes of paraesthesia was carried out. However, his blood sugar level, including HbA1c, was within normal limits; vitamin D level was in the normal range, serum folate level was 3.9 ng/ml, and serum vitamin B12 level was 234 pg/ml. He did not give a positive history of alcohol intake or smoking. A PET-CT scan was done for disease assessment, and the patient was in complete remission.

after one month. On his follow-up visit, symptoms were improved, and hence based on the history and clinical evaluation, a diagnosis of Ibrutinib-induced neuropathy was established. Currently, the patient is on observation as his disease is in remission.

**3. Discussion**

Chemotherapeutics agents act upon peripheral nervous system (PNS) structures to produce neuropathy, axonopathy or myelinopathy responsible for CIPN.<sup>4</sup> The usual presentation of CIPN is a “glove and stocking” pattern, mainly in the feet and hands, as long nerves are more susceptible to CIPN. Patients may experience various symptoms, including paraesthesia, dysesthesia, allodynia, hyperalgesia, hypoalgesia or pain that is burning, shooting or electric-shock-like sensation.<sup>5</sup> Apart from chemotherapeutic agents, other etiological factors for CIPN include age, comorbid conditions like diabetes that can potentially cause nerve damage and the use of alcohol.<sup>6</sup> Ibrutinib is the BTK inhibitor approved for treating chronic lymphocytic leukaemia (CLL)/small lymphocytic leukaemia (SLL). It has oral bioavailability and binds irreversibly to BTK.<sup>7</sup> The recommended dosage of Oral Tab. ibrutinib for CLL is 420 mg until disease progression or intolerance by the patient.<sup>8</sup> Some common toxicities documented for discontinuation of treatment included arthralgias, atrial fibrillation, cytopenia, pneumonitis, bleeding and diarrhoea.<sup>8</sup> In a retrospective series of CLL patients (n = 616) treated with Tab. ibrutinib, the discontinuation rate was 41% due to toxicity rather than disease progression.<sup>9</sup> After an extensive literature search, only two cases were reported to have ibrutinib-induced neuropathy. Supernova A.N. et al.<sup>10</sup> reported ibrutinib-induced peripheral neuropathy after five months of therapy, and Comert et al.<sup>11</sup> reported a similar side effect profile of neuropathy after ten months of Ibrutinib treatment.

**4. Conclusion**

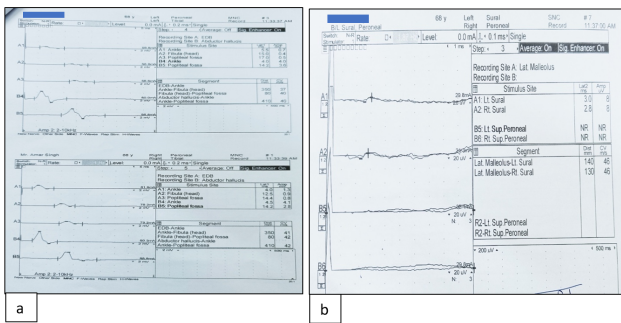
The case being reported is a male in his seventh decade with no prior comorbidities, diagnosed with CLL experiencing a unique side effect of Tab. Ibrutinib that is neuropathy. To the best of our knowledge, till now only two cases have been reported with this novel side effect. It is being presented to clinicians that one should be aware of all the potential side effects of the drug. Awareness regarding novel side effects is vital to avoid misdiagnosis and complications.

**5. Source of Funding**

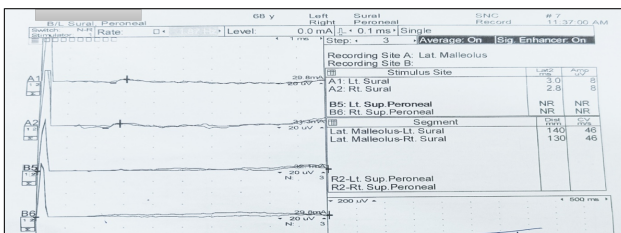
None.

**6. Conflict of Interest**

None.



**Fig. 1: a & b: Nerve conduction velocity test**




**Fig. 2: Nerve conduction velocity test of sural and peroneal nerve**

Nerve conduction studies were carried out for bilateral lower limbs and revealed low amplitude CMAPs (compound muscle action potential) in foot muscles, 90.7 mv in extensor digitorum brevis (EDB), and four mv in Abductor hallucis (AHB) with average motor nerve conduction velocity (NCV) in Peroneal and Tibial nerves. Tibial F waves were at 61-63 ms. The Tibial H reflex was absent on the left and weakly elicited on the right. Sensory potentials in Superficial peroneal nerves were absent, and low amplitude 8mv in Sural nerves. Overall findings revealed length-dependent sensory-motor neuropathy (Figure 1). Given the progression of symptoms, he was advised to discontinue Tab Ibrutinib with a follow-up

## References

- Pachman DR, Barton DL, Watson JC, Loprinzi CL. Chemotherapy-induced peripheral neuropathy: prevention and treatment. *Clin Pharmacol Ther.* 2011;90(3):377–87.
- Gutiérrez-Gutiérrez G, Sereno M, Miralles A, Casado-Sáenz E, Gutiérrez-Rivas E. Chemotherapy-induced peripheral neuropathy: clinical features, diagnosis, prevention and treatment strategies. *Clin Transl Oncol.* 2010;12(2):81–91.
- Imbruvica. Imbruvica - Food and Drug Administration. Accessed: November 13, 2022. Available from: [https://www.accessdata.fda.gov/drugsatfda\\_docs/label/2015/205552s002lbl.pdf](https://www.accessdata.fda.gov/drugsatfda_docs/label/2015/205552s002lbl.pdf).
- Ocean AJ, Vahdat LT. Chemotherapy-induced peripheral neuropathy: pathogenesis and emerging therapies. *Support Care Cancer.* 2004;12(9):619–25.
- Boland BA, Sherry V, Polomano RC. Chemotherapy-induced peripheral neuropathy in cancer survivors. *Oncol Nurse Edn.* 2010;24(2):33–8.
- Windebank AJ, Grisold W. Chemotherapy-induced neuropathy. *J Peripher Nerv Syst.* 2008;13(1):27–46.
- Burger JA, Tedeschi A, Barr PM, Robak T, Owen C, Ghia P, et al. Ibrutinib as Initial Therapy for Patients with Chronic Lymphocytic Leukemia. *N Engl J Med.* 2015;373(25):2425–37.
- Imbruvica. European Medicines Agency; 2022. Available from: <https://www.ema.europa.eu/en/medicines/human/EPAR/imbruvica>.
- Mato AR, Nabhan C, Thompson MC, Lamanna N, Brander DM, Hill B. Toxicities and outcomes of 616 ibrutinib-treated patients in the United States: A real-world analysis. *Haematologica.* 2018;103(5):874–9.
- Suponeva NA, Grishina DA, Piradov MA. Ibrutinib-induced chronic demyelinating polyneuropathy in a 65-year-old man with chronic lymphoid leucosis: A clinical case. *Rom J Neurol.* 2018;17(1):41–9.
- Cömert P. Ibrutinib-induced polyneuropathy: A case report. *J Oncol Pharm Pract.* 2020;26(6):1501–4.

## Author biography

**Disha Tiwari**, Registrar  <https://orcid.org/0000-0003-1262-9837>

**Dipanjan Panda**, Senior Consultant

**Atul Sharma**, Senior Consultant

**Dewesh Kishan**, Registrar

**Cite this article:** Tiwari D, Panda D, Sharma A, Kishan D. Ibrutinib induced sensorimotor neuropathy: A novel side effect. *Indian J Pathol Oncol* 2023;10(2):174-176.