

Content available at: <https://www.ipinnovative.com/open-access-journals>

Indian Journal of Pathology and Oncology

Journal homepage: www.ijpo.co.in

Case Report

Acrokeratosis verruciformis of Hopf: A rare case report

Sujata Panda¹, Deepika Sahu², Shilpa Padhi², Shushruta Mohanty^{2,*}

¹Dept. of Pathology, Nidan Diagnostic Centre, Berhampur, Odisha, India

²Dept. of Pathology, M.K.C.G Medical College and Hospital, Berhampur, Odisha, India



ARTICLE INFO

Article history:

Received 24-11-2022

Accepted 15-12-2022

Available online 16-03-2023

Keywords:

Acrokeratosis verruciformis of Hopf

Churchspires

Genodermatosis

Tretinoin

ABSTRACT

Acrokeratosis verruciformis of Hopf (AKV) is a rare cutaneous autosomal dominant genodermatosis described by Hopf in 1931. It usually presents at birth or may appear as late as 5th decade of life. It is characterized by multiple hyperkeratotic, verrucous papules/plaques to multiple planar wart like lesions on dorsal aspects of hand and feet. Due to rarity of the case, we present a case of AKV in a 60-year-old male that was diagnosed on histopathology. We the authors have attempted to describe the histological features of AKV with differential diagnosis of these lesions through review of literature.

This is an Open Access (OA) journal, and articles are distributed under the terms of the [Creative Commons Attribution-NonCommercial-ShareAlike 4.0 License](https://creativecommons.org/licenses/by-nc-sa/4.0/), which allows others to remix, tweak, and build upon the work non-commercially, as long as appropriate credit is given and the new creations are licensed under the identical terms.

For reprints contact: reprint@ipinnovative.com

1. Introduction

Acrokeratosis verruciformis of Hopf (AKV) is a rare cutaneous autosomal dominant genodermatosis (inherited genetic skin disorder) described by Hopf in 1931.¹ It affects both sexes equally with no gender predilection.² There are two types of AKV based on the age of onset. They are classical AKV which is seen in childhood and sporadic AKV seen in older age group around 5th decade.³ Clinical presentation may vary from multiple hyperkeratotic skin coloured verrucous papules/plaques of hand and feet to multiple planar wart like lesions on hands and feet that may extend to knees, elbows and forearm.^{1,4}

2. Case Report

A 60-year-old male presented to Dermatology department with chief complaints of itchy hyperkeratotic papular/plaque lesions around the right ankle since 8 years. The lesions were hyperpigmented and had exacerbations on and off (Figure 1 a, b). Leukonychia, thickened nail plates

and longitudinal nail ridges and nicks are other typical nail changes that are frequently reported in association with AKV.^{5,6} Our case showed nail plate thickening with longitudinal nail ridges. (Figure 1 c) There was no history of similar complaints in the family. Histopathology of the lesion showed epidermis showing hyperkeratosis, acanthosis, hypergranulosis with papillomatous elevation resembling “church spires”. The reteridges are elongated and extend to a uniform level with dermis appearing unremarkable with normal fibrocollagenous tissues and adnexal structures (Figure 2 a,b,c). Thus corroborating the clinical presentation and characteristics histopathology findings diagnosis of Acrokeratosis Verruciformis of Hopf was rendered.

* Corresponding author.

E-mail address: sushruta.mohanty@gmail.com (S. Mohanty).

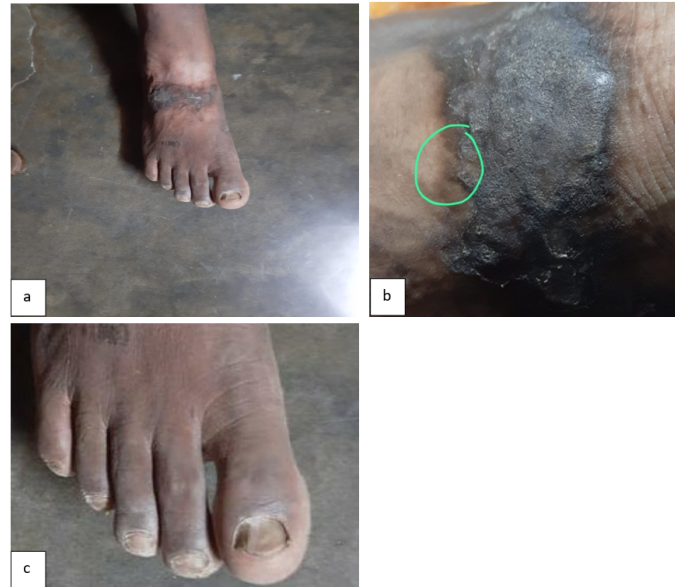

Fig. 1: a,b): Multiple hyperkeratotic, verrucous papules/plaque like lesions on dorsal aspects of hand and feet; **c):** Thickening of the nail plate with longitudinal ridges seen in the big toe

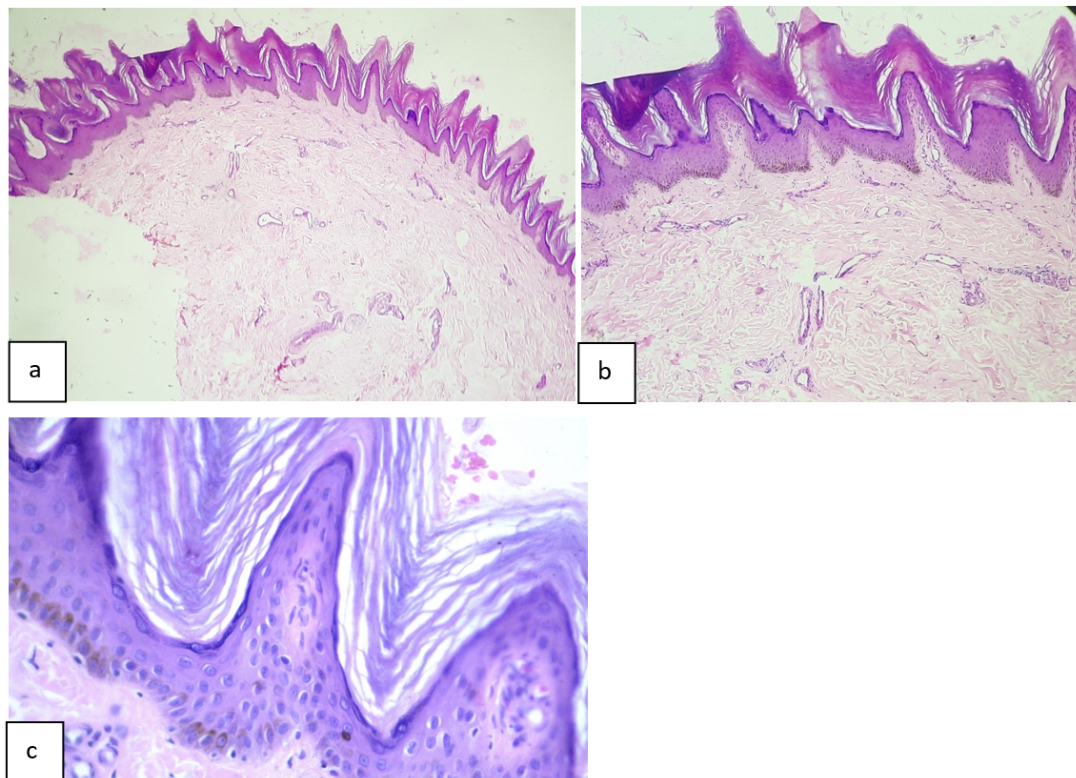


Fig. 2: a): Scanner view: 40x Showing Hyperkeratosis, acanthosis and Papillomatosis (church spire like elevation); **b):** Low power view 100X- Showing acanthosis, hyperkeratosis, hypergranulosis and papillomatosis Dermis appearing unremarkable; **c):** High power 400x- showing characteristics papillomatosis (Church spire like elevations)

3. Discussion

Acrokeratitis veruciformis of Hopf (AKV) is an autosomal dominant genetic disorder of unknown etiology. The disease follows a chronic course with no spontaneous remission. It has an autosomal dominant pattern of inheritance with incomplete penetrance that explains the difficulty of finding similar cases in the family. Clinically AKV manifests as flat topped, polygonal, papules and verrucous plaques and this clinical presentation led us to consider verruca vulgaris, Darriers disease, seborrheic keratosis and epidermodysplasia veruciformis as differential diagnosis. The disease doesn't affect the sebaceous areas –frontal scalp, flexures or oral mucosa.⁵ Diagnosis of AKV however is clinched by characteristic histopathological features that include acanthosis, hyperkeratosis, hypergranulosis without parakeratosis and papillomatosis (circumscribed epidermal elevations known as church spires). Other differentials were ruled out on basis of their histopathological findings that was not seen in our case. Darrier's disease shows a suprabasal acantholysis with corps ronds,⁷ verruca vulgaris shows papillomatous epidermis, hypergranulosis, inward bending of rete ridges with coarse keratohyaline granules and koilocytes,⁸ Epidermodysplasia veruciformis shows hyperkeratosis and distinct intracytoplasmic inclusion bodies in the epidermis.⁹ Absence of horn cyst and basaloid cells ruled out the possibility of seborrheic keratosis.³

Review of literatures have reported that AKV as a variant of Darriers disease due to similarities in clinical presentation and inheritance pattern. Although the exact etiology is not known it is postulated that P602L mutation in the ATP2A2 gene that is allelic to Darriers disease on chromosome 12q24 can cause AKV.¹⁰ The mutation restricts the calcium in the sarcoplasmic reticulum calcium ATPase and cause hyperkeratinisation that leads to genodermatosis.¹¹ Other studies postulated that rather than ATP2A2 mutation, missense mutation in other genes were responsible for AKV. It was also stated that both occur in the same patient,^{12,13} however Darriers disease shows dyskeratotic cells, has a predilection for sebaceous areas and affects oral mucosa which goes against the diagnosis of AKV.

There are various treatment modalities for AKV as described in literatures, however no intervention is required until the patient is symptomatic. Although superficial ablation is effective to treat AKV, it is discouraged due to high recurrence rate. Certain studies have reported no improvement with the use of keratolytics such as salicylic acid and topical corticosteroids with cryotherapy.^{14,15} However, with the Use of oral retinoids, acitretin showed marked improvement.¹⁶ Our patient was given 0.05% tritenoin that showed improvement and is on continuous follow up with no recurrence since 2 months.

4. Conclusion

Very few cases of AKV have been reported in Indian context, and the disease is reported because of its rarity.

AKV of Hopf may transform to squamous cell carcinoma as reported in few literatures, therefore dermatologist should educate the patient as well as monitor the patients routinely from time to time. Additional case reports of AKV will help to recognize the risk factors in this condition and genetic studies of sporadic cases of AKV should be conducted for better management of the patient.

5. Source of Funding

None.

6. Conflict of Interest

None.

References


1. Nair PA. Acrokeratosis verruciformis of hopf along lines of Blaschko. *Indian J Dermatol.* 2013;58(5):406.
2. Agrawal SN, Jane SD, Rawal AA. Acrokeratosis verruciformis of Hopf in family. *Indian Dermatol Online J.* 2014;5(1):17–9.
3. Rege VI, Jane SD, Rawal AA. Acrokeratosis verruciformis of HOPF. *Indian J Dermatol Venereol Leprol.* 1992;58:95–8.
4. Dhitavat J, Macfarlane S, Dode L, Sakuntabhai N, Sakuntabhai A, MacSween R, et al. Acrokeratosis verruciformis of Hopf is caused by mutation in ATP2A2: evidence that it is allelic to Darier's disease. *J Invest Dermatol.* 2003;120(2):229–32.
5. Ormond DTS, Viana SS, Vitral EAO, Pereira CAC, Carvalho MTF. Acroceratose verruciforme de Hopf: relato de caso. *An Bras Dermatol.* 1998;73:25–7.
6. Santos OLR, Cardoso ICL, Cardoso AMF, Filho RS. Acroceratose verruciforme de Hopf. *An Bras Dermatol.* 1995;70:17–9.
7. Bang CH, Kim HS, Park YM, Kim HO, Lee JY. Nonfamilial acrokeratosis verruciformis of Hopf. *Ann Dermatol.* 2011;23(1):61–3.
8. Swetha P, Supriya NA, Kumar GRN. Characterization of different verrucous mucosal lesions. *Indian J Dent Res.* 2013;24(5):642–4.
9. Yoshida R, Kato T, Kawase M, Honda M, Mitsuishi T. Two sisters reveal autosomal recessive inheritance of epidermodysplasia verruciformis: a case report. *BMC Dermatol.* 2014;14(1):12.
10. Vora RV, Diwan NG, Jivani NB, Singhal RR, Gandhi SS, . Macular variant of acrokeratosis verruciformis of Hopf. *Med J DY Patil Univ.* 2017;10(2):195–7.
11. Williams GM, Lincoln M. Acrokeratosis Verruciformis of Hopf. Treasure Island (FL): StatPearls Publishing; 2019.
12. Matsumoto A, Gregory N, Rady PL. HPV-17 Infection in Darier Disease With Acrokeratosis Verrucosis of Hopf. *Am J Dermatopathol.* 2017;39(5):370–3.
13. Harman M, Durdu M, İbiloğlu I. Acrokeratosis verruciformis of Hopf exhibiting Darier disease-like cytological features. *Clin Exp Dermatol.* 2016;41(7):761–3.
14. Patel N, Diwan N, Nair PA. Nonfamilial acrokeratosis verruciformis of Hopf. *Indian Dermatol Online J.* 2015;6(2):110–2.
15. deAndrade T, daSilva GV, Silva TMP, Pinto A, Nunes AJF. Acrokeratosis verruciformis of Hopf - Case report. *An Bras Dermatol.* 2016;91(5):639–41.
16. Serarslan G, Balci DD, Homan S. Acitretin treatment in acrokeratosis verruciformis of Hopf. *J Dermatolog Treat.* 2007;18(2):123–5.

Author biography

Sujata Panda, Consultant Pathologist

Deepika Sahu, Senior Resident

Shilpa Padhi, Senior Resident

Shushruta Mohanty, Assistant Professor  <https://orcid.org/0000-0002-3122-6892>

Cite this article: Panda S, Sahu D, Padhi S, Mohanty S. Acrokeratosis verruciformis of Hopf: A rare case report. *Indian J Pathol Oncol* 2023;10(1):108-111.