



Case Report

Primary renal leiomyosarcoma: A rare case report

Sumaira Siddiqui^{1,*}, Saba Siddiqui², Syed Mohd Ahmad³

¹AIG Hospital, Hyderabad, Telangana, India

²BCM Hospital, Lucknow, Uttar Pradesh, India

³Dept. of ENT, Hind Medical College, Lucknow, Uttar Pradesh, India



ARTICLE INFO

Article history:

Received 06-12-2022

Accepted 15-12-2022

Available online 16-03-2023

Keywords:

Leiomyosarcoma

Radical nephrectomy

Renal

ABSTRACT

Primary leiomyosarcoma of kidney is rare with aggressive behavior. A 61 year female presented with complaint of right flank pain since 2 months. Radiological investigation show mass in mid and lower pole of right kidney for which she underwent radical nephrectomy. Microscopy reveal malignant mesenchymal tumor and IHC confirmed the diagnosis of renal leiomyosarcoma with Caldesmon, smooth muscle actin [SMA] positive and Ki67% - 25%. Complete resection done and on follow up patient is doing well.

This is an Open Access (OA) journal, and articles are distributed under the terms of the [Creative Commons Attribution-NonCommercial-ShareAlike 4.0 License](https://creativecommons.org/licenses/by-nc-sa/4.0/), which allows others to remix, tweak, and build upon the work non-commercially, as long as appropriate credit is given and the new creations are licensed under the identical terms.

For reprints contact: reprint@ipinnovative.com

1. Introduction

Primary leiomyosarcoma [LMS] of the kidney is a rare tumor with an aggressive behaviour. It constitutes 1 – 2% of all malignant renal tumors.¹ It does not have any characteristic diagnostic feature clinically and radiologically, therefore frequently diagnosed on histopathology. Renal leiomyosarcomas can arise from the smooth muscle fibres of the renal pelvis and the renal capsule or the renal vessels, the latter being more common.² Renal sarcoma is less common, but more lethal than any other sarcoma of genitourinary site.

2. Case Report

A 61 yrs old female patient presented with complaints of right flank pain since 2 months. No significant personal history. Hb 7.9 gm/dl, TLC 9,100 cells/cumm, serum creatinine 1.1mg/dl. All systematic examinations were within normal limit and per abdomen show soft bowel sounds with Right flank fullness.

CECT abdomen defined large mass lesion in the right side of retroperitoneum with broad based towards anterior cortex of mid & lower pole region of right kidney, completely encasing renal pelvis and pelvic ureteric junction [PUJ] region, compressing over 2nd part of duodenum and inferior vena cava [IVC], left renal vein is encased by mass lesion; no obvious involvement of ipsilateral adrenal gland- likely renal cell neoplasm, exophytic gastrointestinal stromal tumour [GIST] arising from 2nd part of duodenum.

HRCT chest showed fibrotic lesions seen in right apical region suggestive of Koch' sequelae.

PET- CT scan showed large enhancing soft tissue mass arising from mid and lower pole of right kidney, effect on inferior vena cava [IVC], abutting right psoas muscle as described- primary.

Gross: Received a right nephrectomy specimen measuring 20 x 12 x 9cm and ureter measuring 0.3 cm. Outer surface is nodular. Cut section shows tumor measuring 18x13x9cm with white tan appearance and area of necrosis and hemorrhage and tumour is adherent to capsule. Distance of tumor from ureteric cut margin is 0.3

* Corresponding author.

E-mail address: sumiimc011@gmail.com (S. Siddiqui).

and 0.2cm from renal sinus.

Multiple sections studied from: Tumour are arranged in interlacing fascicles and bundles of malignant spindle cells with variable cellularity with elongated vesicular nucleus and scant eosinophilic cytoplasm. Marked nuclear atypia. Tumour giant cell noted. 20/10HPF mitosis seen. Large area of necrosis seen. 16 reactive lymph node identified. Inked margin, Perinephric fat, Gerota fascia are free from tumor. Possibility of malignant mesenchymal tumor, undifferentiated renal cell carcinoma are considered. IHC shows SMA, Desmin, Caldesmon positive in spindle cell and CD 34 highlight blood vessel with 25% of Ki-67%. So final diagnosis is renal leiomyosarcoma [p T4 pN0]. Complete resection done and on follow up patient is doing well.

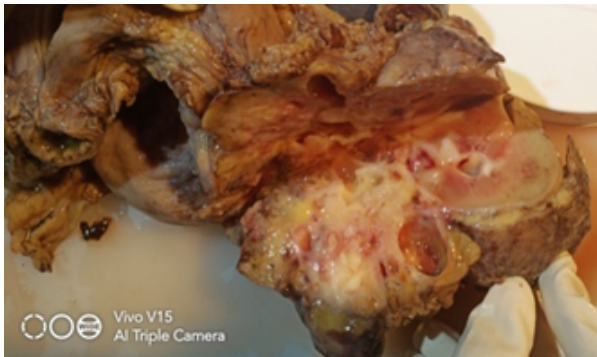

Fig. 1: Gross image: white tan tumour with areas of haemorrhage and necrosis

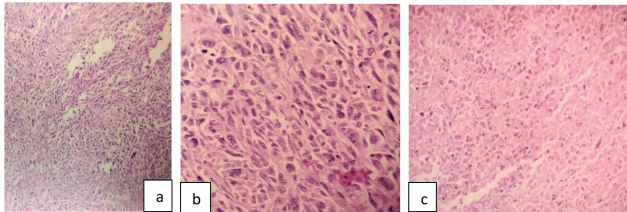


Fig. 2: a): Section shows tumour arranged in fascicles and bundles of malignant spindle cell {4x}; b): Higher magnification {40x}; c): Section showing area of necrosis

3. Discussion

Adult primary renal sarcomas of rare tumor types, accounts for approximately 1 - 2% of all primary renal tumors. Of these, Leiomyosarcoma is the most common histological subtype of renal sarcoma, accounts for 50% - 60% of later.^{3,4} These tumors can occur at any age and are more common in women aged 40-60 years.⁵ The incidence observed in females may be related to the deletion of one or more genes on the X chromosome, which evades X chromosome inactivation⁶ in addition, cases have also been

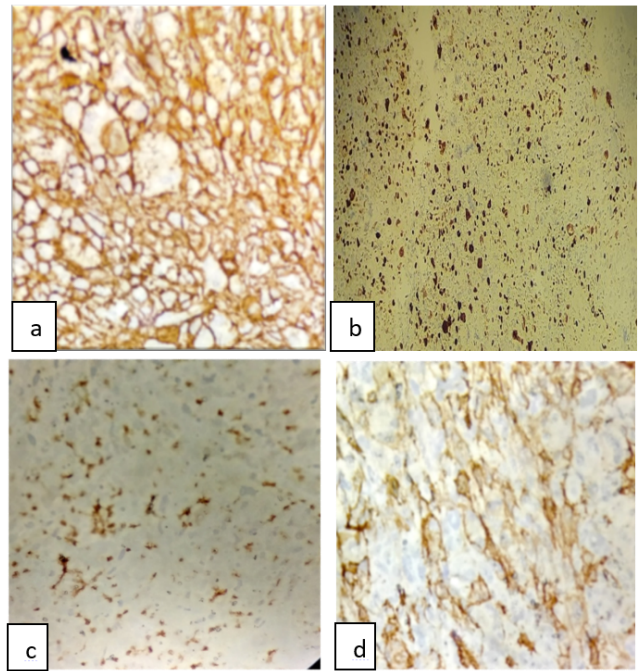


Fig. 3: a): Caldesmon positive in spindle cell; b): Ki -67% : 25%; c): SMA and d): Desmin positive in spindle cells

reported with the EBV virus infection, AIDS and after organ transplantation.⁷

The incidence of the primary renal leiomyosarcoma increases with the age of the patient. This tumor was found to be more common in females than in males and more common in the right kidney than in the left kidney.⁸ Preponderance of renal leiomyosarcomas in females and more frequent after the fifth decade of life.^{9,10} Leiomyosarcoma is a rare and aggressive smooth muscle cell tumor that can arise from different anatomic sites. They have a tendency to recur locally and metastasize early via the haematogenous route.³

Clinical features of renal Leiomyosarcoma are very similar to more common renal malignancies which consist of haematuria, flank pain, progressive weight loss, and an abdominal mass lesion. As the tumor increases in size, it produces symptoms such as lumbar pain and haematuria and a palpable mass.¹¹

It is a very rare entity other differential diagnosis of renal Leiomyosarcoma to be ruled out. Sarcomatoid variant of renal cell carcinoma have malignant epithelial cell and lacks fascicular architecture with IHC positive for keratin and negative for actin. Epithelioid variant of renal angiomyolipoma which shows mature adipose tissue with thick hyalinised blood vessel in histopathology and IHC is positive for HMB 45. And renal synovial sarcoma with three histological subtypes monophasic {spindle cell}, biphasic {both spindle and epithelial cell} and poorly differentiated. IHC are positive for CD99, vimentin bcl2,

EMA, CD 56 and translocation t [X;18][p11.2;q11.2].¹² Hence, immunohistochemistry is an important investigation for the evaluation of such tumors to avoid the wrong diagnosis.¹³

According to the French Federation of Cancer Center classification system, grades are assigned based on tumor differentiation, tumor necrosis and mitotic rates. The current treatment of choice for renal Leiomyosarcoma is radical nephrectomy.¹⁴ Treatment approach is based upon grade and histology. Neoadjuvant radiotherapy is generally administered in R0, chemotherapy indicated in R2 resection. Grossly incomplete resection, intraoperative radiation therapy results in excellent local control and survival for patient.

4. Conclusion

Prognosis of LMS is poor so early diagnosis and radical nephrectomy can prolong patient life. Life expectancy of high grade primary LMS is poor as compared to low grade LMS. Prognostic factors for soft tissue sarcomas include stage, histological subtype, grade, age and gender of patient. Surgery is the main treatment modality. However, chemotherapy and radiotherapy are also recommended considering the aggressive behaviour of neoplasm.

5. Source of Funding

None.

6. Conflict of Interest

None.

References

- Ding Y, Quan C. Primary renal leiomyosarcoma. *J Coll Physicians Surg Pak*. 2021;30(6):725–7.
- Djiwa T, Sabi KA, Simgban P, Bombonne M, Sama BM, Tchaou M, et al. Renal Leiomyosarcoma, a Rare Presentation. *J Kidney Cancer VHL*. 2022;9(1):51–4.
- Venkatesh K, Saini M, Niveditha SR, Krishnagiri C, Babu S. Primary leiomyosarcoma of the kidney. *Patholog Res Int*. 2010;2010. doi:10.4061/2010/652398.
- Tajima S, Waki M, Fukuyama M. Pleomorphic leiomyosarcoma with a dedifferentiation-like appearance in the kidney: Case report and literature review. *Med Mol Morphol*. 2016;49(4):238–42.
- Ozturk H. High-grade primary renal leiomyosarcoma. *Int Braz J Urol*. 2015;41(2):304–11.
- Kwon YS, Salmasi A, Han CS, Hon JD, Singer EA. Renal leiomyosarcoma: Case report and review of the literature. *World J Nephrol Urol*. 2015;4(2):213–7.
- Miettinen M. Smooth muscle tumors of soft tissue and non-uterine viscera: biology and prognosis. *Mod Pathol*. 2014;27(Suppl 1):17–29.
- Beardo P, Ledo MJ, Luis R. Renal leiomyosarcoma. *Rare Tumors*. 2013;5:e42.
- Farrow GM, Harrison EG, Utz DC, Remine WH. Sarcomas and sarcomatoid and mixed malignant tumors of the kidney in adults. *Cancer*. 1968;22(3):545–50.
- Dhamne SA, Gadgil NM, Padmanabhan A. Leiomyosarcoma of the renal pelvis. *Indian J Pathol Microbiol*. 2009;52(4):549–51.
- Valery JR, Tan W, Cortese C. Renal leiomyosarcoma: a diagnostic challenge. *Case Rep Oncol Med*. 2013;2013:459282. doi:10.1155/2013/459282.
- Lohani R, Singh V, Singhai A, Singla S, Agarwal MK. Primary synovial sarcoma of kidney: a rare case report with review of literature. *Afr J Urol*. 2022;28(1):1–5.
- Miller JS, Zhou M, Brimo F, Guo CC, Epstein JI. Primary leiomyosarcoma of the kidney: A clinicopathologic study of 27 cases. *Am J Surg Pathol*. 2010;34(2):238–42.
- Zafar R, Manthri S, Shurbaji MS. Renal Leiomyosarcoma. Treasure Island (FL): StatPearls Publishing; 2022.

Author biography

Sumaira Siddiqui, Fellowship in Surgical and Transplant Pathology

Saba Siddiqui, Consultant Obstetrician and Gynecologist

Syed Mohd Ahmad, Associate Professor

Cite this article: Siddiqui S, Siddiqui S, Ahmad SM. Primary renal leiomyosarcoma: A rare case report. *Indian J Pathol Oncol* 2023;10(1):83-85.