

Content available at: <https://www.ipinnovative.com/open-access-journals>

Indian Journal of Pathology and Oncology

Journal homepage: www.ijpo.co.in

Case Series

Giant schwannoma masquerading as other soft tissue tumors: A series of three cases

Neelam Sood¹, Siddharth Sharma^{1,*}¹Dept. Pathology and Lab Medicine, Deen Dayal Upadhyay Hospital, New Delhi, India

ARTICLE INFO

Article history:

Received 20-05-2022

Accepted 29-10-2022

Available online 16-03-2023

Keywords:

Giant schwannoma

Paravertebral

Scalp

Thigh

Immunohistochemistry

ABSTRACT

Introduction: Schwannoma is a benign peripheral nerve sheath tumor. It commonly occurs in head and neck region, upper extremities and dorsolumbar spine. The giant schwannoma as such is a rare occurring tumor. We present a series of three cases of giant schwannoma in unusual locations, masquerading as other soft tissue tumors.

Case Series: Case 1: A 40-year-old male presented with a large exophytic ulcerated growth on his left thigh. The lesion was deep dermal in location. It was well circumscribed, partially encapsulated with extensive areas of hemorrhage and cystic change. Histopathology and immunohistochemistry (IHC) revealed the diagnosis of Benign Schwannoma with ancient changes.

Case 2: A 30-year-old woman presented with mid back ache and a mass in paravertebral location at T8 to T10 levels from last 2 years. The lesion was dermal in location. It was well circumscribed, partially encapsulated with extensive areas of hemorrhage and cystic change. Histopathology and IHC confirmed the diagnosis of Schwannoma with ancient changes.

Case 3: A 24-year-old male, presented with a 6x6 cm lesion over the scalp. It was well circumscribed, partially encapsulated with solid and cystic areas. Histologically, it turned out to be a Schwannoma.

Conclusion: Giant schwannoma is a rare tumor which occasionally presents at unusual locations and poses a diagnostic challenge to both, the operating surgeon and the pathologist.

These lesions clinically may mimic dermatofibroma, dermatofibrosarcoma and even trichilemmal tumors. These cases are being presented for their unusual presentation.

This is an Open Access (OA) journal, and articles are distributed under the terms of the [Creative Commons Attribution-NonCommercial-ShareAlike 4.0 License](https://creativecommons.org/licenses/by-nc-sa/4.0/), which allows others to remix, tweak, and build upon the work non-commercially, as long as appropriate credit is given and the new creations are licensed under the identical terms.

For reprints contact: reprint@ipinnovative.com

1. Introduction

Schwannoma also referred to as neurilemmoma is a benign slow growing tumor of peripheral nerves arising from Schwann cells.¹ The tumor was first described by Verocay in 1908.² The schwannomas are generally deep-seated tumors and most commonly occurs in sensory nerves of extremities, head and neck region and also in dorso-lumbar spine.³ The giant schwannoma are rare tumors and are defined as tumors involving 2 or more adjacent spinal levels or the tumors that are >2.5 cm in the greatest dimension.⁴

The clinical presentation of schwannoma is non-specific and the patient develops local pain with pressure symptoms late in the course of the disease.^{5,6} The nonspecific presentation and unusual location at times poses a diagnostic challenge to both the clinician and the pathologist. Here we present a series of three such cases of Giant schwannomas with unusual presentation.

2. Case Series

2.1. Case 1

A 40-year-old male patient presented with an exophytic ulcerated, firm growth on posterior surface of his left thigh

* Corresponding author.

E-mail address: sidlogsin@gmail.com (S. Sharma).

(Figure 1 c) for 4 years. The swelling was insidious in onset, gradually became painful. Based on the presentation, the clinical diagnosis of Dermatofibrosarcoma protuberance was made. FNAC of the swelling showed scattered spindle cells and was inconclusive. Excision surgery with wide margins was performed.

Grossly, a 5x5x3.5cm skin covered, partly ulcerated mass with well circumscribed outline was identified. On cutting, it was encapsulated and showed haemorrhagic areas and cystic degeneration (Figure 1 d). Microscopically, the tumor showed a combination of cellular and hypocellular areas of proliferating spindle cells, with perivascular hyalinisation. In few areas, tumor cells showed degenerative nuclear atypia (Figure 1 a). There was foreign body reaction in surrounding dermis with ulcerated epidermis. Immunohistochemistry (IHC) was performed on formalin fixed, paraffin embedded sections. IHC with S-100 (Biocare, RTU, 15E2E2) gave strong positivity in tumor cells (Figure 1 b). However, Pan CK (Dako, RTU, AE1/AE3), CD34 (Biocare, RTU, QBEnd/10) Smooth muscle actin (SMA) (Biocare, RTU, 1A4), CD31, epithelial membrane antigen (EMA) (Biocare, RTU, Mc-5, IgG1) were negative. Ki-67 index (Biocare, RTU, Mc-5, IgG1) was low (3%). Based on these findings, the final diagnosis of Schwannoma with ancient changes was made.

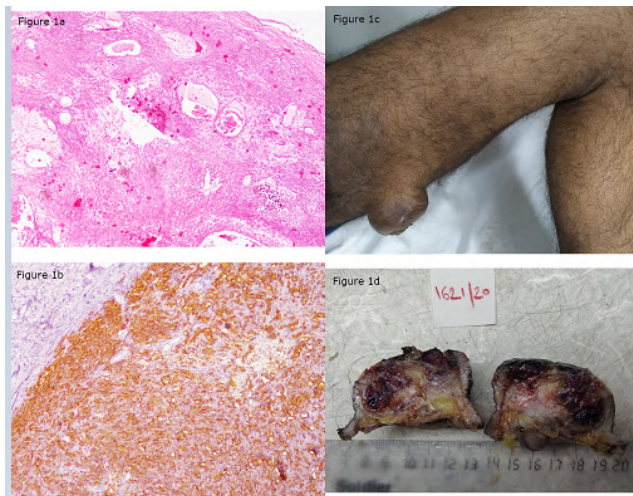


Fig. 1: Shows an ulcerated polypoidal lesion on posterior surface of thigh with hemorrhagic and cystic cut surface. H&E-stained section (40x) shows perivascular hyalinisation with Antoni A and B areas. IHC with S100 (10x) show intense positivity

Shows an ulcerated polypoidal lesion on posterior surface of thigh with hemorrhagic and cystic cut surface. H&E-stained section (40x) shows perivascular hyalinisation with Antoni A and B areas. IHC with S100 (10x) show intense positivity

2.2. Case 2

A 30-year-old female presented to surgery OPD with a globular mass on her back (Figure 2 b) from last 2 years. It was insidious in onset, initially asymptomatic, gradually increased in size and was associated with backache. There was no associated family history. The MRI showed large lesion with uneven density spanning between T8-T10 in paravertebral location. FNAC was indicative of a spindle cell lesion. Based on the presentation, preoperative diagnosis of dermatofibroma was made. The surgical excision was performed and 3.5cm x 3.5 cm mass with 1 cm skin free margins was removed and sent for histopathological examination.

Grossly, lesion was superficial with deep dermal extension, well circumscribed, partially encapsulated. The cut section showed extensive areas of hemorrhage and cystic change (Figure 2a).

On histopathology, a cellular tumor in dermis with both Antoni A and Antoni B areas having extensive hyalinization and Verocay bodies was seen. Marked perivascular hyalinization was present. Thick capsule is identified at most of the places (Figure 2 d). Immunohistochemistry showed strong expression for S-100 (Figure 2 c) with low Ki67 index (<5%). The final diagnosis of Schwannoma with ancient changes was made.

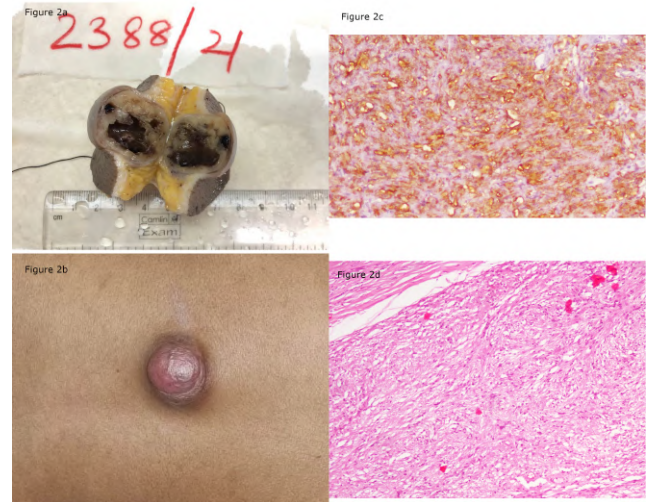


Fig. 2: Shows a paravertebral mass in a per operative picture. Grossly, a raised polypoidal encapsulated tumor with cystic and haemorrhagic cut surface. IHC with S-100 (40x) show intense positivity

2.3. Case 3

A 52-year-old male patient presented with a firm polypoidal scalp growth with stretched overlying skin (Figure 3a). The swelling was insidious in onset gradually increased in size over the duration of 6 years. Clinically, there

was mild tenderness over the swelling. The initial clinical impression was that of an appendageal/mesenchymal tumor. On excision, 6x6 cm well circumscribed and partially encapsulated mass was removed. The cut surface showed hemorrhagic and cystic areas.

Microscopically, an encapsulated tumor was identified in the subepidermal location with deep dermal extension. Tumor showed Antoni type A and B areas in addition to the well-formed Verocay bodies (Figure 3 b). Few areas with cystic degeneration were also noted (Figure 3 b). These findings pointed towards the diagnosis of Schwannoma. Strong expression of S100 (Figure 3 d) and low Ki67 confirmed the diagnosis of Schwannoma with ancient changes.

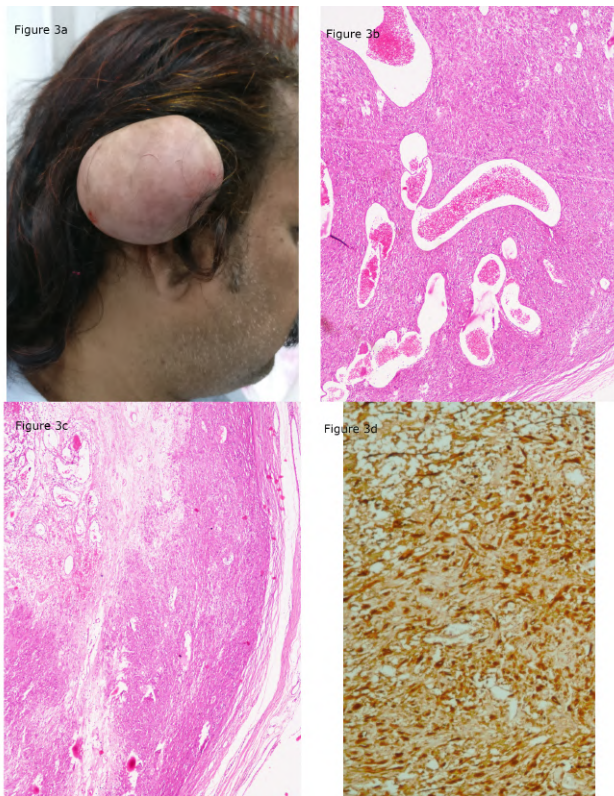


Fig. 3: Shows a polypoidal scalp mass. H&E-stained section (10x) shows classical Schwannoma morphological pattern with cystic degeneration and nuclear atypia. IHC with S-100 (40X) show positivity

3. Discussion

Schwannoma is a tumor originating from Schwann cells of peripheral nerve sheath.^{1,3,7} It has a wide range of presentation i.e., between 2nd to 5th decade of life with no sex predilection.^{3,7} Schwannoma occurs as a solitary mass and are usually deep-seated. These masses originate from nerve trunks. Rarely, they may be located in superficial cutaneous tissues which suggests that the tumor may have

been derived from a terminal cutaneous nerve.⁸ But, the terminal nerve/twig cannot always be demonstrated under the capsule unlike the ones arising from the large spinal nerves. Schwannomas can occur virtually at any site in the body but the most common being acoustic neuroma followed by those occurring at the flexor surface of limbs.⁶ There have been reports in the literature where authors have described schwannomas at various sites including few rare ones such as lateral border of tongue, axilla, paravertebral, scalp, vulva, orbit etc.^{5,6,9–12} Click or tap here to enter text.

Involvement of these sites is not something unexplainable since, neural tissue is present almost everywhere in the body. However, it is rarity of their occurrence at these sites that creates a diagnostic dilemma especially in minds of a surgeon. In cases 1st and 3rd, the clinical presentation favoured the diagnosis of giant appendageal tumor/inclusion cyst/giant dermatofibroma. In case 1 of our study, the lesion was ulceroproliferative so the diagnosis of Dermatofibrosarcoma protuberance was also considered. Cutaneous schwannomas are deep seated tumors and rarely present as polypoidal masses. These tumors originate from the subcutaneous fat or deep dermis.⁸ In our study, all three tumors presented as raised/polypoidal masses and two out of three cases also involved superficial dermis. The common superficially located tumors such as dermatofibroma, angiomatous lesions and trichilemmal tumors originate from superficial dermis and may present as raised masses. Histopathology is a rescuer in such cases.

Histopathologically, schwannoma shows a classical biphasic pattern of hypercellular Antoni type a areas and hypocellular myxoid Antoni type B areas composed of spindle cells arranged in fascicles. In addition, Verocay bodies (palisaded tumor nuclei around fibrillary processes) and large vessels are seen interspersed in these Antoni A areas.^{3,10} A close histological differential diagnosis of schwannoma is PEN (palisaded encapsulated neuroma). Unlike schwannoma, this tumor is incompletely encapsulated and does not show Antoni B areas.¹³ Schwannoma on the other hand lack axons which are present in PENs.⁸ Based on varied histomorphology Schwannomas are divided into cellular, ancient, plexiform, microcystic and epithelioid types.¹⁰ All three cases in our study showed ancient changes like perivascular hyalinization, haemorrhage, focal calcification and degenerative nuclear atypia.¹⁴ Cystic degeneration is common in large sized tumors. The reason for protrusion and cystic degeneration can be vascular insufficiency⁸ Click or tap here to enter text. Foreign body reaction was seen in case 2 of our study which could be in response to previous history of trauma. Kneitz et al.¹⁵ suggested that foreign body reaction leads to release of neurotrophic cytokines such as NGF (nerve growth factor) and FGF2 (fibroblast growth factor 2) which leads to proliferation

of Schwann cells and in turn leads to development of the tumor.

Schwannoma is a benign tumor but carries less than 1 percent risk of a malignant transformation.¹¹ In such tumors long history with microscopic evidence of cellular pleomorphism in a previously diagnosed benign lesion almost always suffice the diagnosis.¹⁶ Schwannoma with ancient changes also presents as a long-standing asymptomatic mass which starts to show symptoms after years.¹⁴ The symptoms in such tumors are due to compression of the underlying nerve.⁵ These tumors when present on the exposed surface, sometimes get infected and ulcerate. Such ulcerated lesions especially with ancient changes can mimic a malignant neoplasm, as in case 1 of our study. Immunohistochemistry a helpful tool to tackle such cases. Tumor cells in schwannoma are S-100 positive owing to their neural origin.² Other spindle cell neoplasms such as peripheral nerve sheath tumors (PNSTs) and fibrous lesions must also be ruled out using IHC. To strike out common differentials following markers are usually used in conjunction with S100 and Ki67: CD34, CD56, CD-117(c-kit), neurofilament protein (NFP), epithelial membrane antigen (EMA) and SOX-10. In most benign cases Ki67 index is <5%. Recurrence of these tumors with a higher value of Ki67 index and SOX-10 positivity point towards malignant transformation.^{16,17}

4. Conclusion

Giant schwannoma is relatively rare tumor which occasionally presents at unusual locations. These lesions clinically may mimic dermatofibroma, dermatofibrosarcoma and even trichilemmal tumors. This becomes a big diagnostic challenge to both, the operating surgeon and the pathologist. Present study highlights the importance of IHC in Giant Schwannomas presenting in rare sites. IHC with S-100 and Ki67 index are reliable and useful markers in such cases. This study suggests that schwannoma must also be kept as a close differential in cases with a raised/polypoidal soft tissue masses in relatively rare sites.

5. Source of Funding

None.

6. Conflict of Interest

None.

References

- Helbing DL, Schulz A, Morrison H. Pathomechanisms in schwannoma development and progression. *Oncogene*. 2020;39(32):5421–9.
- Georgiev GP, Ananiev J, Slavchev SA. An unusual case of a giant schwannoma of the common peroneal nerve with duration of twenty years. *Curr Prob Cancer: Case Rep*. 2021;3:100061. doi:10.1016/j.cpcr.2021.100061.
- Hilton DA, Hanemann CO. Schwannomas and their pathogenesis. *Brain Pathol*. 2014;24(3):205–20.
- Mba SE, Dzowa M, Musara A, Kalangu K. Giant craniocervical junction schwannoma involving the hypoglossal nerve: case report. *Indonesian J Neurosurg*. 2019;2(2):33–7.
- Chen H, Xu Q, Zhan P, Liu Y, Dai M, Zhang B. Giant paravertebral schwannoma near the lumbar nerve roots with bone destruction: A case report. *Medicine (Baltimore)*. 2019;98(42):e17341.
- Örgüç Ş, Başara I, Özkarakaş P, Poğan T, Aydede H. Axillary schwannoma mimicking lymphadenopathy: Two different case reports. *Türk Klinikleri J Med Sci*. 2012;32(6):1737–41.
- Pilavaki M, Chourmouzi D, Kiziridou A, Skordalaki A, Zarampoukas T, Drevelengas A. Imaging of peripheral nerve sheath tumors with pathologic correlation: Pictorial review. *Eur J Radiol*. 2004;52(3):229–39.
- Abreu I, Roriz D, Rodrigues P, Moreira A, Marques C, Alves FC. Schwannoma of the tongue-A common tumour in a rare location: A case report. *Eur J Radiol Open*. 2017;4:1–3.
- Mohan KH, Manjunath H. Cutaneous schwannoma masquerading as trichilemmal cyst over scalp in a young male. *Indian J Dermatol*. 2013;58(5):407.
- Tan J, Chen J, Yang L. A Case of Vulvar Schwannoma Mimicking Epidermoid Cyst. *Case Rep Dermatol*. 2018;10(1):41–5.
- Feijó ED, Nery ACD, Caiado FR, Prehis AM, Limongi RM. Extraconal cystic schwannoma mimicking an orbital dermoid cyst. *Arq Bras Oftalmol*. 2016;79(4):258–60.
- Noh S, Do JE, Park JM, Jee H, Oh SH. Cutaneous schwannoma presented as a pedunculated protruding mass. *Ann Dermatol*. 2011;23(Suppl 2):S264–6.
- Carter JJ, Langman G, Orpin SD. A solitary painful papule on the ear. *Clin Exp Dermatol*. 2009;34(1):125–6.
- Lee YS, Kim JO, Park SE. Ancient schwannoma of the thigh mimicking a malignant tumour: A report of two cases, with emphasis on MRI findings. *Br J Radiol*. 2010;83(991):e154–7.
- Kneitz H, Weyandt G, Meissner C, Gebhart E, Bröcker EB. Dermal Schwannoma (Neurilemmoma): A Peculiar Foreign Body Reaction? *Am J Dermatopathol*. 2010;32(4):367–9.
- Bah AB, N'dri OD, Herbrecht A, Parker F. Malignant transformation of cranial nerve schwannoma after radiosurgery-case report. *J West Afr Coll Surg*. 2014;4(2):112–20.
- Sergheeraert J, Zachar D, Furon V, Khonsari RH, Ortonne N, Mauprivez C. Oral plexiform schwannoma: A case report and relevant immunohistochemical investigation. *SAGE Open Med Case Rep*. 2019;7. doi:10.1177/2050313X19838184.

Author biography

Neelam Sood, HOD & Consultant  <https://orcid.org/0000-0001-5965-5632>

Siddharth Sharma, Senior Resident  <https://orcid.org/0000-0003-1439-8892>

Cite this article: Sood N, Sharma S. Giant schwannoma masquerading as other soft tissue tumors: A series of three cases. *Indian J Pathol Oncol* 2023;10(1):56-59.