



## Case Report

# Liver biopsy changes in fatal COVID 19 patients in a tertiary care hospital

Aravinth Subramaniam<sup>1</sup>, Divya Gnanasekaran<sup>1,\*</sup>, Raghunath<sup>1</sup>, Dhivahar<sup>2</sup>

<sup>1</sup>Dept. of Pathology, GEM Hospital and Research Institute, Coimbatore, Tamil Nadu, India

<sup>2</sup>Dept. of Intensive Care Medicine, GEM Hospital and Research Institute, Coimbatore, Tamil Nadu, India



### ARTICLE INFO

#### Article history:

Received 22-11-2021

Accepted 29-01-2022

Available online 14-02-2022

#### Keywords:

COVID 19

Liver biopsy

Fatal

### ABSTRACT

COVID 19 is an ongoing pandemic that has horrified the entire globe. Aftermath of 2<sup>nd</sup> wave is still a nightmare to many. Albeit not so sure of what's in store, people in medical fraternity try their best to continue to study this virus, its effect and consequences in various organs. Lung being the prime victim followed by the heart has many scientific studies to substantiate its damage. Liver is a sensitive organ and it too has got affected directly by the virus or due to the drugs given irrespective of the ongoing previous liver disease if so any. We are a tertiary hospital in the field of gastrointestinal surgery. Hence we did a study on the patients who died due to COVID 19 associated diseases via a biopsy to understand more microscopically about the implication the dreadful virus has caused.

This is an Open Access (OA) journal, and articles are distributed under the terms of the [Creative Commons Attribution-NonCommercial-ShareAlike 4.0 License](https://creativecommons.org/licenses/by-nc-sa/4.0/), which allows others to remix, tweak, and build upon the work non-commercially, as long as appropriate credit is given and the new creations are licensed under the identical terms.

For reprints contact: [reprint@ipinnovative.com](mailto:reprint@ipinnovative.com)

## 1. Introduction

The current pandemic COVID 19 has shaken the entire world in a disastrous way. According to the available literature and clinical evidence, lung is the prime organ to get involved and affected in covid 19 patients. Hepatic involvement is under study and only little evidence is available to know and compare. With those available data, liver shows varieties of findings depending on patient's previous liver disease if so any. There are many potential causes for liver injury during SARS-CoV-2 infection, including exacerbation of underlying chronic liver disease; drug injury; direct viral infection of the liver; and secondary injury to the liver caused by complications of illness, such cytokine-mediated injury and shock.<sup>1</sup> Hence we are trying to study the changes observed in the liver through a biopsy sample from patients who died due to covid 19 in our tertiary care hospital.

## 2. Materials and Methods

After getting a written informed consent from died patient's attendees, liver biopsy was performed and sample was sent to the histopathology department for further study. All fatal patients in the covid ward/ICU are included in this study.

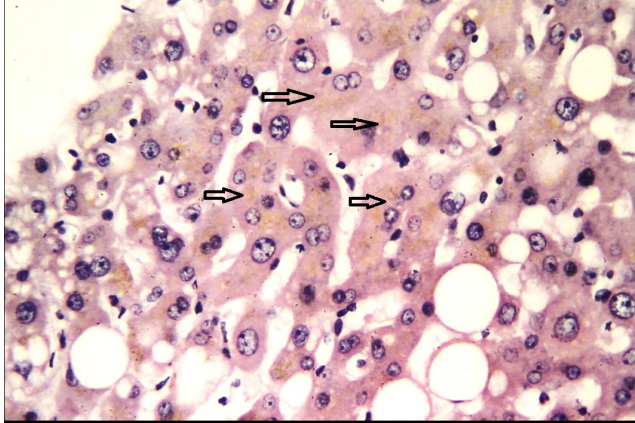
A template was made and our Histopathological findings along with clinical details are noted accordingly.

## 3. Results

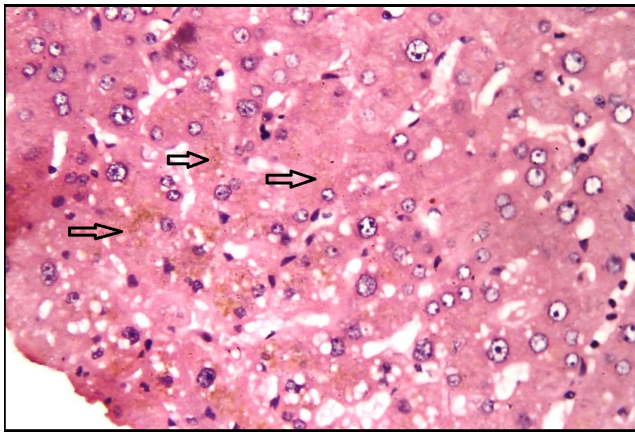
From the biopsies collected the core biopsies were interpreted under the following parameters (Table 1). The template is attached below in which the interpretation was made. Out of 23 specimens, our predominant findings included lobular cholestasis (Figures 1 and 2) which was seen in 10 cases and macrovesicular steatosis (Figure 3) that was seen in 7 cases. 3 cases had fibrosis (Figure 4) and 1 with 10% microvesicular steatosis (Figure 5). 3 biopsies were inadequate for opinion.

\* Corresponding author.

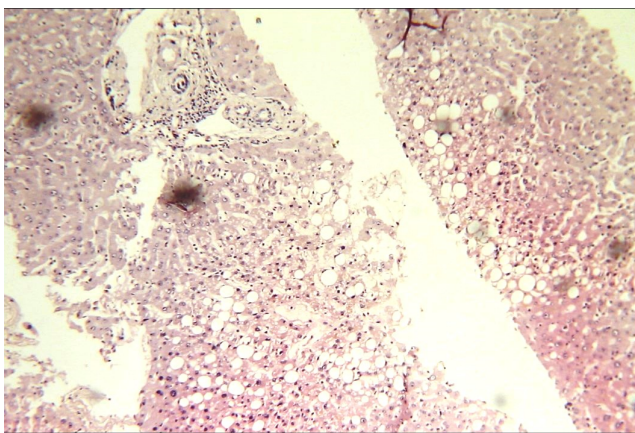
E-mail address: [divyajayamurugan@yahoo.in](mailto:divyajayamurugan@yahoo.in) (D. Gnanasekaran).



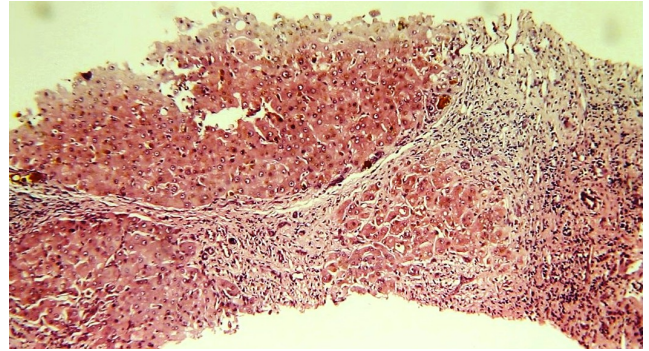
**Fig. 1:** Cholestasis



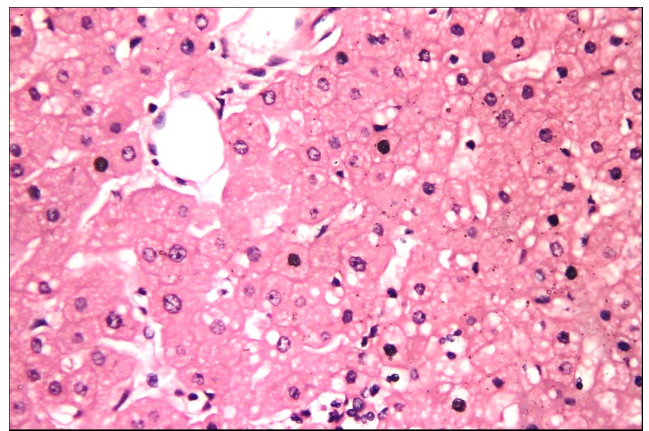
**Fig. 2:** Cholestasis



**Fig. 3:** Macrovesicular steatosis



**Fig. 4:** Fibrosis



**Fig. 5:** Microvesicular steatosis

**Table 1:** Age & sex

<b>Portal tract</b>	No of portal tracts Portal inflammation Fibrosis Bile duct Hepatic artery/Portal vein
<b>Lobules</b>	Steatosis Necrosis Inflammation Inflammatory cells Cholestasis Ballooning of hepatocytes Viral inclusions Mallory bodies Iron on pearl stain
<b>Other findings</b>	
<b>Impression</b>	

#### 4. Discussion

From our study, only 3 patients had evidence of previous liver injury in the form of cirrhosis and hence showing fibrosis in histopathological examination. Cholestasis being induced mostly by viral etiology and drugs is seen in 10% of the patients.

In correlation with ours, one study found patients dying of COVID-19 had biochemical evidence of hepatitis (of variable severity) but no direct effect due to COVID-19.<sup>1</sup> Another study found similar findings but concluded that there is no direct evidence of liver failure in COVID-19 without preexisting liver disease.<sup>2</sup> Thomas et al. found patients with pre-existing cirrhosis were at remarkably high risk of severe COVID-19 and death through their studies.<sup>3</sup>

Schmit G et al. concluded that COVID-19 infection was not associated with a specific histopathological pattern of the liver in their study.<sup>4</sup> Hence to conclude liver damage during this pandemic is more related to preexisting disease, drug induced changes and effects of viral infection. There isn't a strong evidence as yet to note down significant direct changes in liver that can occur due to COVID 19.

#### 5. Source of Funding

None.

#### 6. Conflict of Interest

The authors declare no conflict of interest.

#### References

1. Lagana SM, Kudose S, Iuga AC. Hepatic pathology in patients dying of COVID-19: a series of 40 cases including clinical, histologic, and virologic data. *Mod Pathol*. 2020;33:2147–55.
2. Ali N. Relationship between COVID-19 Infection and Liver Injury: A Review of Recent Data. *Front Med*. 2020;7:458. doi:10.3389/fmed.2020.00458.
3. Marjot T, Webb GJ, Barritt AS. COVID-19 and liver disease: mechanistic and clinical perspectives. *Nat Rev Gastroenterol Hepatol*. 2021;18:348–64.
4. Schmit G, Lelotte J, Vanhaebost J, Horsmans Y, Bockstal MV, Baldin P. The Liver in COVID-19-Related Death: Protagonist or Innocent Bystander? *Pathobiology*. 2021;88:88–94.

#### Author biography

**Aravinth Subramaniam**, Consultant Pathologist

**Divya Gnanasekaran**, Junior Consultant Pathologist

**Raghunath**, Intensivist

**Dhivahar**, Intensivist

**Cite this article:** Subramaniam A, Gnanasekaran D, Raghunath, Dhivahar. Liver biopsy changes in fatal COVID 19 patients in a tertiary care hospital. *Indian J Pathol Oncol* 2022;9(1):91-93.