

Content available at: <https://www.ipinnovative.com/open-access-journals>

Indian Journal of Pathology and Oncology

Journal homepage: [www.ijpo.co.in](http://www.ijpo.co.in)

## Case Report

# A rare case of sclerosing angiomatoid nodular transformation (SANT) of the spleen in a 13-year old girl

Kshitija Kale<sup>1,\*</sup>, Tanushri Dhote<sup>1</sup>, Khan Mohammad<sup>1</sup>, Padmanabhan Anitha<sup>1</sup>

<sup>1</sup>Lokmanya Tilak Municipal Medical College and General Hospital, Sion, Maharashtra, India



## ARTICLE INFO

### Article history:

Received 27-04-2021

Accepted 26-06-2021

Available online 14-02-2022

### Keywords:

Pediatric

Sclerosing

Angiomatoid

Nodular Transformation

## ABSTRACT

Sclerosing Angiomatoid Nodular Transformation (SANT) of spleen is a benign, rare, vascular disease. We report a case of 13-year old female with left upper abdominal pain, ultrasound revealing a hypoechoic lesion in spleen; laparoscopic splenic resection was performed. The definitive diagnosis of SANT was based on histopathological examination and immunohistochemistry.

This is an Open Access (OA) journal, and articles are distributed under the terms of the [Creative Commons Attribution-NonCommercial-ShareAlike 4.0 License](https://creativecommons.org/licenses/by-nc-sa/4.0/), which allows others to remix, tweak, and build upon the work non-commercially, as long as appropriate credit is given and the new creations are licensed under the identical terms.

For reprints contact: [reprint@ipinnovative.com](mailto:reprint@ipinnovative.com)

## 1. Introduction

Sclerosing angiomatoid nodular transformation (SANT) is a rare benign splenic vascular lesion. It was first defined in 2004 by Martel et al.<sup>1</sup> Around fewer than 150 cases of SANT have been reported in the literature.<sup>2</sup> Usually, females and middle-aged adults are predominantly affected.<sup>3</sup> However, it is difficult to preoperatively diagnose SANT as compared to other neoplastic and non-neoplastic lesions, hence necessitating accurate histopathological examination. SANT in the pediatric age group is rare with only four cases reported till date (3 boys, 1 girl).<sup>4</sup> Of all the reported cases five were multifocal SANT; rest being solitary lesions. Our study reports a novel case of SANT in a 13-year old female child with diffuse involvement of the spleen.

## 2. Case Report

A 13-year old female child presented with left upper abdominal pain since a year. Ultrasonography revealed a low attenuation lesion in the spleen. A probable diagnosis

of benign vascular lesion was given. CT scan or MRI was not performed. Laparoscopic splenectomy was performed, and the tissue was sent for histopathological examination.

The spleen was received in multiple pieces aggregating to 11 x 08 centimeters. External surface was brownish, congested, nodular. Cut section appeared congested, with whitish fibrous strands separating the parenchyma into nodules. Gross examination suggested a diffuse splenic involvement.

Histopathologic examination revealed multiple angiomatoid nodules composed of vascular spaces, capillaries and sinusoid-like vessels of varying sizes in dense fibrotic stroma. Septae were seen having dense fibrous tissue and inflammatory cells, mainly lymphocytes and plasma cells. (Figure 1 a, Figure 2 a). Immunohistochemistry was performed and revealed CD34, CD31 and CD8 positivity (Figure 2 b-2d). CD 34 highlighted the capillary proliferation. CD 31 and CD 8 demonstrated sinusoids and endothelial cells of small veins were highlighted by CD 31. Also, CD 68 and S100 highlighted the spindle cell component and histiocytes.

On the basis of histopathologic and immunohistochemistry a diagnosis of Sclerosing Angiomatoid Nodular Transformation was offered.

\* Corresponding author.

E-mail address: [mrudulakm@gmail.com](mailto:mrudulakm@gmail.com) (K. Kale).

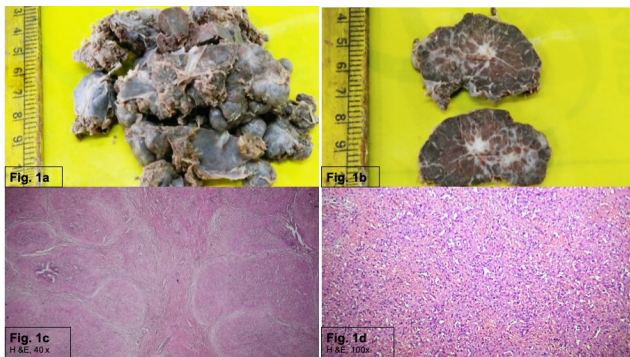


Fig. 1:

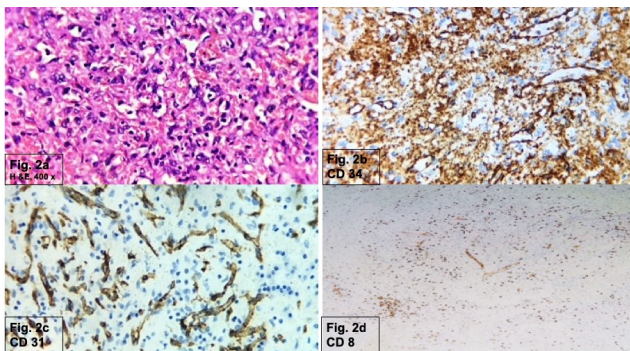


Fig. 2:

### 3. Discussion

Predominantly SANT is seen in females in middle age group. The majority of patients of SANT are asymptomatic, identified incidentally on imaging. There are only three cases of SANT reported in literature in pediatric age group. Usually pediatric SANT presents with abdominal pain and bloating.<sup>4</sup> Differentials of Gaucher's disease, splenic hamartoma, hemangioma, sarcoidosis and lymphoma prevail; thus, needing a splenectomy and microscopic examination. Our 13-year old female child presented with a history of prolonged abdominal pain and USG was done which revealed benign vascular lesion.

Numerous theories about pathogenesis of SANT have evolved. It was been proposed by Martel et al that SANT represents an unusual transformation of the red pulp in response to an exaggerated stromal proliferation.<sup>1</sup> Diebold et al suggested that metabolic changes and passive congestion of red pulp leading to damage to sinusoidal endothelial cells.<sup>5</sup> This culminates in a repair process resulting in deposition of inflammatory cells, histiocytes and fibrosis. The plasma cells present in sclerotic stroma were studied in which IgG4:IgG ratio was found to be raised. Our case showed moderate increase in number of plasma cells, although IgG4 studies were not possible.

Our case showed a diffuse involvement of spleen. The entire spleen was nodular and separated by fibrous strands.

Out of 127 cases reported in literature only 5 case were multifocal SANT, others were solitary lesions in spleen.<sup>6</sup> The solitary lesions mentioned in literature ranged from 3 cm to 17 cm in diameter and the cut surface was nodular with whitish fibrous septae.<sup>1</sup> However, no case of a diffuse splenic involvement by SANT has been yet reported.

The classic microscopic features of SANT are the three types of vascular channels: well-formed capillaries lined by endothelial cells which are CD 34 and CD 31 positive, splenic sinusoids which express CD 31 and CD 8, small veins which are CD 31 positive.<sup>3</sup> ##spindle cells

Radiologically it appears as a hypodense mass. Hence there is myriad of potential mimics such as vascular lesions, splenic hamartoma, lymphoma and metastasis. Thus, splenectomy is a modality for diagnosis. Other vascular lesions can be ruled out with microscopic examination and immunohistochemistry. Cavemous hemangioma commonly seen in spleen has a monotonous blood vessel composition and no evidence of sclerosis. Hemangioendothelioma is a very rare entity in spleen with intermediate malignant potential and it can be ruled out due to lack of cytological atypia and mitotic figures.<sup>7</sup>

Also, no cases of recurrence have been reported following a splenectomy; thus, traditional or laparoscopic splenectomy is largely considered to be a curative option.<sup>8</sup>

### 4. Conclusion

Sclerosing Angiomatoid Nodular Transformation of the spleen although being rare in children, is to be considered in the differential diagnosis of benign splenic vascular lesions in pediatric age group.

### 5. Source of Funding

None.

### 6. Conflict of Interest

The authors declare no conflict of interest.

### References

1. Martel M, Cheuk W, Lombardi L, Lifschitz-Mercer B, Chan JK, Rosai J. Sclerosing Nodular Angiomatoid Transformation (SANT): report of 25 cases of a distinctive benign splenic lesion. *Am J Surg Pathol.* 2004;28(10):1268–79.
2. Falk GA, Nooli NP, Stiff GM, Plesec TP, Rosenblatt S. Sclerosing angiomatoid nodular transformation (SANT) of the spleen: Case report and review of the literature. *Int J Surg Case Rep.* 2012;3(10):492–500.
3. Capaldi M, Fransvea P, Ricci G, Stella F, Trombetta S, Cerasari S, et al. Sclerosing angiomatoid nodular transformation (SANT) of spleen mimicking a splenic abscess: Case report and review of the literature. *Int J Surgery Case Reports.* 2019;56:1–4.
4. Zhang S, Yang W, Xu H, Wu Z. Sclerosing Angiomatoid Nodular Transformation of Spleen in a 3-year-old Child. *Indian Pediatr.* 2015;52(12):1081–3.
5. Diebold J, Tourneau AL, Marmey B, Prevot S, Müller-Hermelink HK, Sevestre H, et al. Is sclerosing angiomatoid nodular transformation (SANT) of the splenic red pulp identical to

- inflammatory pseudotumour? Report of 16 cases. *Histopathology*. 2008;53(3):299–310.
6. Zhixin C, Qiangxiu W, Jiamei L, Jiawen X, Jianfeng L. Multifocal sclerosing angiomatoid nodular transformation of the spleen: a case report and review of literature. *Diagn Pathol*. 2015;10:95. doi:10.1186/s13000-015-0312-2.
  7. Mills SE, Carter D, Greenson JK, Reuter VE, Stoler MH. Sternberg's Diagnostic Surgical Pathology. 6th ed. Philadelphia: Wolters Kluwer Health; 2015.
  8. Budzyński A, Demczuk S, Kumiega B, Migaczewski M, Matłok M, Zub-Pokrowiecka A, et al. Sclerosing angiomatoid nodular transformation of the spleen treated by laparoscopic partial splenectomy. *Wideochir Inne Tech Maloinwazyjne*. 2011;6(4):249–55.

### Author biography

**Kshitija Kale**, Junior Resident 3

**Tanushri Dhote**, Senior Resident

**Khan Mohammad**, Junior Resident 3

**Padmanabhan Anitha**, Associate Professor

**Cite this article:** Kale K, Dhote T, Mohammad K, Anitha P. A rare case of sclerosing angiomatoid nodular transformation (SANT) of the spleen in a 13-year old girl. *Indian J Pathol Oncol* 2022;9(1):88-90.