

Content available at: <https://www.ipinnovative.com/open-access-journals>

Indian Journal of Pathology and Oncology

Journal homepage: www.ijpo.co.in

Case Report

Low grade appendiceal mucinous neoplasm

Sayali Shinde^{1,*}, Smita A Sawant¹

¹Dept. of Pathology, K.J Somaiya Medical College & Research Centre, Mumbai, Maharashtra, India



ARTICLE INFO

Article history:

Received 17-10-2021

Accepted 29-12-2021

Available online 14-02-2022

Keywords:

LAMN

ovarian mucinous tumours

pseudomyxoma peritonei

ABSTRACT

Low grade appendiceal mucinous neoplasm (LAMN) is a rare tumour which lacks usual form of destructive invasion but has ability to spread to peritoneum and ovaries which frequently progresses to pseudomyxoma peritonei and often result in death of patient despite the bland histology of the mucinous epithelium. There are lot of controversies about its classification, clinical significance of pseudomyxoma peritonei, whether ovarian mucinous tumours in this setting are separate primaries or are the metastasis from the appendiceal tumours which are to be solved. We reported two cases of LAMN in which first case was with pseudomyxoma peritonei with secondary involvement of left ovary while other was simple LAMN without any involvement. Whenever we diagnosed LAMN it is necessary to look for ovarian involvement and pseudomyxoma peritonei.

Key Messages: It is necessary to rule out ovarian involvement and pseudomyxoma peritonei whenever we diagnosed LAMN. The unified approach of grading pseudomyxoma peritonei is required for more standardized and prognostically valuable diagnostic reporting.

This is an Open Access (OA) journal, and articles are distributed under the terms of the [Creative Commons Attribution-NonCommercial-ShareAlike 4.0 License](https://creativecommons.org/licenses/by-nc-sa/4.0/), which allows others to remix, tweak, and build upon the work non-commercially, as long as appropriate credit is given and the new creations are licensed under the identical terms.

For reprints contact: reprint@ipinnovative.com

1. Introduction

LAMN is a rare entity accounting for 1% of gastrointestinal neoplasm and is found in less than 0.3% of appendectomy specimen. It is an incidental finding during operative exploration and is often diagnosed late. Grossly, appendix may be unremarkable or may appear mucin filled, cystically dilated tissue. The appendix wall may appear thin, fibrotic, hyalinised or calcified with smooth or granular appearance. The most feared complication is seeding into peritoneum leading to pseudomyxoma peritonei, in late stage of disease. PSOGI (2016) proposed diagnostic terminology of primary appendiceal neoplasm along with criteria of defining LAMN while AJCC 8th edition defined grading and staging of LAMN.¹ We reported two cases of LAMN with one involving peritoneum and one confined to appendix only.

2. Case History

2.1. Case 1

A 45-year old female came with pain in abdomen since 7 days. Abdominal CT scan revealed recent complicated appendicitis with periappendiceal collection and left ovarian simple cyst measuring 4.9X4.3 cm. Serum tumour markers were not done. Emergency appendectomy done. Grossly, we received appendix measuring 5cmx3cm which on cut surface show thickened wall and periappendiceal gray white myxoid area. Entire specimen was submitted. Microscopy showed circumferential involvement of the mucosa by mucin rich epithelium involving at least one segment of appendix (Figure 1 a and 1b), pushing invasion (diverticulum like growth) of epithelium (Figure 2), loss of muscularis mucosa (Figure 2), fibrosis of sub mucosa (Figure 2) and serosa showed acellular mucin (Figure 3). On which diagnosis was made as LAMN. Patient was re-

* Corresponding author.

E-mail address: saya2189@gmail.com (S. Shinde).

operated for right hemicolectomy and left oophorectomy. Intra-operatively mucinous deposits were seen in pelvic cavity which were acellular on microscopy and colon was unremarkable with acellular mucinous deposits on serosa. Left ovary was submitted for frozen section and diagnosis was given as benign mucinous cystic neoplasm (Figure 4). IHC was done on ovarian section in which it was CK20 (Figure 5 a), CDX2 (Figure 5 b), CEA (Figure 5 c) positive and CK7 (Figure 5 d), PAX8 (Figure 5 e) negative.

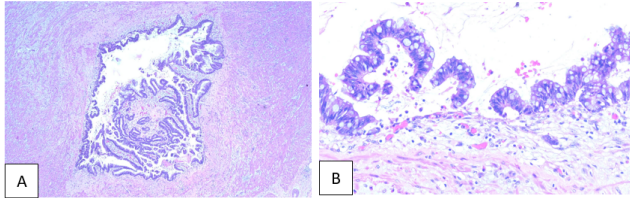


Fig. 1:

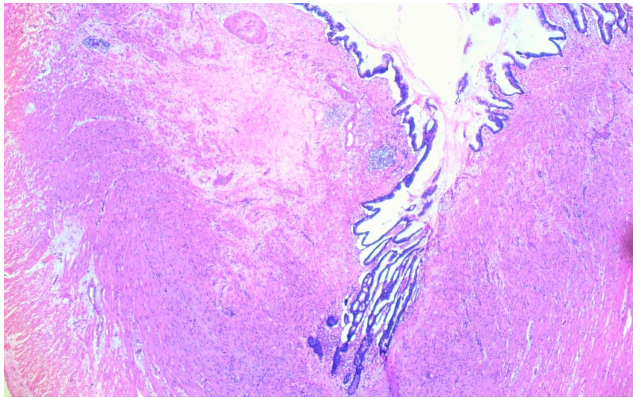


Fig. 2:

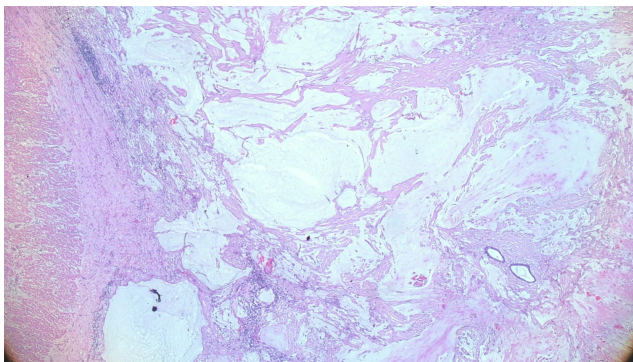


Fig. 3:

On the basis of it, diagnosis was made as LAMN with Pseudomyxoma peritonei with secondary involvement of left ovary. And staged as pT4aM1a.

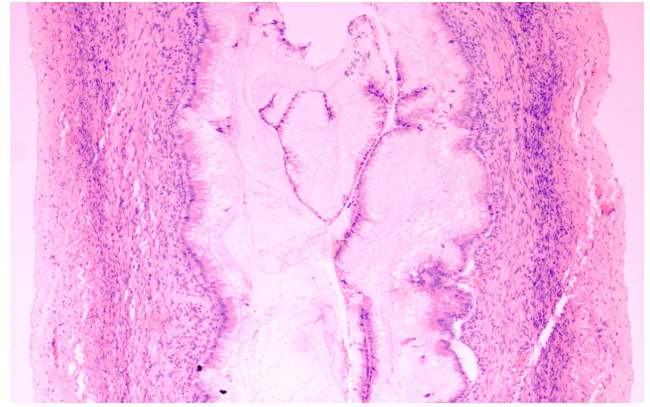


Fig. 4:

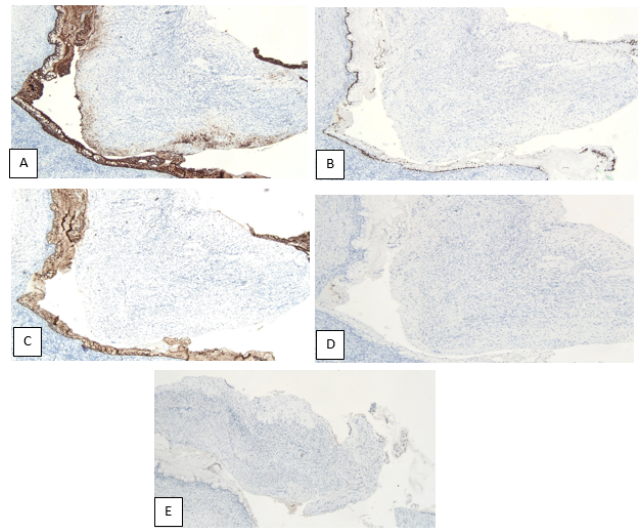


Fig. 5:

2.2. Case 2

60 year female came with pain in abdomen, on sonography mucocele appendix was diagnosed for which laproscopic appendicectomy along with bilateral salpingo oophorectomy done. Grossly, appendix measured 5.5x2cms, partly open and mucoid contents seen in lumen also received mucoid contents separately aggregating to 8x6cm. One ovary showed well circumscribed greyish white nodule measuring 1.1x0.9cm, other ovary was unremarkable. On microscopy it was low grade appendiceal mucinous neoplasm with base involvement and one ovary showed multiple follicular cysts with stromal hyperplasia and fallopian tube showed paratubal cysts. Other ovary and fallopian tube were unremarkable. Patient was re-operated for right hemicolectomy which was free of tumour. There was no evidence of pseudomyxoma peritonei.

3. Discussion

LAMN is a rare entity with female predominance and it is mostly seen in 5th to 6th decade of life.¹ Entire appendix should be submitted for histological examination of LAMN as it is an incidental finding and most of the patients are presented with acute appendicitis.¹ PSOGI (2016) classifies it as non-invasive neoplasm, while according to AJCC 8th edition, it is graded as G1, well differentiated mucinous neoplasm.¹ In our case 1, it was staged as T4aM1a (AJCC 8th edition) as tumour was penetrating the visceral peritoneum, and acellular mucin was involving the serosa of the appendix and peritoneum without identifiable tumour cells; while in case 2, it was staged as Tis as tumour was confined to muscularis propria. Extra-appendiceal mucin is of utmost importance for proper staging, prognosis and modes of management. Differential diagnosis of LAMN are Mucinous adenocarcinoma, serrated polyp and villous adenoma. In mucinous adenocarcinoma, infiltrative pattern with high grade cytological features are seen while in serrated polyp (localized serrated epithelial lesion) and villous adenoma (dysplasia, focal tubulovillous architecture) show retention of muscularis mucosa.¹ Pseudomyxoma peritonei is defined as presence of intraperitoneal mucin with or without associated mucin producing epithelium. The histologic grade of peritoneal disease is considered as extremely important criteria as it more likely influences prognosis and should be used for staging purposes.² Currently, 3- tiered grading scheme is favoured to classify PMP as Grade 1 (low grade), Grade 2 (high grade) and Grade 3 (high grade with signet-ring cells).² This unified approach of grading will allow for more standardized and valuable diagnostic reporting. There are few scenario which shows discordant grading between primary and peritoneal disease at that time overall grading should be done according to peritoneal disease.¹ e.g. if primary appendix is G1 and peritoneal disease G2; then overall grade should be assigned as G2. Recent immunohistochemical, molecular and genetic evidence supports that, pseudomyxoma peritonei concomitant with ovarian and appendiceal neoplasm has its origin in appendix in most of the cases and secondary involvement of the peritoneum and ovaries.³ Ovarian involvement in LAMN is often bilateral and show two distinctive histological features, “scalloped” glands and sub epithelial stromal clefts

(Figure 4), whereas primary borderline ovarian mucinous tumours are more often associated with reactive cellular stroma and histiocyte aggregates.⁴ All the cases of female with appendiceal mucinous neoplasm, the ovaries should be meticulously examined and vice versa. IHCs like CK7, CK20, CDX2 and PAX8 and SATB2 are useful for the same.⁴ In summary, for grading and staging of mucinous neoplasm of appendix and Pseudomyxoma Peritonei; unified approach should be used for standardized diagnostic reporting. Extra-appendiceal mucin is important for staging and prognosis. The grade of peritoneal disease influences prognosis and should be used for staging purposes. Pseudomyxoma Peritonei with simultaneous appendix and ovarian neoplasm should be treated as primary appendiceal tumour.

4. Source of Funding

None.

5. Conflict of Interest

The authors declare no conflict of interest.

References

1. Pai R. An Update on the Diagnosis, Grading, and Staging of Appendiceal Mucinous Neoplasms. *Adv Anat Pathol*. 2018;25(1):38–60.
2. Bradley RF, Carr NJ. Pseudomyxoma Peritonei, Pathology, A Historical Overview, and Proposal for Unified Nomenclature and Updated Grading. *AJSP*. 2019;24(3):88–93.
3. Misdraji J. Appendiceal Mucinous Neoplasms: controversial issues. *Arch Pathol Lab Med*. 2010;134:864–870.
4. Guerrieri C, Frånlund B, Fristedt S, Gillooley JF, Boeryd B. Mucinous Tumours of the vermiform appendix and ovary and pseudomyxoma peritonei; histogenetic implications of CK7 expression. *Hum Pathol*. 1997;28(9):1039–45.

Author biography

Sayali Shinde, Assistant Professor

Smita A Sawant, Professor

Cite this article: Shinde S, Sawant SA. Low grade appendiceal mucinous neoplasm. *Indian J Pathol Oncol* 2022;9(1):81-83.