



Case Report

Tumors colliding in thyroid: A case report

Kunjalkaria^{1,*}, Mrinal Kishor Mallya¹

¹Dept. of Pathology, Saifee Hospital, Mumbai, Maharashtra, India



ARTICLE INFO

Article history:

Received 13-09-2021

Accepted 09-12-2021

Available online 14-02-2022

Keywords:

Follicular carcinoma

Papillary carcinoma

Thyroid malignancy

ABSTRACT

The synchronous presence of two histologically distinct and morphologically independent primary malignancies within the same organ is termed as collision tumor. However, these tumors are rare and many theories like stem cell theory, hostage theory, collision theory are proposed to explain their occurrence. The most frequently encountered collision tumor in the thyroid gland is of papillary carcinoma and medullary carcinoma. We report an extremely rare case of 41 year old female with papillary and follicular collision tumor. The diagnosis of synchronous thyroid malignancy was made on histopathology of the excised tissue.

This is an Open Access (OA) journal, and articles are distributed under the terms of the [Creative Commons Attribution-NonCommercial-ShareAlike 4.0 License](https://creativecommons.org/licenses/by-nc-sa/4.0/), which allows others to remix, tweak, and build upon the work non-commercially, as long as appropriate credit is given and the new creations are licensed under the identical terms.

For reprints contact: reprint@ipinnovative.com

1. Introduction

The incidence of thyroid malignancy is rapidly increasing worldwide. The most common thyroid cancers are papillary, follicular, medullary, anaplastic and undifferentiated types.¹ The presence of more than one type of well differentiated histologically different carcinomas separated with normal parenchymal tissue in the same organ is rare.² Various combinations of such dual pathology in thyroid gland are papillary-medullary, follicular-papillary, follicular –medullary.³ These entities are called collision tumors, mixed tumors or composite tumors based on histo-morphological features.¹ Here we report a case of simultaneous occurrence of follicular and papillary carcinoma in 41 year female. Only two cases of this combination have been reported till date.

2. Case Report

A 41-year female presented with anterior neck swelling and D11 compression fracture to the outpatient department. Fine needle aspiration from thyroid gland showed features

of papillary thyroid carcinoma. (Figure 1) D11 lesion was biopsied and revealed metastatic differentiated thyroid carcinoma. The thyroid function test was within normal limits. PET scan showed nodular thyroid with metabolically active hypodense nodule in the upper pole of the left lobe. Also seen were lytic destructive lesion in the manubrium sterni and D11 vertebrae suggesting metastatic involvement.

The patient underwent total thyroidectomy with lateral and central compartment neck dissection. The resected specimen weighed 20 grams. The capsule was intact and smooth. On serial sectioning, the right lobe showed three separate firm grey white tumors measuring 0.9cm, 0.8 cm and 0.5 cm in greatest dimension. A large firm tumor measuring 2.4 cm in the greatest dimension was noted in the left lobe. The microscopic examination of the tumors from right lobe showed features of papillary carcinoma.(Figure 2) These tumor cells were arranged in complex, branching randomly dispersed papillae with fibrovascular cores. These tumor cells showed enlarged oval nuclei, optically clear chromatin and nuclear grooves. The tumor in the left lobe showed tightly packed micro-follicles along with scattered macro-follicles. This tumor showed capsular invasion and angio-invasion. These features were

* Corresponding author.

E-mail address: kunjalkaria@gmail.com (K. M. Karia).

of follicular thyroid carcinoma. (Figure 4) Additionally, in the left lobe adjacent to the main tumor was a small distinct focus of papillary carcinoma (0.5 cm in greatest dimension). All the lateral and central compartment lymph nodes were negative for metastasis. Based on this histology a diagnosis of follicular-papillary collision tumor of thyroid was made.(Figure 3)

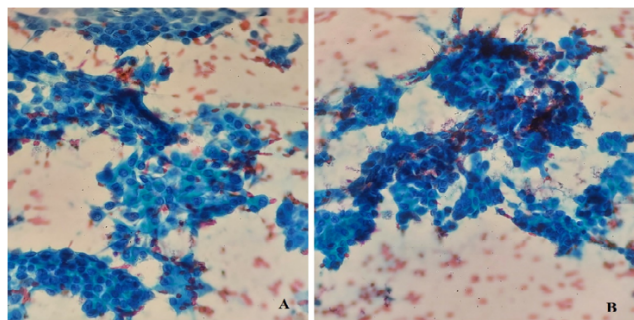


Fig. 1: Fine needle aspiration from thyroid showing papillary carcinoma with nuclear grooves and holes (400X)

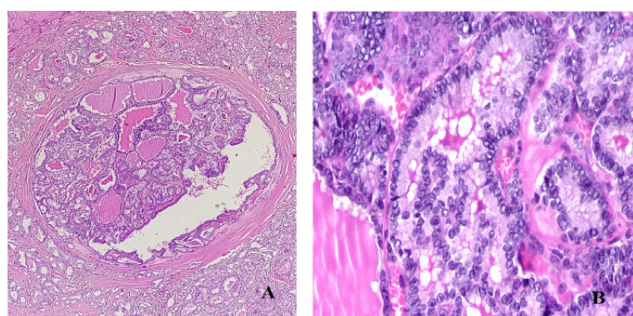


Fig. 2: (A): Papillary carcinoma in thyroid lobes (40X) (B): Tumor shows enlarged oval nuclei and grooves (400X)

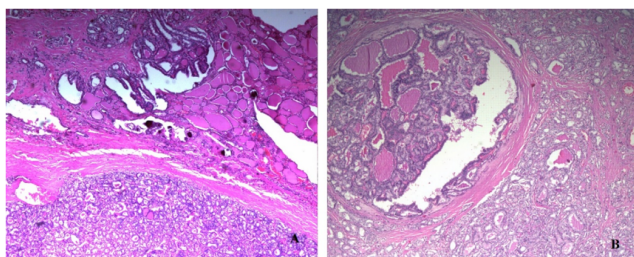


Fig. 3: (A& B) Synchronous papillary and follicular thyroid carcinoma in left thyroid lobe (40X and 100X)

3. Discussion

The incidence of thyroid malignancy as the commonest endocrine malignancy varies from 0.5 to 10 new cases per 1 lakh population per year worldwide.^{1,4} The most

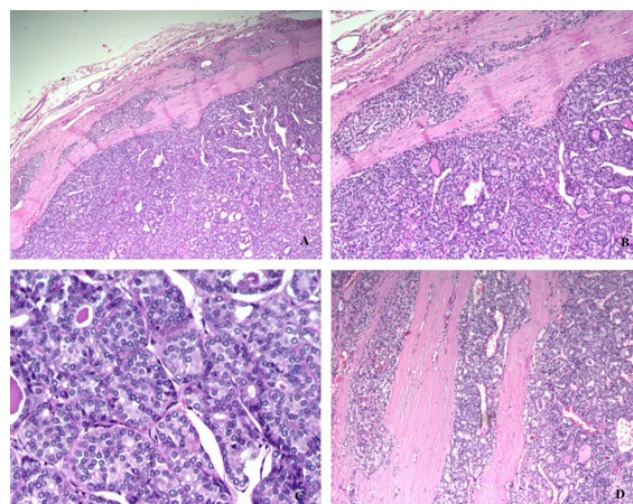


Fig. 4: A & B): Follicular carcinoma in thyroid with capsular invasion (100X); C): Tumor shows round hyperchromatic nuclei (400X); D): Follicular carcinoma with angio-invasion (200X)

common differentiated thyroid malignancy is papillary carcinoma having an incidence of 60-65% followed by follicular carcinoma accounting for 15%. Papillary and follicular carcinoma both are encountered in 4th- 7th decade with female preponderance. Follicular thyroid carcinoma and papillary thyroid carcinoma are relatively quiescent tumors, however they are known to metastasize hematogenously and through lymphatics respectively.^{3,5,6} Many genetic alterations are involved in tumorigenesis of different thyroid carcinomas. 30% to 70% of papillary thyroid cancer exclusively showed BRAF mutations. Other mutations harboured by papillary thyroid cancer were somatic rearrangements of RET/ PTC. Follicular thyroid carcinoma incidence is encountered more in areas of iodine deficiency. These populations have elevated TSH levels and many show presence of activating RAS mutations.^{1,2} The alteration in MAPK pathway due to BRAF and NRAS mutations suggest overlapping molecular pathophysiology of both these tumors.³

The presence of well-differentiated tumor in the thyroid gland is common, but harboring of more than one type of malignancy simultaneously is rare. The commonest synchronous malignancy occurring in the thyroid gland are medullary-papillary cancer. Collision tumors presenting in thyroid gland are extremely rare but they can be encountered in other organs like kidneys, ovaries, colon, lung, skin and stomach. These tumors are diagnostically challenging.¹ These dual cancers occurring in the same organ can be collision tumors, mixed tumors, or composite tumors.³ The two histo-morphologically distinct malignant tumors coexisting adjacently in the same organ are called as collision tumors. Mixed tumors are the tumors that shows histological admixture of two types of malignant

tumors. Composite tumors are tumors with two discrete cell population.⁶ Till date 6 cases of synchronous follicular and papillary cancers are reported, including 1 with additional undifferentiated carcinoma and 3 with medullary carcinoma with it.³ Plauche et al. in 2013 reported first follicular-papillary thyroid collision tumor.

Our case showed synchronous papillary-follicular cancer with metastasis to D11 vertebrae. It may be postulated in our case that hematogenous spread to D11 vertebrae occurred due to follicular thyroid carcinoma component.

The criteria for the presence of multiple primary tumors in same organ was first laid in 1879 by Bilroth which later were simplified by Warren and Gates. The criteria is as follows:

1. Each tumor must demonstrate a definite picture of malignancy
2. Each tumors must be distinct.
3. The possibility that one of the tumors is a metastatic lesion from the other should be excluded.¹

Many hypotheses are laid to explain the formation of collision tumors.

1. The theory that collision tumors arise from a single pluripotent precursor cell was proposed by Lax et al.
2. “Neoplastic coercion” was the other hypothesis which stated that a single neoplasm arises and its presence alters the microenvironment and facilitates the development of the second malignant tumor.
3. The chance meeting of two different malignant tumors by de novo or local genesis is another postulated hypotheses.^{5,7}
4. Takano in 2004 proposed fetal cell carcinogenesis model for thyroid carcinogenesis. According to this model papillary carcinoma, follicular carcinoma and anaplastic carcinoma arise from thyroblasts, pro-thyocytes and thyroid stem cell remnants respectively. It also states that due to differentiation process follicular tumors can arise from different cells, thus follicular carcinoma can arise from papillary carcinoma but vice versa is not possible.¹ Inadequate data and evidence fails to explain the origin of these collision tumors.

Collision tumors being more aggressive, its diagnosis and treatment is challenging and complex. The treatment is patient specific and depends on the biology of dual tumors involving thyroid. Each component of these neoplasms should be treated independently. The mainstay for treatment of thyroid collision tumors is surgery and adjuvant therapy like external beam radiotherapy, radio-iodine.^{1,3}

4. Conclusion

We report a rare case of collision tumor of thyroid with follicular and papillary thyroid carcinoma component. The reported literature of collision tumor in thyroid is less. The presence of two malignant tumors make the diagnosis and management challenging. There is no specific postulate that can explain the origin of these tumors. We present this case to increase awareness about this entity as it is essential to make an accurate diagnosis of these tumors in order to plan adequate and specific treatment protocols.

5. Source of Funding

None.

6. Conflict of Interest

The authors declare no conflict of interest.

References

1. Thomas VP, George R. Collision tumors of the thyroid: Review of literature and report of a case of papillary-Follicular collision tumor. *Thyroid Res Pract.* 2018;15(2):60–4.
2. Verdi D, Pennelli G, Galuppini F, Pelizzo MR, Toniato A. Synchronous medullary, papillary and follicular carcinomas in the same thyroid: case report and review of literature. *Updates Surg.* 2013;65(4):329–32.
3. Cracolici V, Mujacic I, Kadri S, Alikhan M, Niu N, Segal JP. Synchronous and metastatic papillary and follicular thyroid carcinomas with unique molecular signatures. *Endocr Pathol.* 2018;29(1):9–14.
4. Cupisti K, Raffle A, Ramp U, Wolf A, Donner A, Krausch M. Synchronous occurrence of a follicular, papillary and medullary thyroid carcinoma in a recurrent goiter. *Endocr J.* 2005;52(2):281–5.
5. Ryan N, Walkden G, Lazic D, Tierney P. Collision tumors of the thyroid: A case report and review of the literature. *HeadNeck.* 2015;37(1):E125–9.
6. Plauche V, Dewenter T, Walvekar RR. Follicular and papillary carcinoma: a thyroid collision tumor. *Indian J Otolaryngol Head Neck Surg.* 2012;65(1):182–4.
7. Tang P, Khor L, Takano A. Synchronous papillary thyroid carcinoma and medullary thyroid carcinoma- a pitfall waiting to happen. *Malaysian J Pathol.* 2017;39(2):171–4.

Author biography

Kunjil Mukesh Karia, DNB Trainee

Mrinal Kishor Mallya, Consultant Histopathologist

Cite this article: Karia KM, Mallya MK. Tumors colliding in thyroid: A case report. *Indian J Pathol Oncol* 2022;9(1):71-73.