



Case Report

Micro-invasive squamous cell carcinoma of gastro-esophageal junction in a teenage female: A rare case report

Kafil Akhtar^{1,*}, Mohd Talha¹, Sadaf Haiyat¹, Habeeb Raza²

¹Dept. of Pathology, Faculty of Medicine, Jawaharlal Nehru Medical College, Aligarh Muslim University, Aligarh, Uttar Pradesh, India

²Dept. of Surgery, Faculty of Medicine, Jawaharlal Nehru Medical College, Aligarh Muslim University, Aligarh, Uttar Pradesh, India



ARTICLE INFO

Article history:

Received 04-06-2020

Accepted 24-06-2020

Available online 19-11-2020

Keywords:

Endoscopy

Gastroesophageal junction

Squamous cell carcinoma

Teenage female

ABSTRACT

Squamous cell carcinoma (SCC) of upper gastrointestinal (GI) tract is an aggressive malignancy more common in older age group. Post 1970's with advent of endoscopy and the discovery of H. pylori bacteria and with its role in malignancy of esophagus and stomach, detection rate of squamous cell carcinoma esophagus has increased subsequently. In this case report we present a case of squamous cell carcinoma gastroesophageal (GE) junction in a 15 years old female owing to its rarity in younger age. The patient presented in the surgery OPD with history of weight loss and dysphagia since the last 5 months. She also complained of epigastric pain and heartburn since the last 2 months. There was no past history of carcinoma of GIT in any family members. Upper GI endoscopy showed an exophytic growth at the GE junction. Histopathological examination of subsequent GE biopsy confirmed the diagnosis of micro-invasive squamous cell carcinoma while the stomach showed features of chronic atrophic gastritis. The patient underwent resection of GE junction through thoraco-abdominal approach followed by radiotherapy for any residual tumour. Our patient is doing well after 3 months post op follow up. This case report emphasises the rare occurrence of SCC in a teenage female with no family history and to consider it in the differential diagnosis in younger patients with similar complaints.

© This is an open access article distributed under the terms of the Creative Commons Attribution License (<https://creativecommons.org/licenses/by/4.0/>) which permits unrestricted use, distribution, and reproduction in any medium, provided the original author and source are credited.

1. Introduction

Squamous cell carcinoma (SCC) of esophagus particularly of GE junction in older age group has been reported in the past. Post 1970's many literatures report SCC in both younger and older age group owing to aggressive use of endoscopy and detection of H. pylori bacteria with special stain.¹ Its prognosis in younger age group remain controversial. Some case series report better prognosis while others report poor prognosis of SCC in younger age group when compared with older age group.^{2,3} Esophageal SCC occur worldwide with variable geographic distribution. Higher incidence of cases are seen in China, Iran, South Africa, France and Italy.³

Microscopically, esophageal SCC show presence of atypical cell with nuclear hyperchromasia, clumped chromatin and loss of polarity of cells. Clinically, they present as fungative, ulcerative or infiltrative lesions, ranging from well differentiated lesions with focal keratinization to poorly differentiated lesions showing marked cytologic atypia, increased mitotic activity (>10 mitosis/10HPF) and widespread necrosis. Majority of cases present with metastasis to distant site with poor prognosis.³

2. Case Summary

A 15 years old teenage female presented to the surgery out-patient department with complaints of dysphagia since last 5 month initially for solid foods which progressively increased to liquids since last 2 month. She also complained

* Corresponding author.

E-mail address: drkafilakhtar@gmail.com (K. Akhtar).

of weight loss of approximately 8kgs during this period and epigastric pain associated with heartburn since the last 2 months. The pain was intermittent, dull in nature and occurred shortly after food intake. However there was no complaint of pain during deglutition, chest pain or vomiting. There is no history of addiction or family history of upper GI malignancies.

On general examination, the patient was of thin built with wasting of muscles of extremities, afebrile, had low blood pressure of systolic 90/diastolic 50, raised pulse rate of 120 per minutes and pallor. Systemic examination was unremarkable except for presence of systolic murmur. Routine lab examinations like haemogram, general blood pictures, urine examination, liver function test, renal function test, lipid profile, iron profile, Vit. B12 assay and electrocardiogram were normal except for the presence of dimorphic (mixed nutritional deficiency) anaemia and low blood sugar (60mg/dl).

Imaging study viz., x ray of abdomen and chest showed normal studies. Barium swallow show rat tail appearance of lower third of the esophagus. Endoscopic examination showed ulcerated exophytic growth at GE junction partially obstructing the lumen and reddened area in stomach along greater curvature. Histopathology of GE junction growth showed marked dysplastic and koilocytic changes in stratified squamous lining. Superficial stroma showed nests of dysplastic squamous cells and reactive desmoplasia with moderate lymphocytic inflammation, findings consistent with microinvasive squamous cell carcinoma (Figures 1 and 2). Staining of biopsy sections for *H. pylori* and Human papilloma virus (HPV) were negative. Sections from gastric biopsy was consistent with chronic atrophic gastritis. CT scan & MRI of abdomen and thorax did not show any evidence of metastasis. Patient underwent resection of GE junction with clearing of margins through left thoraco-abdominal approach along with end to end anastomosis. No lymph nodes were found to be enlarged intraoperatively. Patient was administered 50 Gy in 35 fractions of Co-60 radiotherapy for any residual tumour along with gradual resumption of oral diet. Our patient is doing well after 3 months of follow up.

3. Discussion

Squamous cell carcinoma of esophagus is among top 10th most common malignancies in the world. Adenocarcinoma of distal esophagus is relatively rare. However in past 25 years, incidence of esophageal adenocarcinoma has exceeded incidence of squamous cell carcinoma in the US and other western countries.^{4,5} Gastro-esophageal SCC is more common in black males. Male to female ratio is 7:1.5 years. Survival rate is 11% with no difference between various histologic types.² Risk factors include smoking, alcohol use, high salt intake in diet (pickles, fish),

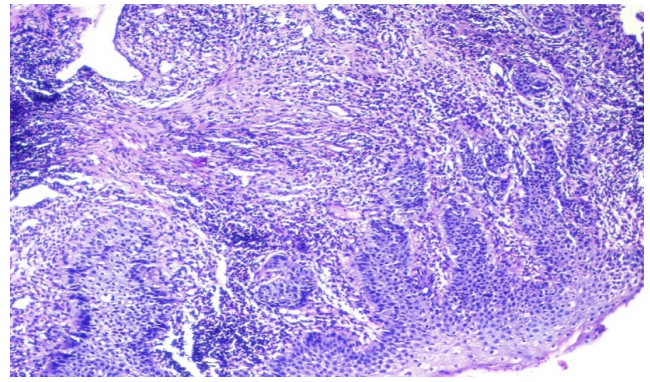


Fig. 1: Tissue section shows markedly dysplastic and koilocytic changes in stratified squamous lining. Superficial stroma shows nests of dysplastic squamous cells and reactive desmoplasia with moderate lymphocytic inflammation. Hematoxylin and Eosin x10X.

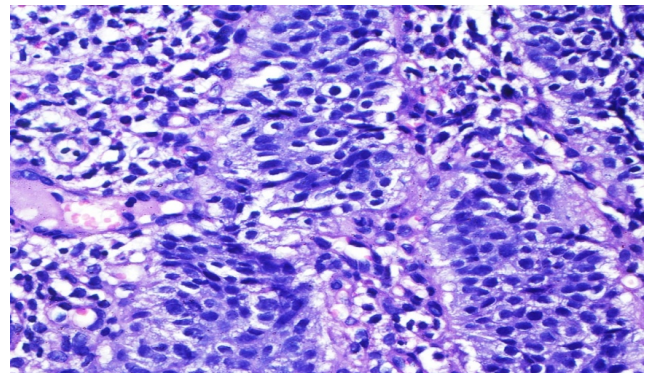


Fig. 2: High power of Figure 1. Hematoxylin and Eosin x40X.

low fibre diet, poor socioeconomic status and *H. pylori* associated infection.^{6,7} Other risk factors include deficiency of vitamins A, C & E, occupational exposures to asbestos, perchloroethylene, combustion products, ionizing radiation and Human papilloma virus (HPV).⁶

Few cases of GE junction esophageal carcinoma have been reported so far. Youngest patient of esophageal carcinoma reported in India is a 8 year old girl with carcinoma in middle third portion with lung metastasis.⁸ The prevalence of esophageal carcinoma is high in first degree relative with esophagitis. Tylosis, achalasia, esophageal diverticula, stricture and plummer–vinson syndrome are considered as premalignant conditions to esophageal carcinoma.

Microinvasive SCC is considered by some pathologists as early stage SCC with invasion of rete process in deeper tissues.⁹ Few literature defined microinvasive SCC as histological subtype of SCC with irregular infiltrative border along with reactive desmoplasia and lymphocytic inflammation of deeper tissues.^{9,10} Microinvasive SCC has greater propensity for lymphatic and vascular channel

infiltration. However owing to subjective variation in diagnosis of microinvasive SCC among pathologists, concrete literature comparing clinicopathological and prognostic differences between SCC and microinvasive SCC are lacking.^{11,12} However, many authors discuss poor prognosis of SCC in young compared to adults and emphasised careful monitoring and assessment of young patient with suspicion of esophageal SCC.^{8,13}

The differential diagnosis to be considered in case of GE junction SCC are achalasia, oesophageal stricture and benign esophageal tumour, especially leiomyoma. All these can be confirmed by combination of imaging studies (barium study, CT scan etc) and endoscopic imaging biopsy of any mass lesion.

Treatment of disease depends on the stage of tumour at time of presentation. Surgery alone or in combination with radiotherapy are the treatment of choice. Surprisingly outcome of disease is independent of age of the patient.¹³

4. Conclusions

This case report emphasises the importance of considering squamous cell carcinoma in patients with complaint of dysphagia even at an early age and in the absence of any associated risk factors.

5. Source of Funding

None.

6. Conflict of Interest

None.

References

1. Bowrey DJ, Clark GWB, Rees BI, Williams GT, Carey PD. Outcome of oesophagogastric carcinoma in young patients. *Postgrad Med J*. 1999;75(879):22–6.
2. Crew K, Neugut AI. Epidemiology of upper gastrointestinal malignancies. *Semin Oncol*. 2004;31(4):450–64.

3. Stoner GD, Wang LS. Chemoprevention of esophageal squamous cell carcinoma with berries. *Nat Prod Cancer Prev Ther*. 2012;22:20–1.
4. Parkin DM, Pisani P, Ferlay J. Estimates of the worldwide incidence of eighteen major cancers in 1985. *Int J Cancer*. 1993;54(4):594–606.
5. Blot WJ, Devesa SS, Kneller RW, Fraumeni JF. Rising incidence of adenocarcinoma of the esophagus and gastric cardia. *J Pathol*. 2017;265(10):1287–9.
6. CREW K. Epidemiology of upper gastrointestinal malignancies. *Seminars in Oncology*. 2004;31(4):450–464. Available from: <https://dx.doi.org/10.1053/j.seminoncol.2004.04.021>. doi:10.1053/j.seminoncol.2004.04.021.
7. Zhang ZF, Kurtz RC, Yu GP, Sun M, Gargon N, Karpehr M. Adenocarcinomas of the esophagus and gastric cardia: the role of diet. *J Nutr Cancer*. 2017;5:22–5.
8. Soni NK, Bikaner PC. Carcinoma of the oesophagus in an eight-year-old child. *J Laryngol Otol*. 1980;94(3):327–9.
9. Shankar AA, Gokul S. The dilemma of microinvasion. *Head Neck Oncol*. 2014;6(5):30–1.
10. Pentenero M, Navone R, Motta F, Marino R, Gassino L, Broccoletti R, et al. Clinical features of microinvasive stage I oral carcinoma. *Oral Dis*. 2011;17(3):298–303.
11. Woolgar JA, Triantafyllon A. Pitfalls and procedures in the histopathological diagnosis of oral and oropharyngeal SCC: A review of the role of pathology in prognosis. *Oral Oncol*. 2009;45:361–85.
12. Cardesa A, Slootweg PJ. Benign and potentially malignant lesions of squamous epithelium. In: *Pathology of Head and Neck*. Berlin: Springer; 2006. p. 1–48.
13. Nagdeve NG, Sarve GN, Hedawoo JB. Squamous cell carcinoma of esophagus in a 15-year-old boy. *J Indian Assoc Pediatr Surg*. 2010;15(2):59–60.

Author biography

Kafil Akhtar, Professor

Mohd Talha, Resident

Sadaf Haiyat, Resident

Habeeb Raza, Professor

Cite this article: Akhtar K, Talha M, Haiyat S, Raza H. Micro-invasive squamous cell carcinoma of gastro-esophageal junction in a teenage female: A rare case report. *Indian J Pathol Oncol* 2020;7(4):654–656.