



Original Research Article

A study on the morphological spectrum of salivary gland tumors

J Margaret Theresa^{1,*}, A B Harke², Lavanya M¹¹Dept. of Pathology, Sri Venkateshwara Medical College Hospital and Research Centre, Pondicherry, India²Dept. of Pathology, Karpaga Vinayaga Institute of Medical Sciences and Research Centre, Kanchipuram, Tamil Nadu, India

ARTICLE INFO

Article history:

Received 19-07-2019

Accepted 28-10-2019

Available online 22-02-2020

Keywords:

Salivary gland tumors

Benign tumors

Pleomorphic Adenoma

Malignant tumors

Mucoepidermoid carcinoma

ABSTRACT

Introduction: Salivary gland neoplasm are relatively uncommon and are constitute about 3% of all head and neck neoplasm. Atleast 80% of tumors are located in the parotid gland and the remaining tumors are located in submandibular, sublingual and in minor salivary glands.

Objective: The aim is to identify the occurrence of various salivary gland tumors and to categorize them as per WHO classification. Further to identify the histomorphological patterns of salivary gland tumors.

Materials and Methods: The biopsy and excised specimens of salivary gland tumors were received in the department of pathology. A gross examination of biopsy and excised specimen was carried out. All the biopsy specimens were well fixed in 10% buffered formalin, processed, embedded with paraffin. After the paraffin blocks were sectioned and stained with Haematoxylin-Eosin, special stains like PAS, Mucicarmin were applied to the sections where ever indicated. The stained slides were examined for histomorphological patterns of salivary gland neoplasms and categorized as per WHO classification.

Result and Conclusion: A total of 57 salivary gland tumors specimens were included in the present study. The study report revealed that 40 cases were belong to benign making it 70.2% and the remaining 17 were malignant making it to 29.8% of the total Salivary gland tumors. Pleomorphic Adenoma was the most commonly observed benign tumor. Out of 40 benign tumors 33 were Pleomorphic adenoma (82.5%). Mucoepidermoid carcinoma was the most commonly observed malignant tumor. Out of 17 malignant tumors 6 were Mucoepidermoid carcinomas (35.2%) of all the malignant tumors.

© 2020 Published by Innovative Publication. This is an open access article under the CC BY-NC-ND license (<https://creativecommons.org/licenses/by/4.0/>)

1. Introduction

Three pairs of major salivary glands are there in the oral cavity, which consist of parotid, submandibular and sublingual glands. Apart from these, other minor salivary glands are also in the oral cavity located in the floor of mouth, hard and soft palate, tonsil, tongue and oropharynx.¹ Salivary gland neoplasms are rare, and are account for about 3-10% of head and neck neoplasms.² As per the WHO revised classification (2017) salivary gland tumors account for more than 35 distinct variants.³ Keeping this in mind the present study is planned to analyze the morphological pattern and the spectrum of salivary gland tumors in this local population to understand and to correlate the variants

of salivary gland neoplasms in our area.

2. Materials and Methods

The present study is a retrospective and prospective study on salivary gland tumors, and was carried out in the department of Pathology for a period of five years between August 2012 and 2017. The study was conducted on biopsy and excised specimens of salivary gland tumors. A total number of 57 cases of Salivary gland tumors were included in this study. Institutional Ethics Committee approval was obtained. Required data like clinical history, duration of symptoms, location of tumors, and other relevant details such as age, gender, and social status use of tobacco were obtained from the patients. Other results such as radiological examination like X-ray, Ultrasound and CT

* Corresponding author.

E-mail address: margitheresa@gmail.com (J. M. Theresa).

scan of the patients were also reviewed and documented.

2.1. Methods

Formalin fixed biopsy and excised specimens of salivary gland neoplasms received from hospital were studied macroscopically. The tissues were routinely processed in to paraffin embedded blocks. Microscopic sections were taken and stained with Haematoxylin & Eosin. Special stains PAS and Mucicarmin were also used to stain the sections as and when required.

3. Results

Among the 57 cases of Salivary gland tumors, histopathological reports revealed that 40 of them were benign neoplasm (70.2%) and the other 17 were malignant (29.8%) showed in Table 1.

Table 1: Incidence of benign and malignant salivary gland tumors

Tumors	No. of cases	Percentage
Benign	40	70.2
Malignant	17	29.8
Total	57	100

On the basis of histomorphological features, the benign salivary gland neoplasms were further classified in Pleomorphic adenoma, Warthin's tumor, Basal cell adenoma and Myoepithelioma. We observed that the most common benign salivary gland tumor was pleomorphic adenoma, which is seen in 33 cases (82.5%) followed by warthin's tumor which is seen in 3 cases (7.5%). The details of the number of cases in each type is shown Table 2.

Table 2: Frequency and distribution of benign salivary gland tumors

Benign Tumors	No of cases	Percentage
Pleomorphic Adenoma	33	82.5
Warthin's tumor	3	7.5
Basal cell adenoma	2	5.0
Myoepithelioma	2	5.0
Total	40	100.0

Similarly, on morphological examination we could able to identify the histological variants of malignant salivary gland tumors as Mucoepidermoid carcinoma, Adenoid cystic carcinoma, Polymorphous low grade adenocarcinoma, Carcinoma ex pleomorphic adenoma, Basal cell adenocarcinoma and Salivary duct carcinoma. Among these, the most common malignant salivary gland tumor identified is mucoepidermoid carcinoma, which is seen in 6 cases (35.2%) followed by adenoid cystic carcinoma seen in 5 cases (29.4%). The details of the number of cases in each type is shown Table 3.

The most commonly involved salivary gland among the benign tumor is parotid gland. Out of 40 benign tumors

Table 3: Frequency and distribution of malignant salivary gland tumors

Malignant Tumors	No. of cases	Percentage
Mucoepidermoid carcinoma	6	35.3
Adenoid cystic carcinoma	5	29.4
Polymorphous low grade adenocarcinoma	1	5.9
Carcinoma ex pleomorphic adenoma	1	5.9
Basal cell adenocarcinoma	1	5.9
Salivary duct carcinoma	3	17.6
Total	17	100.0

29 were observed in parotid gland. Similarly submandibular salivary gland involved by 7 benign tumors. It is observed that the least commonly involved salivary gland is minor salivary glands. The details of the number of cases in each type is shown Table 4.

The most commonly involved salivary gland by the malignant tumors is parotid gland. Out of 17 malignant tumors 13 were observed in parotid gland. However minor salivary gland was involved by 3 cases of malignant tumor. The least commonly involved salivary gland is the sublingual gland. Details of the number of cases in each type is shown Table 5. The most common benign and malignant salivary gland neoplasms were pleomorphic adenoma and mucoepidermoid carcinoma which is shown below.

The following Haematoxylin and Eosin stain show the microscopic features of Pleomorphic Adenoma shown Figure 1.

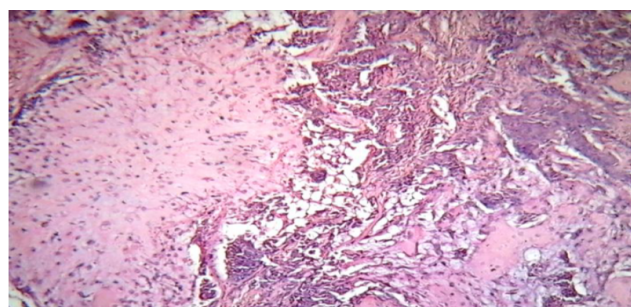


Fig. 1: Haematoxylin and eosin stain of pleomorphic adenoma (Salivary gland Tumor Magnification: 100X)

The following Haematoxylin and Eosin stain show the microscopic features of Low grade Mucoepidermoid carcinoma shown Figure 2.

4. Discussion

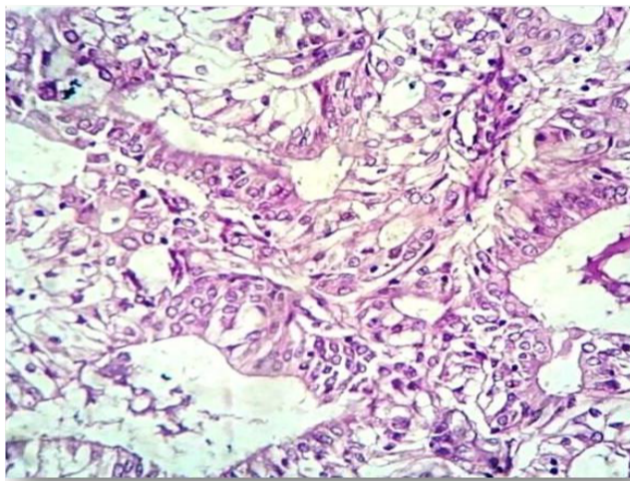
Salivary gland tumors exhibit a diverse group of benign and malignant tumors which showed multifaceted clinical pictures, different morphological architecture with unpre-

Table 4: Site wise distribution of benign salivary gland tumors

Neoplasms	Parotid	Submandibular	Sublingual	Minor salivary gland	Total
Pleomorphic adenoma	22	7	4		33
Warthin's tumour	3	-	-	-	3
Basal cell adenoma	2	-	-	-	2
Myoepithelioma	2	-	-	-	2
Total	29	7	4		40

Table 5: Site wise distribution of malignant salivary gland tumors

Malignant	Parotid	Submandibular	Sublingual	Minor SG	Total
Mucoepidermoid carcinoma	4	1	-	1	6
Adenoid cystic carcinoma	4	-	-	1	5
Polymorphous low grade adenocarcinoma	-	-	-	1	1
Carcinoma ex pleomorphic adenoma	1	-	-	-	1
Basal cell adenocarcinoma	1	-	-	-	1
Salivary duct carcinoma	3	-	-	-	3
Total	13	1	-	3	17

**Fig. 2:** Haematoxylin and eosin stain of low grade mucoepidermoid carcinoma (Salivary gland Tumor Magnification: 100X)

dictable prognostic status. Salivary gland tumors account about 0.4-13 per 1,00,000 patients per year.⁴ Among this 70-80% of tumors arises from parotid gland. Among them only 15-30% are malignant and the remaining are benign tumor. The most common benign tumor of parotid gland is Pleomorphic adenoma, and the most common malignant tumor is Mucoepidermoid carcinoma. About 50% of tumors that arising from minor salivary glands are malignant.⁵ Mucoepidermoid carcinoma, Adenoid cystic carcinoma and Polymorphous low grade adenocarcinoma are more common malignant tumors of minor salivary gland.⁶ The present study was carried on 57 consecutive cases of various types of salivary gland neoplasms. Out

of the 57 salivary gland tumors studied, 40 were benign making it 70.2% and 17 were malignant making it to 29.8% of the total salivary gland tumors. The result observed in the present study is in correlation with Janudevi et al,⁷ Juan Araya et al,⁸ Rajesh Sing et al,⁹ M.S Gill et al,¹⁰ Alpana Banerjee et al,¹¹ Nepal et al,¹² irrespective of total number of cases. The details of the number of cases in each type is shown Table 6.

The benign lesions were more common than the malignant lesions. Pleomorphic Adenoma was the most commonly observed benign tumor. Of the 40 benign tumors 33 were Pleomorphic adenomas making it 82.5% of all the benign tumors. Similar observations were quoted by Shahidaniazi et al,¹³ Shilpa H Gandhi et al,¹⁴ Shafkat Ahrnad et al.¹⁵ Mucoepidermoid carcinoma is the common malignant tumor observed in the present study. Out of 17 malignant tumors 6 were Mucoepidermoid carcinoma (35.2%). Similar observations were quoted by Khandekar et al¹⁶ Shashikala et al.¹⁷ Present study showed that the neoplastic lesions affected salivary gland was parotid gland followed by submandibular salivary gland and other minor salivary glands. Among the 57 salivary gland tumors encountered in this study it is observed that 42 cases involve the parotid gland (73.6%) and 8 cases were involve submandibular gland (14.3%). The results also showed that the sublingual and minor salivary gland are the least affected. These findings are comparable with the results of other studies quoted by Krishnaraj Subhashraj et al,¹⁸ Lakshmi Bai B Mallappa et al,¹⁹ Maj T Chatterjee et al,²⁰ Kirti N Jaiswal et al²¹ and Subhashini Bandar et al.²²

Table 6: Incidence of salivary gland tumor in various studies

S.No	Study	Place	Year	Cases	Benign	Malignant
1	Janu Devi et al ⁷	Assam	2	84	57(67.8%)	27(32.2%)
2	Juan Araya et al ⁸	Valparai sochile	11	279	196(70.2%)	83(29.8%)
3	Rajeshsingh et al ⁹	Manipur	10	104	56(53.8%)	22(21.1%)
4	M.S.Gill et al ¹⁰	Karachi	8	379	277(73.1%)	102(26.9%)
5	Alpana Banerjee et al ¹¹	Tripura	7	46	37(80.4%)	9(19.6%)
6	Nepal et al ¹²	Nepal	5	51	41(80.4%)	10(19.6%)
7	Present study	Kanchipuram	5	57	40(70.2%)	17(29.8%)

5. Conclusion

The present study results conclude that salivary gland neoplasms exhibit a varied histomorphological patterns. The most commonly observed benign and malignant salivary gland neoplasms are pleomorphic adenoma and mucoepidermoid carcinoma. Limitations of this study include a limited number of available cases of each tumor type and therefore missing of some tumor types may be due to its relatively infrequent occurrence.

6. Source of funding

None.

7. Conflict of interest

None.

References

- Nagao T, Sato E, Inoue R, Oshiro H, Takahashi RH, et al. Immunohistochemical analysis of salivary gland tumors: application for surgical pathology practice. *Acta Histochemica Et Cytochemica*. 2012;45(5):269-282.
- Oliveira FAD, Duarte EC, Taveira CT, Maximo AA, de Aquino EC, et al. Salivary gland tumor: a review of 599 cases in a Brazilian population. *Head Neck Pathol*. 2009;3(4):271.
- Barnes L, Eveson JW, Reichart P, Sidransky D. World Health Organization classification of tumours: pathology and genetics of head and neck tumours. World Health Organization Classification of Tumours: Pathology and genetics of head and neck tumors ; 2005.
- Tian Z, Li L, Wang L, Hu Y, Li J. Salivary gland neoplasms in oral and maxillofacial regions: a 23-year retrospective study of 6982 cases in an eastern Chinese population. *Int J Oral Maxillofac Surg*. 2010;39(3):235-242.
- Sun G, Yang X, Tang E, Wen J, Lu M, Hu Q. The treatment of sublingual gland tumours. *Int J Oral Maxillofac Surg*. 2010;39(9):863-868.
- Neville BW, Damm DD, Allen CM, Bouquot JE. Salivary Gland Pathology in: Oral and Maxillofacial Pathology. vol. 11. St. Louis.: Elsevier ; 2009., 3rd ed.
- Devi J, Talukdar KL. Salivary gland neoplasms: A clinicopathological study of 84 cases ;.
- Araya J, Martinez R, Niklander S, Marshall M, Esguep A. Incidence and prevalence of salivary gland tumours in. *Patologia Oral Y Cirugiabucal*. 2015;20(5):532.
- Laishram RS, Kumar KA, Pukhrabam GD, Laishram S, Debnath K. Pattern of salivary gland tumors in Manipur, India: A 10 year study. *South Asian J Cancer*. 2013;2(4):
- Gill MS, Muzaffar S, Soomro IN, Kayani N, Hussainy AS, et al. Morphological pattern of salivary gland tumours. *J Pak Med Assoc*. 2001;51(10):343.
- Banerjee A, Manasi S. Histopathological Spectrum of Salivary Gland Tumors in Tripura, India: A Seven Year Study. *J Dent Med Sci*. 2017;(16).
- Joshi RR, Nepal A, Chettri ST, Bhattarai M, Ghimire A, Karki S. Primary salivary gland tumors in eastern Nepal tertiary care hospital. *J Nepal Health Res Council*. 2010;.
- Shahidaniazi, Madihaarshad, Asifaqbal, Anumjaffery, Bokhari MH. The Morphological Spectrum of Salivary Gland. Tumours AtKemu and Mayo hospital. *Lahore Biomedica*. 2013;(29).
- Gandhi HS, Purohit TM, Deepa, Jethwani, Vidja M. FNAC Diagnosis Of Salivary Gland Lesions With Histopathological Correlation. *NJIRM*. 2013;4(3).
- Ahrnad S, Lateef M, Ahmad R. Clinicopathological study of primary salivary-gland tumors in Kashmir. *JK-Practitioner*. 2002;9(4):231-233.
- Khandekar MM, Kavatkar AN, Patankar SA, Bagwan IB, Puranik SC, Deshmukh SD. FNAC of salivary gland lesions With histopathological correlation. *Indian J Otolaryngol Head Neck Surg*. 2006;(58):3.
- Shashikala V, Rani PBS, Victor AJ. Clinicopathological study of Salivary Gland Tumors. *Int J Biomed Res*. 2016;7(9):621-623.
- Subhashraj K. Salivary gland tumors: a single institution experience in India. *Br J Oral Maxillofac Surg*. 2008;46(8):635-638.
- Mallappa LB, Balakrishna SV, Raghupathi AR. A Study of Salivary Gland Lesions-By Fine Needle Aspiration Cytology. *Int J Health Sci Res (IJHSR)*. 2014;4(4):44-48.
- Chatterjee T, Panda PK. A pathological study of benign and malignant tumours of salivary glands. *Med J Armed Forces India*. 2000;56(4):282-286.
- Jaiswal KN, Johari SP, Shrivastav AC, Shrikhande AV. Study of Salivary Gland Neoplasms. *Indian Med Gazette*. 2015;.
- Bandar S, Priyadarshinikv, Avani gaddai, Ramalaxmipv. Cytohistological study of salivary gland lesions. *J Evol Med Dent Sci*. 2016;5(103):7571-7576.

Author biography

J Margaret Theresa Assistant Professor

A B Harke Professor

Lavanya M Associate Professor

Cite this article: Theresa JM, B Harke A, Lavanya M . A study on the morphological spectrum of salivary gland tumors. *Indian J Pathol Oncol* 2020;7(1):1-4.