



## Original Research Article

# A rare case of Mucinous, tubular and spindle cell carcinoma of kidney and Histomorphological study of renal cell tumours

Lakshmi K<sup>1,\*</sup>, Leenadevi K R<sup>1</sup><sup>1</sup>Dept. of Pathology, KIMS Hospital, Trivandrum, Kerala, India

## ARTICLE INFO

## Article history:

Received 28-05-2019

Accepted 27-08-2019

Available online 22-02-2020

## Keywords:

Histomorphology

Renal cell carcinomas

## ABSTRACT

**Introduction:** Cancers of the kidney amount to 2% of total human cancer burden, with approximately 1,90,000 new cases diagnosed each year. Prognostic markers for RCC, such as tumor stage, grade, necrosis or microvascular invasion are important in determining appropriate follow up and selecting patients for adjuvant therapy.

**Aim:** Aim of the study is to analyze the clinical and histopathological variables in Renal Cell Carcinoma and establish possible correlations between them, if any. The study also highlights a rare case of mucinous tubular and spindle cell carcinoma of the kidney.

**Materials and Methods:** This is a retrospective study involving 52 cases of Renal Cell tumors diagnosed, during period of 2 years (2015-2016)

**Results:** Clear cell, Papillary, Chromophobe Carcinomas and Oncocytomas accounted for 78.85%, 7.69%, 1.92% and 7.69% of all cases, respectively.

**Conclusion:** Clear cell Carcinoma was the most common histological type, followed by Papillary Carcinoma. Majority of Clear cell Carcinomas were grade 2 with most common stage being PT1b. Tumour necrosis was common in Papillary Carcinomas. We had one case of Mucinous Tubular and Spindle cell Carcinoma which is a rare variant.

© 2020 Published by Innovative Publication. This is an open access article under the CC BY-NC-ND license (<https://creativecommons.org/licenses/by/4.0/>)

## 1. Introduction

Renal Cell Carcinoma accounts for 2% of total human cancer burden.<sup>1</sup> The peak incidence is in sixth and seventh decades of life. The male to female ratio is 1.6:1. Etiological factors include tobacco smoking and lifestyle factors. RCC is seen in a variety of inherited syndromes.<sup>2</sup>

RCC is a heterogenous disease comprising different types with specific histopathological and genetic characteristics.<sup>3</sup> 2004 WHO classification of RCC include Clear cell, Papillary, Chromophobe, Collecting duct, Medullary, Multilocular Cystic RCC, Mucinous Tubular and Spindle cell Carcinoma and Unclassified categories.<sup>2</sup> The new categories included in the 2016 WHO classification are Hereditary leiomyomatosis and renal cell carcinoma-associated RCC, MiT family translocation RCC, Succinate

dehydrogenase deficient RCC, Tubulocystic RCC, Acquired cystic disease-associated RCC and Clear cell Papillary RCC.<sup>4</sup> The Mainz classification of Renal cell tumours also include Renal Oncocytoma.<sup>5</sup> The Clear cell type accounts for 70% of all RCC's.<sup>6</sup>

In our study, we aimed to evaluate the clinical and pathological variables, such as age, sex, histologic subtype, tumour grade, pT classification, tumour necrosis and microvascular invasion, in a series of consecutive patients with RCC.

## 2. Materials and Methods

This is a retrospective study done on cases of Renal cell Carcinomas, diagnosed in the Pathology Department of KIMS hospital during a period of 2 years (2015-2016). Surgical specimens from patients who underwent radical or partial nephrectomy specimens, provided the tissue

\* Corresponding author.

E-mail address: [doclakshmi02@gmail.com](mailto:doclakshmi02@gmail.com) (Lakshmi K).

samples. These were formalin fixed, paraffin embedded followed by standard hematoxylin-eosin staining.

Clinicopathologic features like histologic subtype, nuclear grade, tumour stage, necrosis and microvascular invasion were evaluated after reviewing pathology slides and reports. Histologic subtypes were classified based upon 2004 WHO classification, tumour staging was done based on 2002 AJCC staging system, and Fuhrman nuclear grading was done.

### 3. Results

The study comprised of 52 consecutive Renal cell tumors. The peak incidence of RCC was seen in the age group of 51-60 years, consisting of 17 patients (32.69%). Thirty five(67.31%)patients were male and seventeen(32.69%)were female(ratio of 2.06:1)

Clear cell RCC was the most common type found in 41(78.85%) of cases. The other types were Papillary RCC (n=4, 7.69%), Oncocytoma (n=4, 7.69%), Chromophobe RCC variant (n=1,1.92%) and one case of the very rare Mucinous Tubular and Spindle cell carcinoma. (n=1). (Table 1)

**Table 1:**

Histological type of renal cell tumors	No. of cases
Clear cell carcinoma	41
Papillary carcinoma	4
Oncocytoma	4
Chromophobe variant	1
Mucinous,tubular and spindle cell carcinoma	1
Multilocular cystic Renal cell carcinoma	1

**Table 2:**

Stage of RCC	No.of cases
pT1a	16
pT1b	16
pT2a	3
pT2b	4
pT3a	7
pT3b	2

#### 3.1. Case report of mucinous tubular and spindle cell carcinoma of kidney

A 60 year old male presented to the urology department with an incidentally detected right renal mass. MRI abdomen and pelvis showed a mass arising from the lower pole of right kidney, which was hypointense on DW, with significant restriction on ADC map.

Laparoscopic right radical nephrectomy was done. Grossly the tumour was grey white and lobulated .Microscopy showed cuboidal cells arranged in cords and

tubules with spherical to oval nuclei and small nucleoli (Figures 1 and 2). Collection of foamy histiocytes and scattered lymphocytes were seen in between the tumour cells. Many of the areas showed spindling of cells (Figure 3). Alcian blue showed focal positivity for extracellular mucin.(Figure 4)

A diagnosis of Mucinous, tubular and spindle cell carcinoma of the kidney was given.

#### 3.2. Clear Cell RCC

On Gross examination specimens had a variegated appearance with some showing cystic areas. There were different growth patterns including alveolar, acinar, solid and mixed. Most of them showed capillaries and thin walled blood vessels in the supporting stroma- which is a helpful diagnostic feature. The cytoplasm of the cells is rich in lipids, and glycogen, which dissolved during processing and gave the characteristic clear appearance. Many of the cases also exhibited an eosinophilic cytoplasm. Nuclear pleomorphism was seen, according to the grade of the tumour. One case exhibited sarcomatoid differentiation.

#### 3.3. Papillary RCC

Papillary RCC was found in 4 cases (7.69%). Grossly the tumours were variegated with hemorrhagic and necrotic areas. Papillae contained a delicate fibrovascular core and aggregates of foamy macrophages. Necrosis and hemorrhage were seen. Tumour cells varied from small size with scanty cytoplasm and high NC ratio to larger cells with abundant eosinophilic cytoplasm. Calcific concretions were noted.

#### 3.4. Oncocytoma

Oncocytoma was found in 4 cases (7.69%) of the patients studied. Gross showed tan brown areas with central fibrotic scar in some. Solid compact nests of cells were seen, with strongly eosinophilic granular cytoplasm; Most of the cells showed uniform round nuclei, evenly dispersed chromatin and small nucleoli. Some of the cells showed bizarre enlarged nuclei; but mitoses were rare. Stroma was edematous in some areas.

#### 3.5. Chromophobe RCC variant

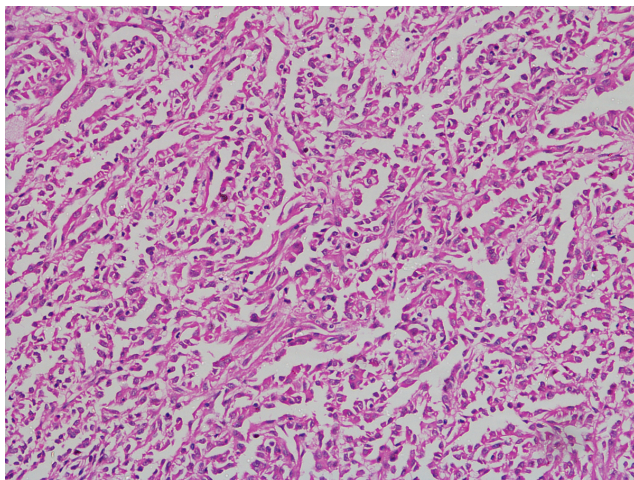
Chromophobe RCC variant was seen in 1 case(1.92%). Cut surface showed grey white, brownish and hemorrhagic areas. Microscopy showed a solid growth pattern. Neoplastic cells had abundant pale eosinophilic cytoplasm with a perinuclear halo. The cells also had distinct borders. This case also showed focal sarcomatoid differentiation. Hales colloidal iron stain was positive in this case which is used to differentiate it from oncocytomas.

We also encountered one case of Multilocular Cystic RCC. Of all the clear cell carcinomas, 28 cases (68.29%) were fuhrman nuclear grade 2; and 10 cases (24.39%) were grade 3 and 3 cases (7.3%) were grade 1. Of all the Papillary RCCs, 2 cases(50%) were nuclear grade 2 and other 2 cases(50%)were grade 3.

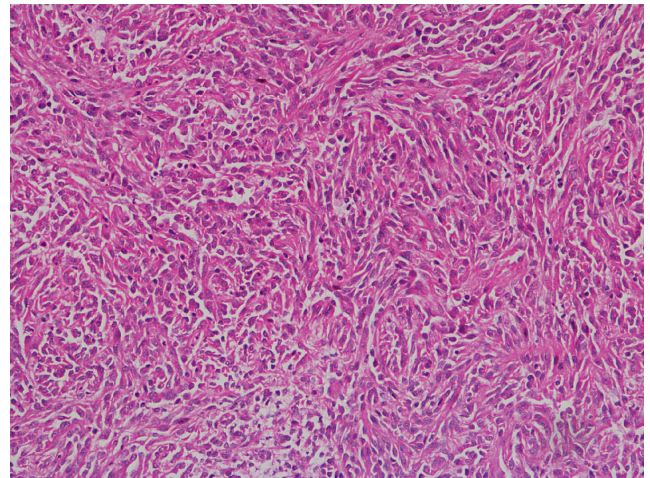
A proper TNM staging could not be done because of the inconstant clinical data regarding metastasis. So we categorized the patients according to the pT stage and nodal stage

There were 16 cases (33.33%) each in PT1a and pT1b.3 cases (6.25%), 4 cases (8.33%), 7 cases (14.58%) and 2 cases (4.17%) belonged to Tt2a, T2b, T3a, and T3b respectively. The Mucinous, Tubular and Spindle cell carcinoma was T2a stage. Only one case showed regional node metastasis.(Table 2)

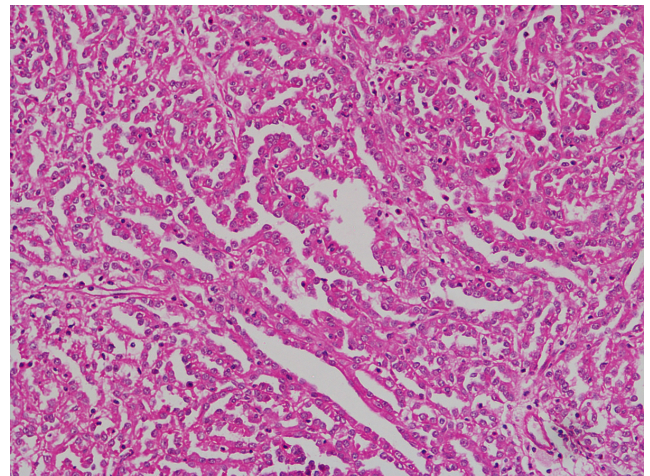
Tumour necrosis and microvascular invasion were also evaluated. There were 7 cases with tumour necrosis, of which 4 were clear cell carcinomas. Microvascular invasion was present in 3 cases.



**Fig. 1:** Mucinous tubular and spindle cell carcinoma, cells arranged in tubules



**Fig. 2:** Mucinous tubular and spindle cell carcinoma, cells with spindling

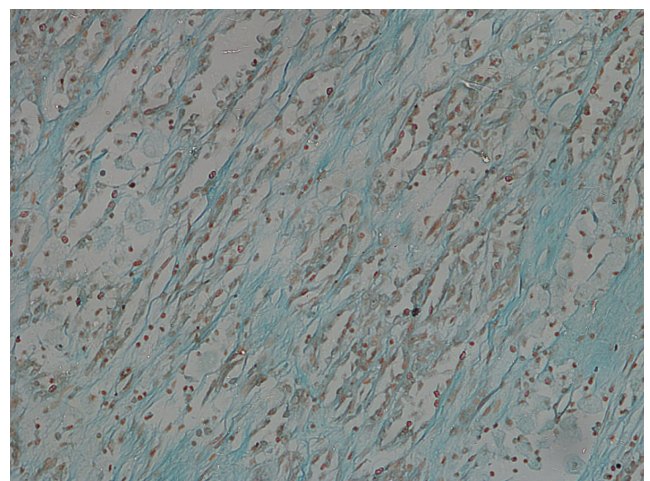


**Fig. 3:** Mucinous tubular and spindle cell carcinoma, cells in cords

#### 4. Discussion

Renal cell carcinoma is the most common malignancy of human kidney. It remains a major source of morbidity and mortality.<sup>7</sup> Tumour stage, size, histologic subtypes and nuclear grades are the most important pathologic prognostic indicators for RCC.<sup>6</sup>

The first parameter considered for pathologic evaluation was the histologic subtype. The main subtype encountered in our case series was Clear cell Carcinoma, followed by Papillary carcinoma. This was similar to other referenced reports and reviews.<sup>6</sup> The frequency of Chromophobe RCC was less in our study. Histologic subtyping of RCCs has a significant role in patients' overall outcome because of



**Fig. 4:** Alcian blue positive extracellular mucin



their implications in the prognosis and treatment.<sup>8</sup> Clear cell carcinomas have a less favourable prognosis than other subtypes like Papillary and Chromophobe RCCs.<sup>9</sup>

Another factor implicated in the poor outcome is the sarcomatoid dedifferentiation, which was noted in 2 cases in our study. This is also associated with decreased response to immunotherapy treatments.<sup>10</sup> Sarcomatoid differentiation is seen in 5% of Renal cell carcinomas and can be observed in any of the subtypes. Renal cell carcinomas with sarcomatoid differentiation has other adverse pathologic features like tumour size, extension into perinephric fat and vessels, hemorrhage and necrosis. There is an increased likelihood of distant metastasis and carcinoma specific deaths.<sup>11</sup>

There was one case of Mucinous, Tubular and Spindle cell carcinoma, in our study. It is a rare and recently described subtype of RCC. Less than hundred cases have been reported in the literature.<sup>12</sup> It shows a female predominance and affects adult population cut surface is usually bulging with tan, grey or pale yellow colour. Foci of hemorrhage or necrosis may be seen.<sup>2</sup>

Histologically the tumour is characterized by cuboidal cells arranged in cords and tubules with transition to spindle cell areas. Papillary projections protruding into the tubular lumen may be seen as a minor component, as was found in our case. Extracellular mucinous or myxoid matrix are usually abundant.<sup>12</sup>

A so called “mucin poor” pattern of Mucinous, Tubular and Spindle cell carcinoma has recently been described where there is little or no extracellular mucin appreciable on light microscopy. Alcian blue stain can highlight the scant mucin in the tumour. Our case belonged to the mucin poor category. The tumour cells are usually bland with low nuclear grade. Mitoses and necrosis are uncommon. Stromal changes other than myxoid degeneration that can be seen in MTSRCC are collections of foamy macrophages, lymphocytic infiltrate at the periphery, psammoma bodies and heterotopic bone. MTSRCC in its classic form does not pose a diagnostic problem. But predominance of spindle cells and paucity of mucin can cause diagnostic dilemma.<sup>13</sup> When the spindle cells predominate, the most important differential diagnosis is Sarcomatoid RCC, which can be excluded by the lack of pleomorphic nuclei, mitotic activity or necrosis. The prognosis is generally favourable and complete surgical excision is the mainstay of treatment.<sup>12</sup>

Tumour grading is an important prognostic tool. Fuhrman nuclear grading is based on nuclear characteristics like size, contour and nucleoli.<sup>6</sup> Most of the cases in our study belonged to grade 2. There was no difference between the predominant nuclear grade in papillary and clear cell carcinomas. This was not in correlation with other studies, where Papillary carcinomas mostly belonged to grade 3.<sup>14</sup> This discrepancy must be because of the fewer number of patients in the Papillary carcinoma group.

In our study, only seven cases showed tumour necrosis. Tumours with coagulative necrosis tend to be associated with a higher grade and advanced tumour stage.<sup>15</sup> These results were comparable with those of other studies. Histologic tumour necrosis should be routinely reported because it is an independent predictor of outcome in clear cell and chromophobe RCCs.<sup>16</sup>

Microvascular invasion is associated with higher risk for the development of metastatic disease and is an independent predictor of disease recurrence.<sup>11</sup> This was demonstrated in 5.77% of our cases which was considerably lower when compared to most of the studies. This might be because we were depending on the routine Hematoxylin & Eosin method instead of immunohistochemistry.

## 5. Conclusion

RCCs have characteristic histomorphological features and biologic behaviour. The main histologic subtype encountered in our study was Clear cell Carcinoma. Most of the clear cell carcinomas belonged to nuclear grade 3. We had a case of Mucinous, Tubular and Spindle cell carcinoma which is a rare entity. Our study also showed that tumour necrosis was associated with a higher grade and tumour stage.

## 6. Source of funding

None.

## 7. Conflict of interest

None.

## References

1. Bukowski RM, Negrier S, Elson P. Prognostic factors in patients with advanced renal cell carcinoma: development of an international kidney cancer working group. *Clin Cancer Res*. 2004;10:6310–6324.
2. Eble JN, Sauter G, Epstein JI. WHO classification of Tumours of the urinary system and male genital organs. Lyon, France: IARC press ; 2004.
3. Kovacs G, Akhtar M, Beckwith BJ. The Heidelberg classification of renal cell tumours. *J Pathol*. 1997;183(2):131–133.
4. Moch H, Peter A, Humphrey. WHO classification of Tumours of the Urinary system and Male genital organs ; 2016.
5. Diaz JJ, Mora LB, Hakam A. The Mainz classification of Renal cell Tumours. *Cancer Control*. 1999;6:571–579.
6. Stinga ASAC, Stinga M, Cruce. Histopathological study of Renal cell carcinoma. *Curr Health Sci J*. 2016;42(4).
7. Kontak JA, Campbell S. Prognostic factors in Renal cell carcinoma ; 2003.
8. Muglia VF, Prando A. Renal cell carcinoma, histological classification and correlation with imaging findings. *Radiologia Brasileira*. 2015;48(3):166–174.
9. Amin AB, Tamboli P, Menon M. Prognostic impact of histologic subtypes of adult renal epithelial neoplasms; an experience of 405 cases. *Am J Surg Pathol*. 2002;26:281–291.
10. Cheville JC, Lohse CM, Zincke H. Comparison of outcome and prognostic features among histologic subtypes of Renal cell carcinoma. *Am J Surg Pathol*. 2003;27:612–624.
11. Oglio MD, Antunes AA. Microvascular tumour invasion in renal cell carcinoma, The most important prognostic factor. The most important



- prognostic factor. *BJU Int.* 2007;100(3):552–555.
12. Zhao M. Xiang-lei He, Mucinous, Tubular and Spindle cell carcinoma. A review of clinicopathologic aspects. *Diagnostic Pathol.* 2015;10:168.
  13. Fine SW, Argani P, Marzo AMD. Expanding the histologic spectrum of Mucinous, Tubular and Spindle cell carcinoma: a report of 15 cases and a review of literature. *Virchow Arch.* 2005;447(6):978–983.
  14. Patard JJ. Prognostic value of histologic subtypes in Renal cell Carcinoma, A multicenter experience. *J Clin Oncol.* 2005;23:2763–2771.
  15. Park WH, Eisen T. Prognostic factors in Renal cell carcinoma. *BJU Int.* 2007;99:1277–1281.
  16. Sengupta S, Lohse CM. Histologic Coagulative Tumour necrosis as a prognostic indicator of Renal cell carcinoma aggressiveness. *Cancer.* 2005;104:511–520.

### Author biography

**Lakshmi K** Senior Resident

**Leenadevi K R** Senior Consultant

**Cite this article:** Lakshmi K , Leenadevi K R . A rare case of Mucinous, tubular and spindle cell carcinoma of kidney and Histomorphological study of renal cell tumours. *Indian J Pathol Oncol* 2020;7(1):176-180.