



Original Research Article

Study of birth anomalies in twin pregnancies

Kasturi Kshitija¹, Ruchi Nagpal^{1,*}, Seethamsetty Saritha², Sheshagiri Bhaskar³¹Dept. of Pathology, Bhaskar Medical College & General Hospital, KNR University, Hyderabad, Telangana, India²Dept. of Anatomy, Kamineni Academy of Medical Sciences & Research Centre, Hyderabad, Telangana, India³Dept. of OBG, Maternity Hospital, Hyderabad, Telangana, India

ARTICLE INFO

Article history:

Received 29-07-2019

Accepted 11-10-2019

Available online 22-02-2020

Keywords:

Monozygotic (MZ)

Dizygotic (DZ)

Twin to twin transfusion syndrome (TTTS)

Twin reversed arterial perfusion sequence (TRAP sequence)

Congenital anomalies (CAs)

ABSTRACT

Introduction: Twin pregnancies with congenital malformations in fetuses is associated with higher morbidity and mortality both for the mother as well as the child. Its incidence is 4 times more common than single births. This study highlights rare anomalies and complications in twins.

Materials and Methods: This is a prospective study which includes women with twin pregnancies diagnosed in first trimester by sonography. The cases were collected from a maternity hospital over a period of one year. Details of gestational age, gender, zygosity, chorionicity, anomalies and complications of the twins were taken into account along with age and parity of the mother.

Results: Out of 2023 pregnancies 41 were twin pregnancies in which 23 were dizygotic twins and 18 were monozygotic twins based on Weinberg formula. Congenital anomalies and fetal complications were observed in 4 cases (17.39%) of dizygotic twins and 8 cases (44.44%) of monozygotic twins. The affected twins predominantly belonged to female sex. Monozygotic twins showed TRAP Sequence with Acephaly and Twin to twin transfusion syndrome in 2 and 3 pairs respectively. Pregnant women with twins were between 25 to 40 years of age group.

Conclusion: Twinning rate was 20.26/1000 deliveries. Central nervous system anomalies were seen in women with no folic acid intake preconceptionally. Complications and anomalies were among monozygotic twins. Therefore chorionicity of the placenta should be detected in first trimester of pregnancy in order to prevent fetal deaths by undertaking appropriate medical measures.

© 2020 Published by Innovative Publication. This is an open access article under the CC BY-NC-ND license (<https://creativecommons.org/licenses/by/4.0/>)

1. Introduction

Birth anomalies which are more frequent in twins than single births present defective morphogenesis during early fetal life. All the twin pairs share a common environment in the uterus. Division of a zygote resulting from the fertilization of single ovum by a sperm leads to MZ twins. Genetically these twins are similar in every detail and hence are of same sex. DZ twins occur when two eggs are fertilized by two different sperms. Here the genetic makeup is not similar and thus they are nonidentical or fraternal twins. Further more they may be the same sex or be a male and female pair. DZ and MZ twins account for 66.7%

and 33.3% of twin pregnancies respectively. The type of placentation is determined by the chorionicity. Twins with single chorion are always MZ and those with two chorions may not only be MZ but also DZ.¹ In the present world, the frequency of twinning continues to rise due to mothers becoming pregnant in late stages of reproductive life with the help of ovulation inducing drugs along with contributing hereditary factors. In Northern Europe twinning rate is 1 in 80 of all pregnancies. Incidence of MZ and DZ twinning are 1 in 300 and 1 in 100 to 500 of pregnancies respectively. If the zygote division is delayed for more than 14 days after conception, conjoined twins occurs with a prevalence of one in every 50,000 pregnancies.¹ Twin pregnancies in India complicates 1% of pregnancies and are the cause of 10% perinatal mortality.² Fetal malformations and mortality

* Corresponding author.

E-mail address: ruchi2001@gmail.com (R. Nagpal).

occur more frequently in MZ twins compared to DZ twins.

2. Materials and Methods

The present study was done for a period of one year. The data was collected from a maternity hospital in Hyderabad. The study was designed to know about the spectrum of CAs in first and second trimester which were identified prenatally by Ultrasound and Targeted Imaging for Fetal Anomalies scan following which a regular follow up was done. Medical termination of Pregnancy was done in these cases with due consent of women in confinement. Some Twin pregnancies had spontaneous abortion or premature delivery. Twin pregnancies with severe congenital anomalies and complications were included in the study and singleton pregnancies with fetal malformations were excluded. Fetal information about age, gender, born alive or aborted and the type of anomaly involved was recorded. Chorionicity was determined antenatal by ultrasound scan. Single placental mass with lack of twin peak sign indicated monochorionicity whereas double placental masses with a twin peak sign indicated dichorionicity. To estimate the proportion of MZ and DZ twins, Weinberg formula was used. Accordingly, an equal number of SS twin pairs and OS twin pairs are assumed to be DZ. The remaining SS twin pairs are considered MZ. Maternal details included the age of the mother, parity, family history of twin pregnancy, preconception folic acid supplementation and assisted reproduction technologies. The results were analyzed by simple statistical techniques. Fetuses with anomalies are sent to the Anatomy/Pathology department with written consent from the parents for academic purpose. It was also approved by the ethical committee with registration number ECR/58/Inst/AP/2013/RR-16.

3. Results

There were 41 twin pregnancies (2%) from a total of 2023 pregnancies during one year study. From 41, the DZ and MZ twins were 23 (56.09%) and 18 (43.9%) respectively. CAs were observed in 4 cases (17.3%) of DZ twins and 8 cases (44.44%) of MZ twins (Figure 1). From 4 cases of DZ twins, there was 1 pair (25%) of female sex, 1 pair (25%) of male sex and 2 pairs (50%) of opposite sexes. All these pairs were aborted during third trimester of pregnancy except, in 1 pair where one baby of the twin was delivered alive. From 8 cases of MZ twins, there were 5 pairs (62.5%) of female sex, 2 pairs (25%) of male sex and in 1 pair (12.5%) sex was difficult to determined (Figure 2). One of these pairs was in I trimester (10 to 12 weeks), two pairs were full term, and 5 pairs were in II trimester (20 to 24 weeks). All these pairs were aborted in their respective trimester except, in 2 pairs which were in full term wherein 1 baby in each pair was delivered alive. In MZ affected twin group there were 5 monochorionic

monoamniotic and 3 monochorionic diamniotic. All the affected DZ twins were dichorionic diamniotic. CAs in MZ twins were 1 Craniorachisis, 1 Craniophagus, 1 Prune Belly syndrome and 1 Fetus papyraceus with Edward's syndrome, 2 Acardiac twins with Acephaly and 3 TTTS (Table 1). CAs in DZ twins were, 1st pair had Anencephaly in one of the twin with IUD of the other baby, 2nd pair had bilateral cystic hygroma with Turner's syndrome in one of the twin with IUD and swollen scrotum in other baby, 3rd pair had hydrocephalus in one twin with Down's syndrome with IUD in other baby and 4th pair had fetus papyraceus in one twin and the other baby was born alive (Table 2). All 41 mothers with twins were between 25 to 40yrs of age group. Mothers with affected twins were 30%, 29.4% and 25% between the age groups of 25 to 29 years, 30 to 35 years and 36 to 40years respectively. Primiparous women with affected twins were 5, of which 4 women had MZ twins and 1 had DZ twin. Multiparous women with affected twins were 7, of which 4 women had MZ twins and 3 had DZ twins. Women who did not have folic acid supplements preconception were 3 (7.3%). Family history of twin pregnancies was seen in 9 cases (21.95%) of which 2 cases (22.22%) were affected twins in multiparous women. In 7 cases (17.07%) women became pregnant with the help of ovulation induction drugs of which 3 cases (42.88%) had affected twins in primiparous women (Table 3)

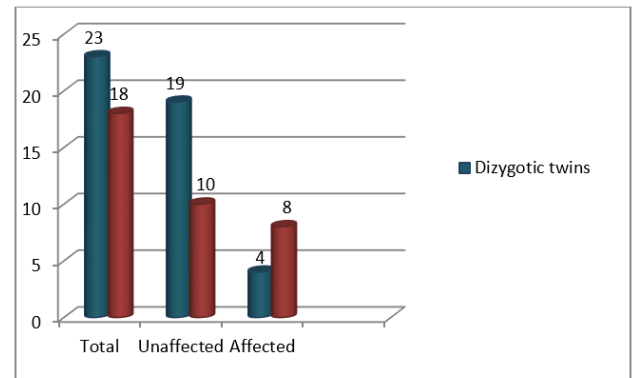


Fig. 1: Number of MZ and DZ twins

In a total of 2043 cases, multiple congenital defects were observed in 47 cases (2.3%). From this they were 41 fetal cases (87.23%) and 6 were neonatal cases (12.96%). Out of 47 cases, females were 27 (57.44%), males were 19 (40.42%) and 1 (2.12%) was ambiguous (Figure 4).

The pregnant women were between 19 to 39 years of age groups.

4. Discussion

In the 21st century incidence of twin pregnancy is on rise in India as more number of women are getting conceived in later stage of reproductive life with the help of ovulation

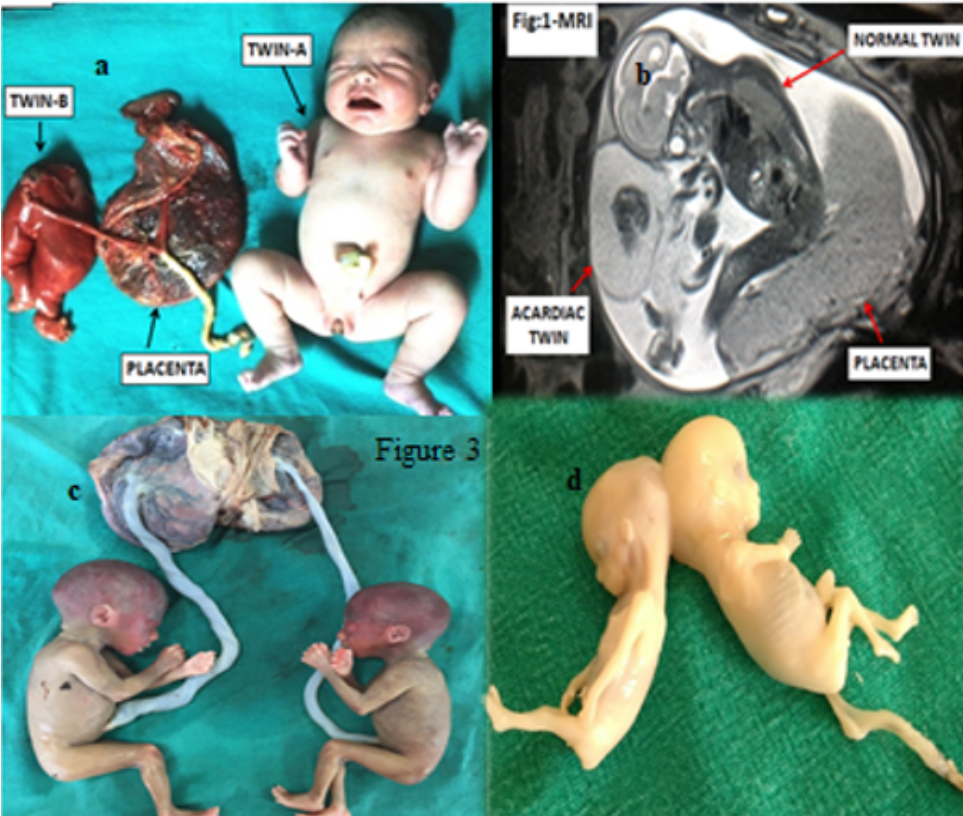

Fig. 3: (a)(b): TRAP Sequence with Acephaly; (c): TTTS; (d): Conjoint twins

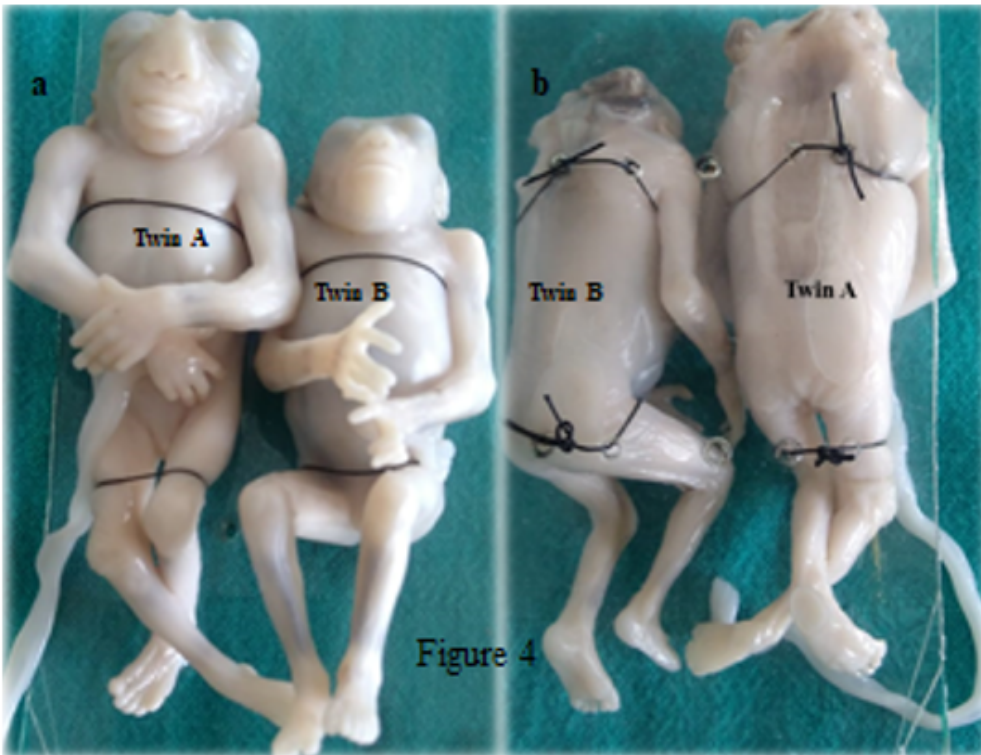


Fig. 4: Craniorachischisis (a): Anterior view (b): Posterior view

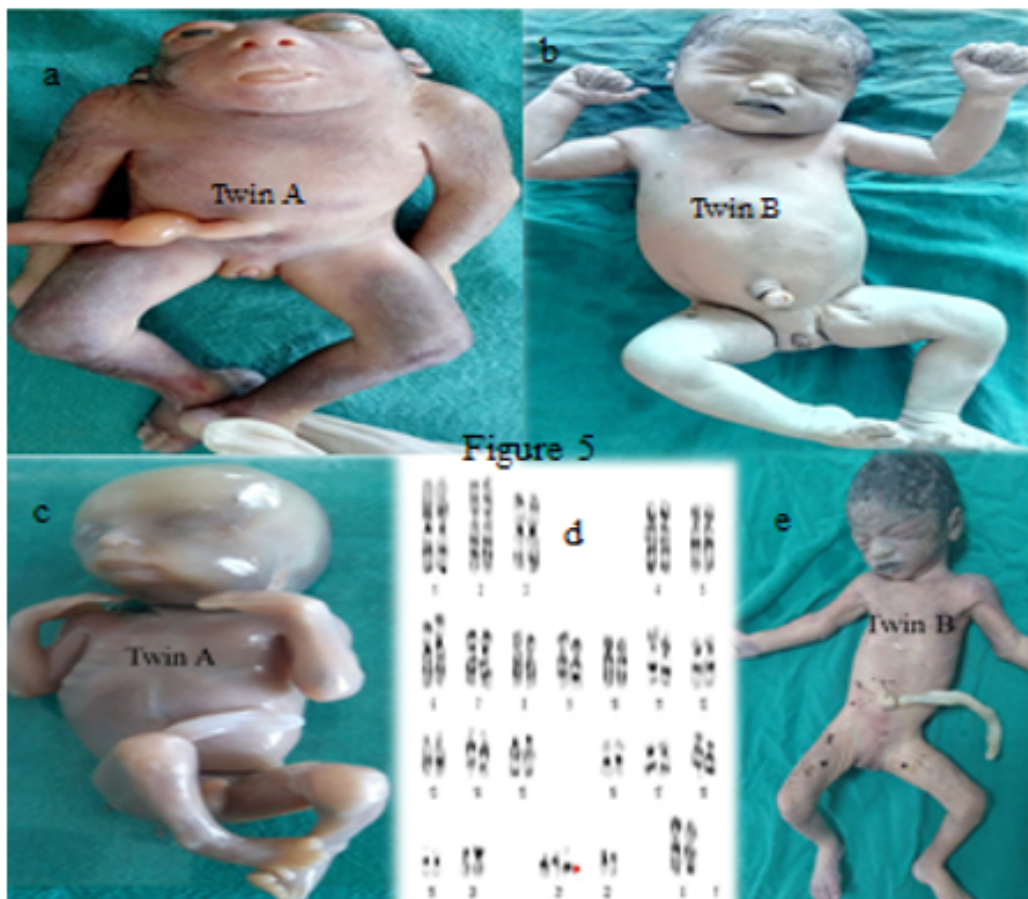

Fig. 5: DZ twins (a): Anencephaly (b): IUD (c): Hydrocephalus (d): Trisomy 21 (e): IUD

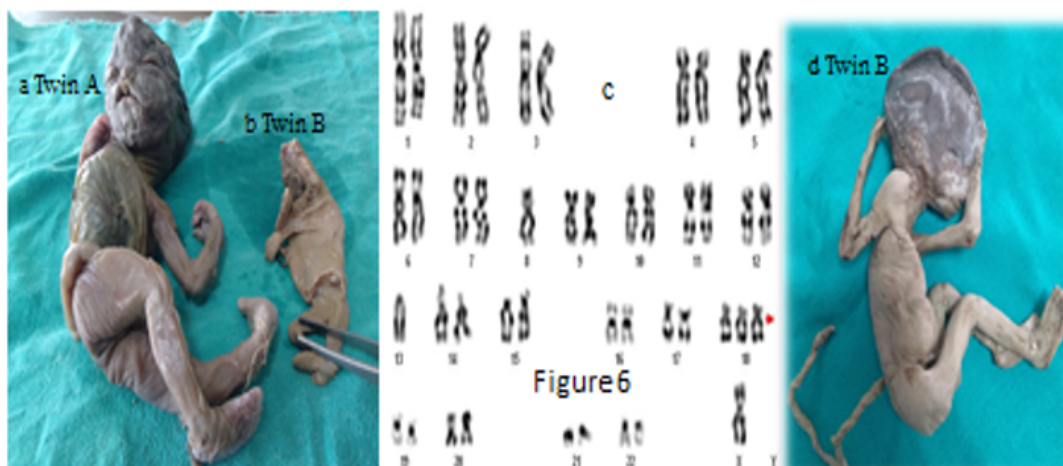


Fig. 6: MZ twins showing (a): Prune belly syndrome (b): Fetus Papyraceus (c): Trisomy 18 (d): Fetus Papyraceus in DZ twins

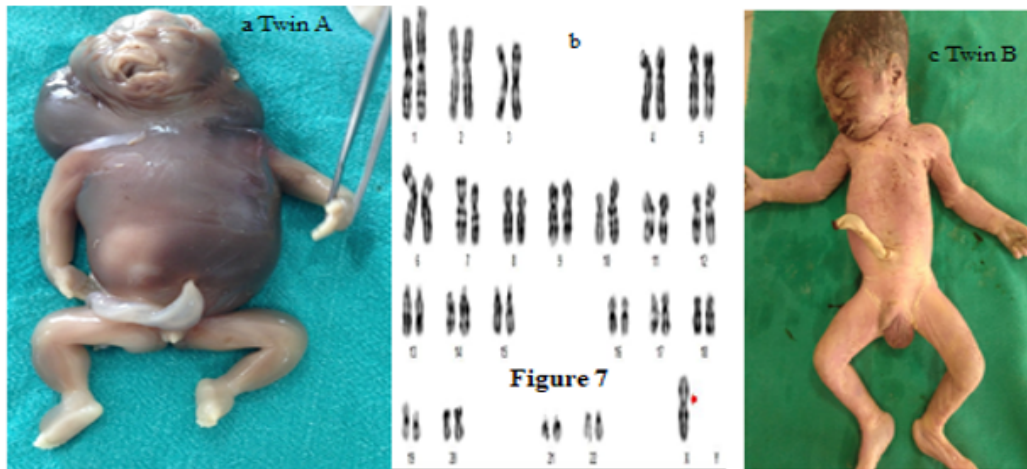


Fig. 7: DZ twins (a): Bilateral cystic hygroma (b): Turner's syndrome (c): IUD with swollen scrotum

Table 1: Showing the details of congenital defects in MZ twins

S. No.	Sex pair	Status of Twins	Gestational Age	Type of Anomaly
1.	Female	Twin A- born alive Twin B- affected	Full term	TRAP Sequence Acephaly
2	Female	Twin A- born alive Twin B- affected	Full term	
3.	Not identified	Both twins affected	20-22 weeks	Twin A-Prune belly syndrome Twin B – Fetus papyraceus Edward Syndrome
4.	Female	No external anomalies detected	20 – 24 weeks	TTTS
5.	Female			
6.	Male			
7.	Male	Both twins affected	10 -12 weeks	Craniophagus
8.	Female	Both twins affected	22- 24 weeks	Craniorachschisis

Twin A –first baby in twins, Twin B-second baby in twins

Table 2: Showing the details of congenital defects in DZ twins

S. No.	Sex pairs	Status of Twins	Gestational Age	Type of Anomaly
1	Female	Both twins affected	28 weeks	Twin A-Anencephaly Twin B -IUD
2	1 Female & 1 Male	Both twins affected	24 weeks	Twin A-Bilateral cystic hygroma Turner's syndrome Twin B –IUD
3	1 Female & 1 Male	Both twins affected	24 weeks	Twin A- Hydrocephalus Down's syndrome Twin B –IUD
4	Male	Twin A- born alive Twin B- affected	32 weeks	Fetus papyraceus

Twin A –first baby in twins, Twin B-second baby in twin

Table 3: Maternal details

S.No.	Maternal Parameters	Unaffected twins	Affected Twins	Total
1	Maternal Age			20 (48.78%)
	25 to 29 years	14 (70%)	06 (30%)	17 (41.46%)
	30 to 35 years	12 (70.6%)	05 (29.4%)	04 (9.7%)
	36 to 40 years	03 (75%)	01 (25%)	
2	Parity			18 (43.9%)
	Primiparous	13 (72.22%)	05 (27.77%)	23 (56.09%)
	Multiparous	16 (69.56%)	07 (30.4%)	
3	Family history of Twins	07 (77.77%)	02 (22.22%)	09 (21.95%)
4	Ovulation inducing drugs	04(51.14%)	03 (42.85%)	07 (17.07%)

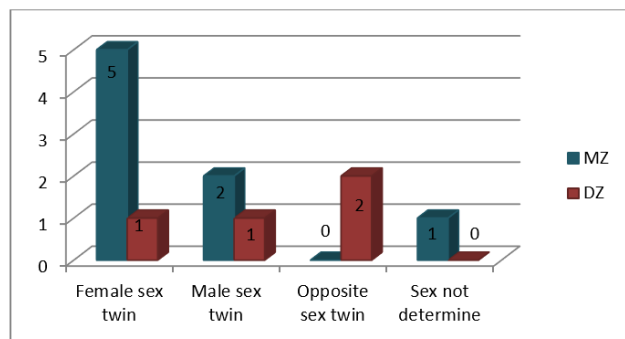


Fig. 2: Number of sex combination of twin pair

inducing drugs.^{3,4} Our study had 41 twin maternities (2.02%) in 1 year which is comparable to 1.9% reported by Upreti P and Pandey MR et al.^{4,5} Twinning rate was 20.26 per 1000 maternities with MZ and DZ twins accounting for 43.9% and 56.09% respectively which coincided with the data from Baghdadi, Ratha C, Hoffman et al that reported DZ twins as the majority group.^{6–8} Multiparous and primiparous women with affected twins were 30.4% and 27.77% respectively. All studies independent of racial distribution shows twinning to be associated with increased parity.⁶ The mean age of mothers in our study was 31 years which correlated with E. Stenhouse et al.⁹ The hereditary cause of twins in our study was 21.95% which was close to studies done by Masuda S et al (36%) and Sultana H et al (30%) respectively.^{10,11} In our study women who were conceived with the help of ovulation inducing drugs were 17.7%. This data correlated with the studies done by Masuda S et al, Sultana H et al and Satija et al.^{10–12} MZ twins have higher prevalence of CAs and fetal complication when compared to DZ twins.^{12,13} The present study observed CAs in 8 out of 18 cases of MZ twins and 4 out of 23 cases of DZ twins. This coincided with the data of Glinianaia et al.¹⁴ Identical twins have higher incidence of CAs when compared to fraternal twins as MZ twinning is itself an abnormality.¹⁵ This correlated with our findings which had same sex twins in 10 out of 12 cases. In our study female sex twins was 50% (6 out of 12 cases) which correlated with finding of Yang Yu et al.¹⁶ But this data did not correlate with Upreti P et al where male sex twin frequency was more than female sex twin.⁵

TRAP sequence is a rare vascular complication and is exclusively associated with 1% monochorionic twin pregnancies. It occurs only in 1 in 35,000 deliveries. It is characterized by presence of vascular anastomosis between the Acardiac and the healthy fetus putting the latter at the risk of cardiac failure leading to 50% mortality rates.¹⁷ Acardius-acephalus is the common presentation in the parasitic twin in which no cephalic structures are present and the head and upper extremities are lacking.¹⁸ We report 2 cases of MZ twins which has TRAP sequence

with acephalus in one twin and the other twin was born full term alive (Figure 3). TTTS is a serious progressive disorder complicating 15% of twins with monochorionic diamniotic placenta.³ It results from abnormal blood vessel connections in the placenta which allows blood to flow unevenly between the babies. Mortality rates are very high in untreated cases.¹⁹ There were 3 cases of monochorionic diamniotic twins showing TTTS with a pair and 2 pairs of male and female sex foetuses respectively. All have undergone spontaneous abortion in second trimester. (Figure 3)

Conjoined twins are extremely rare phenomenon seen in MZ twins occurring once in every 50,000 to 100,000 live births.²⁰ Mathew R.P et al reported 1 case each of cephalopagus, thoracopagus and omphalopagus over a period of 6 years.²⁰ Tang Y et al reported conjoint twins in 0.284/10,000 births over a period of 8 years.²¹ We report a case of Craniopagus in MZ male sex twins aborted in first trimester (Figure 3).

Twin studies with regards to neural tube defects (NTD) is twice more common for MZ twins compared to DZ twins. Its also more common in female sex than male sex.²² According to Glinianaia et al in twins occurrence of anencephaly and hydrocephalus was more frequent than defects in spinal cord.¹⁴ Craniorachischisis is severe form of NTD. In a study done by Sebastiano Bianca et al craniorachischisis was seen in one twin and heterotaxia in other twin.²³ We report a female sex MZ twins with craniorachischisis extending upto lumbar region in one twin A and upto cervical region in twin B aborted in II trimester (Figure 4). In 1 DZ female sex twin there was anencephaly in twin A with intrauterine death (IUD) in twin B. In the other opposite sex DZ twin there was. Hydrocephalus with Down's syndrome in twin A and IUD in the twin B. Both DZ twins were aborted in II trimester (Figure 5). In all 3 cases mother did not have folic acid supplements.

Fetus papyraceus is a compressed fetus in twin pregnancy where one fetus gets completely pressed against uterine wall by a living fetus. It is an infrequent phenomenon occurring once in every 184 to 200 twin pregnancies. It has more complications in monochorionic than dichorionic pregnancies.²⁴ We had 1 case of Prune belly syndrome in twin A and fetus papyraeus in twin B with Edward syndrome in MZ female sex twin. Other case of fetus papyraeus in twin B with alive born twin A in DZ male sex twins (Figure 6). We also reported a case of bilateral cystic hygroma with Turner's syndrome in one twin and intrauterine death with swollen scrotum in the other, of opposite sex DZ twins (Figure 7).

5. Conclusion

Currently multiple pregnancies account for 3.2% of births globally, though the incidence appears lower in developing countries.²⁵ The twin pregnancy in our study

was 2.02%. With average age of mothers being 31 years. Twins were mostly dizygotic with abnormalities seen mainly in monozygotic twins and female sex pairs. The complications in DZ twins were intrauterine death, a Down's syndrome with hydrocephalus, a Turner's syndrome with cystic hygroma, an Anencephaly and a fetus papyraceus. TRAP sequence/Acardiac twin with acephaly, TTTS, Craniorachischisis, Prune belly syndrome with fetus papyraceus and Conjoint twins were serious complications of MZ twins. Active fetal surveillance, intervention and appropriate neonatal care can improve fetomaternal outcome.

6. Source of funding

None.

7. Conflict of interest

None.

References

1. Menasinkai SB, Dakshayani R, Chiniwar MA. Congenital malformations in multiple births. *Int J Res Med Sci.* 2013;1(3):101–106.
2. Murukesan L, Brahmanandan M. Fetal complications in twin pregnancies with special reference to chorionicity. *Academic Med J India.* 2015;3(1):13–17.
3. Chhabra S, Saharan K. Increasing burden of multiple pregnancies with inherent risks in today's era of assisted reproduction. *J MGIMS.* 2012;17(i):1–7.
4. Purnima Upreti Twin pregnancies: incidence and outcomes in a tertiary health centre of Uttarakhand, India. *Int J Reprod Contracept Obstet Gynecol.* 2018;7(9):3520–3525.
5. Pandey MR, Kshetri BJ, Dhakal D. Maternal and Perinatal Outcome in Multifetal Pregnancy: A Study at a Teaching Hospital. *Am J Public Health Res.* 2015;3(5A):135–138.
6. Ratha C, Kaul A. An analysis of pregnancy outcome in dichorionic and monochorionic twins given special antenatal and intranatal care, a four year survey. *J Obstet Gynaecol India.* 2014;64(4):256–259.
7. Baghdadi S, Gee H, Whittle MJ, Khan KS. Twin pregnancy outcome and chorionicity. *Acta Obstet Gynecol Scand.* 2003;82:18–21.
8. Hoffmann E, Oldenburg A, Rode L, Tabor A, Rasmussen S, Skibsted L. Twin Births: cesarean Section or vaginal delivery? *Acta Obstetrica et Gynecologica Scandinavica.* 2012;91:463–469.
9. Stenhouse E. Chorionicity determination in twin pregnancies: how accurate are we? *Ultrasound Obstet Gynecol.* 2002;19:350–352.
10. Masuda S, Sabera K, Rifat A, Parui A, Abu B, Siddique S. Maternal and perinatal outcome of twin pregnancy in a tertiary hospital. *Ibrahim Card Med J;*2011(2):35–39.
11. Sultana M, Khatun S, Saha AK, Akhter P, Shah AB. Maternal and perinatal outcome of twin pregnancy in a tertiary hospital. *Ibrahim Card Med J.* 2011;1(2):35–39.
12. Satija M, Sharma S, Soni RK, Sachar RK, Singh G. Twinning and its Correlates; Community- Based study in a Rural Area of India. *The value of twin surveys in the study of malformations.* 2008;80.
13. Cameron AH, Edwards JH, Derom R, Thiery M, Boelaert R. -. *Eur J Obstet Gynecol Reprod Biol.* 1983;14(5):347–356.
14. Glinianaia SV, Wright JCR. Congenital anomalies in twins: a register-based study. *Hum Reprod.* 2008;23(6):1306–1311.
15. Menasinkai BS, Dakshayani K. Congenital malformations in multiple births. *Int J Res Med Sci.* 2013;1(3):101–106.
16. Yu Y. Birth Anomalies in Monozygotic and Dizygotic Twins: Results From the California Twin Registry. *J Epidemiol.* 2019;29(1):18–25.
17. Lyn ZA, Rabetsimamanga. Twin Reversed Arterial Perfusion (TRAP) Syndrome or acardiac twin: a case report in Madagascar. *Int J Res Med Sci.* 2018;6(5):1790–1792.
18. Buyukkaya A. Twin Reversed Arterial Perfusion (TRAP) Sequence; Characteristic Gray-Scale and Doppler Ultrasonography Findings. *Iran J Radiol.* 2015;12(3):14979.
19. Edwin Thia Fetoscopic laser photocoagulation in twin-to-twin transfusion syndrome: experience from a single institution. *Singapore Med J.* 2017;58(6):321–326.
20. Mathew RP. Conjoined twins - role of imaging and recent advances. *J Ultrason.* 2017;17(71):259–266.
21. Tang Y, Zhu J, Zhou GX, Dal L, Wang YP, Liang J. An Epidemiological study on conjoined twins in China. *Zhonghua Yufang Yixue Zazhi.* 1996;41:146–149.
22. Deak KL. Further evidence for a maternal genetic effect and a sex-influenced effect contributing to risk for human neural tube defects. *Birth Defects Res Clin Mol Teratol.* 2008;82(10):662–669.
23. Bianca S. Craniorachischisis and Heterotaxia with Heart Disease in Twins: Link or Change Nature? *Congenital Heart Disease.* 2010;5(5):450–453.
24. Matovelo D. Fetus papyraceus causing dystocia in a rural setting: a case report. *J Med Case Rep.* 2015;9:178.
25. Mathew R, Wills V, Abraham J. Maternal determinants and fetal outcome of twin pregnancy: a five-year survey. *Int J Reprod Contracept Obstet Gynecol.* 2017;6(6):2459–2465.

Author biography

Kasturi Kshitija Associate Professor

Ruchi Nagpal Assistant Professor

Seethamsetty Saritha Professor and HOD

Sheshagiri Bhaskar Consultant

Cite this article: Kshitija K, Nagpal R, Saritha S, Bhaskar S. Study of birth anomalies in twin pregnancies. *Indian J Pathol Oncol* 2020;7(1):164-170.