



Case Report

Amyloid associated infiltrative cardiomyopathy with Waldenstrom's Macroglobulinemia

Poornakala S¹, Richa Bhartiya^{1,*}, Nina Desai¹, Neha Pokharna¹

¹Dept. of Pathology, Bombay Hospital And Medical Research Centre, Mumbai, Maharashtra, India

ARTICLE INFO

Article history:

Received 24-02-2019

Accepted 07-06-2019

Available online 22-11-2019

Keywords:

Amyloidosis

Lymphoplasmacytic lymphoma

Plasma cell neoplasm

Abdominal fat biopsy

Biomarkers

ABSTRACT

Amyloidosis is a rare systemic disease characterised by deposition of misfolded aberrant precursor protein, which forms fibrils in beta-pleated sheets. Waldenstrom's macroglobulinemia is one of the uncommon causes of systemic amyloidosis. Diagnosis of systemic amyloidosis in Waldenstrom's Macroglobulinemia is crucial, as it is one of the indications of treatment. Biomarkers play major role in early detection of amyloidosis, which is managed by treatment of underlying plasma cell neoplasm with rapidly acting agents. Here we are presenting a case of 73-year-old male, a case systemic amyloidosis with underlying Waldenstrom's Macroglobulinemia.

© 2019 Published by Innovative Publication. This is an open access article under the CC BY-NC-ND license (<https://creativecommons.org/licenses/by/4.0/>)

1. Case Report

73-year-old male came to cardiac OPD with the complaints of bilateral pedal edema, exertional breathlessness, Chest discomfort, reduced appetite and hoarseness of voice. He was an ex-alcoholic and a chronic tobacco chewer. 2D echo showed severe diastolic dysfunction with LVEF 55%. Cardiac MRI showed infiltrative cardiomyopathy characteristic of amyloidosis. Abdominal fat biopsy showed the presence of amyloid, which was confirmed by the Congo red stain. (Figures 1 and 2). X-ray chest revealed bilateral pleural effusion. Pleural fluid was tapped and cytology was unremarkable. Laboratory investigations showed CBC, routine biochemical parameters and urine routine within normal limits. However, Pro BNP was 11359 pg/ml and bone marrow aspirate smears showed lymphocytosis (45%) (Figure 3). In view of amyloid associated infiltrative cardiomyopathy, bilateral pleural effusion and lymphocytosis on bone marrow aspiration, a diagnosis of Waldenstrom's Macroglobulinemia was suggested and Bone marrow biopsy confirmed it to be a low-grade

lymphoplasmacytic lymphoma. The immunophenotype showed CD 20 expression in lymphoid cells and the plasma cells were positive for CD38, IgM and MUM1 (focal). Free Light Chain Kappa was 35.93mg/L, Free Light Chain lambda was 139.8mg/L and kappa/lambda ratio was abnormal (0.25). Serum protein electrophoresis showed M band (1.2gms%) in gamma globulin region and Immunofixation electrophoresis confirmed the presence of IgM lambda band. (Figure 4). Thus the final diagnosis was systemic amyloidosis associated with Waldenstrom's macroglobulinemia.

2. Discussion

Waldenstrom's Macroglobulinemia is an indolent disease, which does not require treatment always. However, Coexistent Systemic Amyloidosis, which is reported in nearly 3% patients, is one of the indications for treatment.¹

Amyloidosis is a rare systemic disease characterised by misfolding of aberrant precursor protein forming unstable aggregates, which results in the formation of beta-pleated sheets.² It involves major organs like heart, kidney, peripheral nerves, GIT etc. Systemic light

* Corresponding author.

E-mail address: richabhartiya2006@gmail.com (R. Bhartiya).

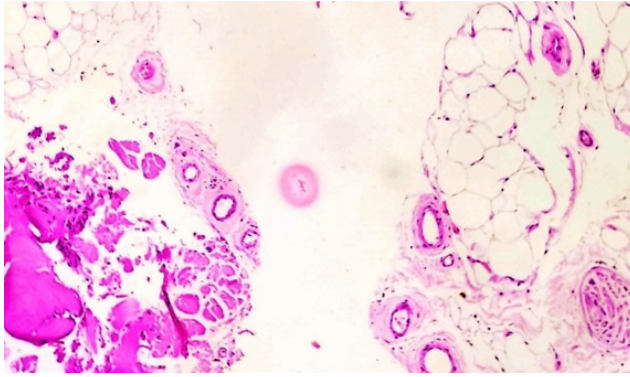


Fig. 1: Abdominal fat biopsy showing amyloid (H and E, x100)

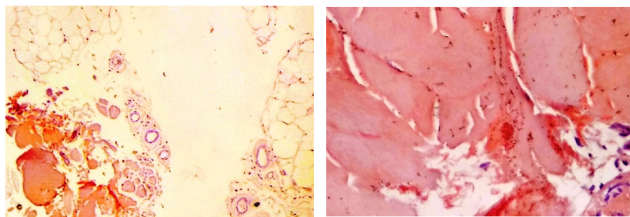


Fig. 2: Amyloid stained with Congo red (a: Congo red, x100 and b: Congo red x400)

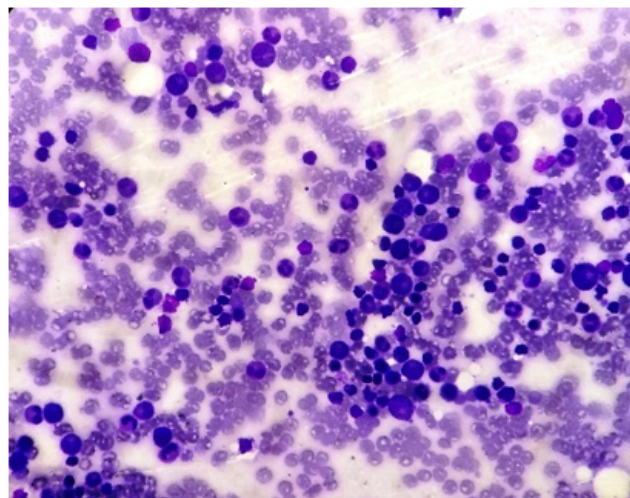


Fig. 3: Bone marrow aspirate showing lymphocytosis (Wright, x400)

chain amyloidosis (AL) is the most common type in which amyloid protein is secreted by underlying plasma cell neoplasm. However, IgM associated amyloidosis is uncommon representing 4-7% of all cases of AL amyloidosis. IgM amyloidosis patients have high frequency involvement of lung, lymph nodes, and peripheral nerves and have lower concentration of circulating free light chains.¹

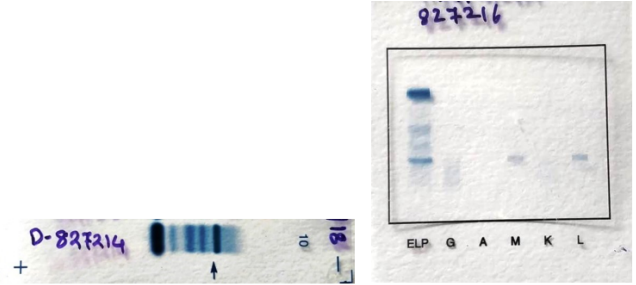


Fig. 4: a: Serum Protein Electrophoresis showing M band; b: Immune Fixation Electrophoresis showing IgM lambda band

Waldenstrom's Macroglobulinemia (WM) is defined as Lymphoplasmacytic lymphoma with bone marrow involvement and IgM monoclonal gammopathy of any concentration.³ It is a rare disease representing 2% of all cases of Non – Hodgkin's lymphoma.⁴ Diagnosis of WM requires 10% of lymphoplasmacytic lymphocytes infiltration in bone marrow and IgM monoclonal protein of any concentration. 10% cut off is emphasised by mayo clinic consensus to differentiate it from IgM MGUS.⁴ Smouldering WM is an indolent disease in which there is no evidence of end organ damage or other complications and always does not require treatment. Treatment is indicated when WM is associated with constitutional symptoms, symptomatic hepatosplenomegaly, lymphadenopathy, haemoglobin <10g/dl, platelet < 100000/ mm³, symptomatic Hyper viscosity, severe systemic neuropathy, systemic amyloidosis, or systemic cryoglobulin.⁵ Recently discovered mutations like MYD88 and CXCR4 helps in better understanding of tumourbiology.⁶

Amyloidosis associated with W M is difficult to diagnose because of the overlapping symptoms with the primary disease and the common conditions in elderly.⁷ When systemic amyloidosis is suspected, abdominal fat aspiration is the simple and least invasive procedure to confirm the diagnosis with a sensitivity of 80%.¹ Amyloid sub typing is essential, as 4%, cases can be associated with reactive amyloidosis (AA) and very rarely unrelated senile amyloidosis, which requires completely different treatment.¹

Mayo clinic group has reported 7% of IgM – MGUS patients and 2% of SWM patient's progress to develop AL amyloidosis every year.⁸ The clinical manifestations occur after significant damage to the target organs. However, biomarkers are widely available which are helpful in early detection of complications several months before the onset of symptoms. Among the various bio – markers NT-Pro BNP, BNP for heart and Urinary albumin, Serum creatinine for kidney are significant and should be done at least once in a year in individuals with serum monoclonal IgM.⁸ Early detection using biomarkers is crucial because, in the

presence of amyloidosis, rapidly acting agents are preferred to suppress the production of misfolded light chains.

3. Conclusion

This case highlights that systemic amyloidosis is an unusual presenting complication of WM and high index of clinical suspicion is essential for timely diagnosis. Biomarkers play major role in the early detection of this complex, but treatable disease.

4. Source of funding

None.

5. Conflict of interest

None.

References

1. Palladini G, Merlini G. Diagnostic challenges of amyloidosis in Waldenström macroglobulinemia. *Clin Lymphoma Myeloma Leukemia*. 2013;13(2):244–246.
2. Mahmood S, Palladini G, Sanchorawala V, Wechalekar A. Update on treatment of light chain amyloidosis. *Haematol*. 2014;99(2):209–221.
3. Campo E, Harris NL, Jaffe ES, Pileri SA, Stein H, Thiele J. WHO Classification of Tumours of Haematopoietic and Lymphoid tissues. Lyon; International Agency for Research on Cancer ; 2017,.
4. Mazzucchelli M, Frustaci AM, Deodato M, Cairoli R, Tedeschi A. Aldenstrom's macroglobulinemia: an update. *Mediterr J Hematol Infect Dis*. 2018;10(1).
5. Kyle RA, Ansell SM, Kapoor P. Prognostic factors and indications for treatment of Waldenström's Macroglobulinemia. *Best Prac Res Clin Haematol*. 2016;29(2):179–186.
6. Hunter ZR, Xu L, Yang G, Zhou Y, Liu X, et al. The genomic landscape of Waldenström macroglobulinemia is characterized by highly recurring MYD88 and WHIM-like CXCR4 mutations, and small somatic deletions associated with B-cell lymphomagenesis. *Blood*. 2014;123(11):1637–1646.
7. Amyloidosis associated with Waldenström disease or IgM-MGUS. *IWMF Torch*. 2013;14:1–4.
8. Kyle RA, Benson J, Larson D, Therneau T, Dispenzieri A, et al. IgM monoclonal gammopathy of undetermined significance and smoldering Waldenström's macroglobulinemia. *Clin Lymphoma Myeloma*. 2009;9(1):17–18.

Author biography

Poornakala S Junior Consultant

Richa Bhartiya Associate Consultant

Nina Desai Deputy Chief Pathologist

Neha Pokharna Junior Resident

Cite this article: Poornakala S, Bhartiya R, Desai N, Pokharna N. Amyloid associated infiltrative cardiomyopathy with Waldenström's Macroglobulinemia. *Indian J Pathol Oncol* 2019;6(4):714–716.