



Case Report

Vagal nerve Schwannoma- An interesting case presenting as lateral neck swelling

Ajay Kumar Thakral¹, Mohammad Jaseem Hassan^{2,*}, Divya Prasad¹¹Dept. of General Surgery, Hamdard Institute of Medical Sciences and Research (HIMSR), New Delhi, India²Dept. of Pathology, Hamdard Institute of Medical Sciences and Research (HIMSR), New Delhi, India

ARTICLE INFO

Article history:

Received 28-07-2019

Accepted 20-08-2019

Available online 22-11-2019

Keywords:

Benign tumor

Neck swelling

Schwannoma

Vagal nerve

ABSTRACT

A Schwannoma is a benign nerve sheath tumor composed of Schwann cells. Schwannoma arising from the vagus nerve is an uncommon (2–5%) benign nerve tumor. Less than 1% becomes malignant. Definitive pre-operative diagnosis may be difficult and investigations such as FNAC have low specificity. Surgical removal of tumor is the treatment of choice for vagal schwannomas with nerve preservation. Surgical removal can be done either by intra capsular enucleation or extra capsular excision of tumor. Definitive diagnosis is obtained by means of surgical pathology. Here we present a case of 40 year old male presented with swelling over antero-lateral aspect of left lower neck region for last four years with mild change in his voice for few months. CECT of the neck was suggestive of left neck cystic necrotic lesion. On FNAC the swelling was misdiagnosed as colloid nodule. The mass was excised. Grossly a single encapsulated globular cystic tissue piece measuring 8.5x7x6 cm was received in histopathology lab, which on cut section show a unilocular cyst filled with blood mixed mucoid material. On Histopathology, a diagnosis of Schwannoma was rendered.

© 2019 Published by Innovative Publication. This is an open access article under the CC BY-NC-ND license (<https://creativecommons.org/licenses/by/4.0/>)

1. Introduction

A Schwannoma is a benign nerve sheath tumor composed of Schwann cells. Schwann cells produces insulating myelin sheath which covers the peripheral nerves. Schwannomas are mostly benign and less than 1% becomes malignant.¹ Schwannoma arising from the vagus is an uncommon (2–5%) benign nerve tumor. In head and neck, extra cranial Schwannomas are more common in neck region.² Male to female predilection is 1:1.³ Definitive pre-operative diagnosis may be difficult and investigations such as FNAC have low specificity.¹ This tumor most often presents as a slow growing asymptomatic solitary lateral neck mass. Diagnosis is based on clinical suspicion and confirmation obtained by means of surgical pathology.

2. Case Report

A 40 year old male was admitted with swelling over antero-lateral aspect of left lower neck region (Figure 1). Initially swelling was small in size which was progressively increasing for last four years and reached to the size of tennis ball. Patient had mild change in his voice for few months, other than that patient had no complaint. His general physical examination and systemic examination were normal. On neck examination swelling of size around 7x 5 cms starting from near to midline of neck anteriorly up to the lateral border of sternocleidomastoid horizontally and from supraclavicular region up to mid neck region longitudinally. Temperature over the swelling was normal. Swelling was firm in consistency, well defined margins, smooth surface, with restricted mobility and not moving with deglutition and protrusion of tongue. CECT neck was suggestive of left neck cystic necrotic lesion, probably Necrotic nerve sheath tumor or Exophytic thyroid cyst (colloid goiter). FNAC was suggestive of colloid nodule.

* Corresponding author.

E-mail address: jaseemamu@gmail.com (M. Jaseem Hassan).

Blood investigations were within normal limits. On exploration there was a large swelling anterior to carotid artery and vagal nerve which was compressing internal jugular vein from posterior and displacing it laterally. Thyroid gland was normal. Internal jugular vein was densely adhering to the swelling and it was difficult to make them separate. During separation it got ruptured and we have to sacrifice internal jugular vein. After ligating the internal jugular vein proximally and distally swelling was separated from the surrounding structures. Vagus nerve was going posteriorly to the swelling. Vagus nerve was separated from swelling by extra capsular dissection and tumor was removed (Figure 2A). Proper hemostasis was achieved and wound was closed in layers after placing negative suction drain. Post-operative period was uneventful. The specimen was sent for histopathological evaluation. Grossly in histopathology lab, a single encapsulated globular cystic tissue piece was received, measuring 8.5x7x6 cm. outer surface was glistening in appearance and show congested blood vessels. Cut surface show a unilocular cyst filled with blood mixed mucoid material. The inner surface was reddish yellow in color. The wall thickness varies from 0.4-0.6 cm. On serial cutting a glistening white thickened area was seen measuring 2.5x2x1.5 cm. (Figure 2B). Microscopic Examination show a well encapsulated mass consist of hyper cellular (Antoni A) area and hypo cellular (Antoni B) areas (Figure 3A). In Antoni A areas palisading of spindle cells are seen around eosinophilic Verocay bodies. (Figure 3B). Thus a diagnosis of benign nerve sheath tumor- Schwannoma was rendered histologically.

Patient is doing well in follow up except for mild hoarseness of voice for which he is taking speech therapy and he is improving.

3. Discussion

Lateral neck swelling in adult patient is mostly lymph node enlargement which may be because of infection or malignancy and that can be primary or secondary.⁴ 75% of lateral neck masses in patients over 40 years of age are caused by malignant tumor. Infection is the most common cause of lateral neck swelling, however in absence of infection, lateral neck mass is almost always occurs either because of lymphoma or metastatic squamous cell carcinoma. Benign tumors can be sebaceous cyst, lipoma, neuroma, sympathetic neuroma, carotid aneurysm, carotid body tumor, chemodectoma, vagal paraganglioma, vagal schwannoma and few others. paraganglioma is the most common neoplasm of vagus nerve, constituting 50% cases of all vagus nerve neoplasm. Other less common vagus nerve neoplasm includes Schwannoma, neurofibroma and neurofibrosarcoma.⁵

Mostly, Schwannoma presented as slow growing painless swelling in the lateral neck with firm consistency and usually reported between third to sixth decades of life.¹

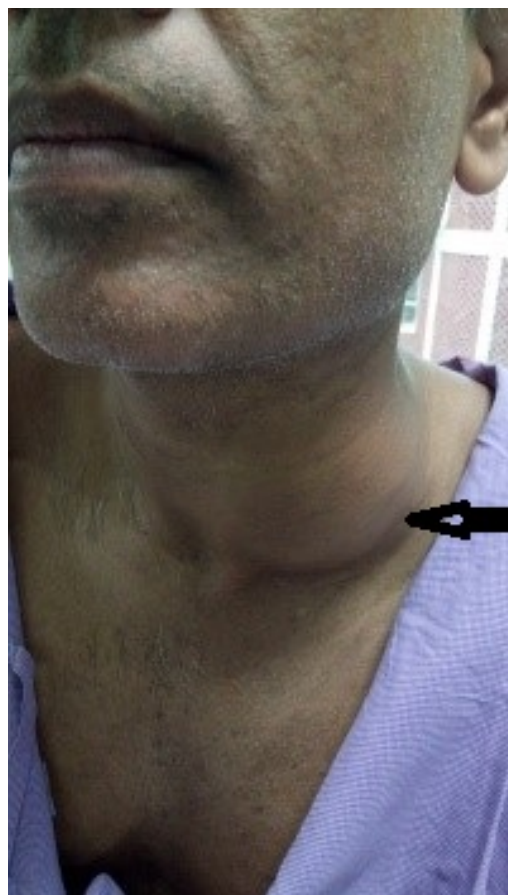

Fig. 1: Clinically picture showing swelling over anterio-lateral aspect of left lower neck region (arrow).

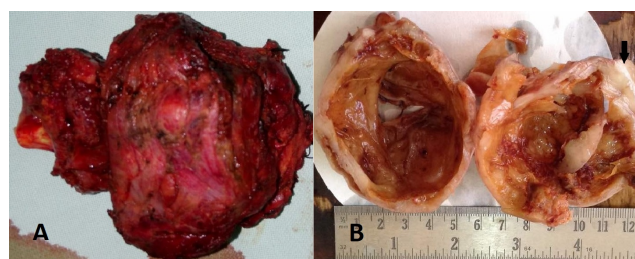


Fig. 2: (A): post-operative specimen showing a globular tissue piece. (B): Cut section show a unilocular cyst with reddish yellow in appearance. A thickened glistening white area is seen (Arrow)

Cough, hoarseness or occasionally pain may be the presenting complaints. Carotid artery is displaced anteriorly and medially by this swelling, while jugular vein is displaced laterally and posteriorly. These swellings move transversely. No vertical movement of these swelling is reported. Diagnosis is based on clinical suspicion and confirmation obtained by means of surgical pathology. Definitive pre-operative diagnosis may be difficult and investigations such as FNAC have low specificity. In

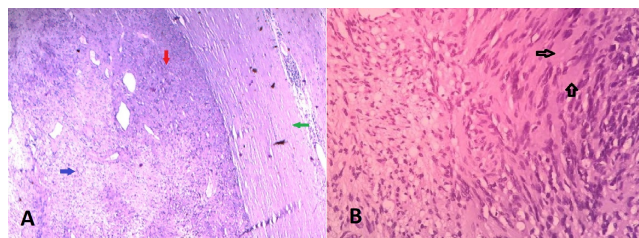


Fig. 3: (A): Histopathological section showing a well encapsulated mass (Green color arrow) with hyper cellular Antony A area (Red arrow) and hypo cellular Antoni B area (Blue arrow). (H&E x 100). **(B):** Histopathological section showing palisading of nuclei around eosinophilic Verocay body (Arrows). (H&E x 400).

our case FNAC was suggestive of colloid nodule. On contrast enhanced computed tomography images, Vagal Schwannoma show higher attenuation than muscle and they appear as well defined mass. In our case CECT neck was suggestive of left neck cystic necrotic lesion, probably Necrotic nerve sheath tumor or Exophytic thyroid cyst (colloid goiter).¹ Schwannomas of the vagus nerve must be differentiated from the carotid body and glomus vagale tumors. Both tumors enhance intensely on CT images and reveal a characteristic “salt-and-pepper” appearance. Surgical removal of tumor is the treatment of choice for vagal schwannomas with nerve preservation. Surgical removal can be done by Intra capsular enucleation or extra capsular excision of tumor. In order to save the function of the nerve, surgery is planned according to the size, location and vascularity of the tumor. The surgical planning of this tumor also depends on the relation of tumor with adjacent structures like carotid artery, jugular vein, vagus nerve and sympathetic chain.⁶ In our case we did the extra capsular excision of the tumor with ligation of internal jugular vein as it was densely adhere to the swelling and during separation it got ruptured. Postoperative complications can be hematoma formation, wound infection, hoarseness or coughing. In our case Patient had done well in follow up except for mild hoarseness. Histopathologically, Schwannoma shows both hypercellular and hypocellular areas, Hypercellular areas are known as Antoni A area and are characterised by palisading of nuclei around a central mass of eosinophilic cytoplasm known as verocay body. The hypocellular areas are known as Antoni B area and are characterised by loosely arranged stroma in which fibres and cells are arranged without any distinctive pattern.

Haemorrhage, necrosis and cystic degeneration are also seen histologically.

4. Conclusion

Definite diagnosis of Schwannoma is usually obtained by histopathology. In our case microscopic examination show a well encapsulated area consist of hyper cellular Antoni A and hypo cellular Antoni B areas. In Antoni A areas palisading of spindle cells are seen around eosinophilic Verocay bodies.

5. Source of funding

None.

6. Conflict of interest

None.

References

1. Sreevatsa MR, Srinivasarao RV. Three case of vagal nerve schwannoma and review of literature. *Indian J Otolaryngol Head Neck Surg.* 2011;63:310–312.
2. Liu HL, Sy Y, Li GK, Wei WI. Extracranial head and neck schwannomas: a study of the nerve of origin. *Eur Arch Otorhinolaryngol.* 2011;268:1343–1347.
3. Langner E, Negro D, Akashi A, Araujo HA, Tincani PP, et al. Schwannomas in the neck: retrospective analysis of 21 patients and review of the literature. *Sao Paulo Med J.* 2007;125:220–222.
4. Gleeson M, Herbert A, Richards A. Management of lateral neck masses in adults. *BMJ.* 2000;320:1521–1524.
5. Green JD, Olsen KD, Desanto LW, Scheithauer BW. Neoplasms of the vagus nerve. *Laryngoscope.* 1988;98:648–654.
6. Kim SH, Kim NH, Kim KR, Lee JH, Choi HS. Schwannoma in Head and Neck: Preoperative Imaging Study and Intracapsular Enucleation for Functional Nerve Preservation. *Yonsei Med J.* 2010;51:938–942.

Author biography

Ajay Kumar Thakral Associate Professor

Mohammad Jaseem Hassan Associate Professor

Divya Prasad Assistant Professor

Cite this article: Kumar Thakral A, Jaseem Hassan M, Prasad D. Vagal nerve Schwannoma- An interesting case presenting as lateral neck swelling. *Indian J Pathol Oncol* 2019;6(4):711–713.