



Original Research Article

The spectrum of benign breast diseases among females: A 6-year histopathological study

Shweta Pai^{1,*}¹Dept. of Pathology, East Point College of Medical Sciences & Research Centre, Karnataka, India

ARTICLE INFO

Article history:

Received 31-03-2019

Accepted 31-05-2019

Available online 22-11-2019

Keywords:

Benign breast disease

Fibroadenoma

Fibrocystic disease

Phyllodes tumor

Inflammatory breast diseases

ABSTRACT

Introduction: Benign breast diseases have become a major health issue in modern times to contend with owing to its alarming pace of increase in global prevalence and the adverse risk that it holds in turning cancerous. They account for approximately 90% of all clinical presentations related to the breast.

Objectives: 1) To study the gross and microscopic features of benign breast diseases; 2) To categorize the cases into different morphological types.

Materials and Methods: Materials for the study consisted of specimens of breast lesions received in the Department of Pathology from SS Hospital over a period of 6 years. They were processed using the routine prescribed protocol, following which a microscopic analysis of the stained smears were carried out.

Results: A total of 153 benign breast diseases were received in the department over a period of 6 years with benign to malignant ratio of 1.6:1. They were seen more commonly in the 3rd decade. The most common lesion was fibroadenoma accounting for 64.7%, followed by fibrocystic disease 16.3% and phyllodes tumor (5.2%). Other lesions noted were lactational adenoma (2.6%), gynecomastia (1.3%) and inflammatory lesions consisting of acute mastitis (3.3%), chronic mastitis (2.6%), granulomatous mastitis (3.3%) and fat necrosis (0.7%).

Conclusion: Breast lesions are a cause of concern since some carry the potential risk of turning malignant. Timely excision of lesion, evaluation and confirmation of histological findings helps us to differentiate between benign from malignant lesions.

© 2019 Published by Innovative Publication. This is an open access article under the CC BY-NC-ND license (<https://creativecommons.org/licenses/by/4.0/>)

1. Introduction

Benign breast diseases (BBD) have in recent times become a major women's health issue owing to its ever rising global prevalence, deterioration in the general quality of life in affected women and the cancerous potential that some histological subtypes carry. Globally, BBDs account for approximately 90% of all clinical case presentations related to the breast. Fibroadenoma, fibrocystic change and breast abscesses account for a good majority. Generally, when a breast lump is detected in a female, it is almost invariably regarded as benign at face value. Consequently, she may choose to refrain from any further consultations. Equally so, all lumps are not cancers. In fact, the benign lesions

out number malignant ones by a factor of ten.¹ BBDs in females are very interesting to the pathologist as they take on myriad forms of histological presentation. These variations pose a great challenge to the microscopic study of the pattern of disease and the unambiguous identification of sub-varieties. A thorough review of pathological findings in BBDs can provide insight into the exact nature of the lesion and will also serve as a means for timely decision making for the patient and the clinician. This study has therefore, been undertaken with the aim of understanding the histomorphological patterns of BBDs encountered in our institute.

* Corresponding author.

E-mail address: drshwetapai02@gmail.com (S. Pai).

2. Materials and Methods

This is a descriptive study undertaken in the Department of Pathology S.S Institute of Medical Sciences, Davangere over a period of 6 years from December 2008 to November 2014. Ethical clearance was obtained from the Institutional Ethical Committee. The materials for this study consisted of a total of 153 specimens which included lumpectomies and resected lesions of breast. These specimens were received by the Department of Pathology from patients who were operated either in SSIMS and RC or in private hospitals situated in and around Davangere during this period. Relevant clinical data was collected using requisition forms. The specimens were received in 10% formalin and allowed to fix for 24 hours. These specimens were subjected to detailed macroscopic study according to the methodology described by Schnitt SJ & Connolly JL.² On an average 3 to 4 representative bits were taken from different areas and processed routinely using automated tissue processor and paraffin blocks were made. The sections from paraffin blocks were cut at 3-5 μ thickness using Leica semi-automated microtome, stained with hematoxylin and eosin and studied under the microscope. The histomorphological findings were recorded in detail and lesions were categorized according to Dupont, Page and Rogers classification.³ Special stain (Zeil Neilson stain) was employed for granulomatous lesions. The study included those cases that were diagnosed as BBDs on histopathology irrespective of the age and excluded specimens that were known or suspected to be malignant.

3. Results

A total of 17,835 specimens were received during the study period, of which 248 (1.4%) were breast lesions. Of the 248 breast lesions, 153 (61.7%) were benign (including inflammatory and miscellaneous lesions) and 95 (38.3%) were malignant, with benign to malignant ratio of 1.6:1. [Chart 1] Of the 153 BBD specimens, 151 specimens were from females and 2 were from males. Benign lesions included fibroadenoma, benign phyllodes tumor, lactational adenoma, fibrocystic disease, acute mastitis, chronic mastitis, granulomatous mastitis, fat necrosis and gynecomastia. Malignant lesions comprised of epithelial tumors, malignant phyllodes and other sarcomas. Yearly distribution of benign breast diseases showed increasing trend over years with peak in 2012 [Chart 2].

In the present study, the profile of cases examined was as follows: fibroadenomas [99 cases (64.7%)], fibrocystic disease [25 cases (16.3%)] and benign phyllodes tumor [8 cases (5.2%)]. Less commonly encountered were inflammatory breast diseases like acute mastitis [5 cases (3.3%)], chronic mastitis [4 cases (2.6%)], Granulomatous mastitis [5 cases (3.3%)] and Fat necrosis [1 case (0.7%)]. We also came across, 4 cases of lactational adenoma (2.6%)

and 2 cases of gynecomastia (1.3%) [Chart 3]. Majority of BBDs were seen in the 3rd decade [60 out of 153 (39.2%)] and the 4th decade [42 out of 153 (27.5%)]. In both the decades, fibroadenomas were the most commonly observed lesion [Table 1]. In the current study, 144 (94.1%) lesions of BBDs were unilateral and 9 (5.9%) were bilateral.

Fifteen cases (9.8%) of inflammatory breast diseases were seen in this study. Acute and chronic mastitis showed dense infiltration of breast tissue with inflammatory cells consisting of predominantly neutrophils and lymphocytes, respectively along with stromal fibrosis in chronic mastitis cases. Granulomatous mastitis showed granulomas comprising of epithelioid cells, foreign body type of giant cells, mantle of lymphocytes and peripheral fibrosis. Ducts were dilated and showed presence of foamy macrophages. Three cases (60%) showed areas of caseous necrosis and langhans type of giant cells. Special stain (Zeil-Neilson stain) was employed to confirm diagnosis of tuberculous mastitis in these cases [Figure 1]. We also came across a single case of fat necrosis, in which adipose tissue was interspersed with granulation tissue and infiltrated by a mixture of inflammatory cells like neutrophils, lymphocytes, plasma cells, sheets of foamy macrophages and foreign body type of giant cells [Figure 2].

In our study, lactational adenomas showed closely packed hyperplastic ducts and lobules. The lining epithelial cells showed extensive secretory changes and the lumens were impacted with secretions. Additionally, we observed 3 such cases (75%) with adenosis, 2 cases (50%) with epithelial hyperplasia of glands and 1 case (25%) with apocrine metaplasia. The stroma showed fibrosis with minimal inflammatory cell infiltrate [Figure 3]. Finally, we encountered two cases of gynaecomastia, in which one had a fibroadenoma picture with apocrine change while the other had a fibrocystic pattern.

Most of the fibroadenomas were encapsulated. Their overall architecture varied with few cases showing either intracanalicular (29.3%) or pericanalicular (26.3%) pattern but 44 cases (44.4%) showed both patterns. Complex features seen were apocrine metaplasia (19 cases), cysts (22 cases), calcification (1 case) and epithelial hyperplasia (34 cases) [Figure 4]. We encountered 8 cases of phyllodes tumor in the present study. They showed overgrowth of stroma, forming leaf like projections compressing the benign ductal lining into slit like spaces with epithelial hyperplasia (37.5% cases), apocrine metaplasia (37.5% cases) and cystic dilatation (50% cases) of ducts [Figure 5]. Stromal cellularity was increased, showing spindle cells with myxoid changes and mitosis was absent.

All cases of fibrocystic disease showed variably sized cystically dilated glands, lined by flattened to cuboidal epithelial cells with dense periductal and perilobular fibrosis. Additional features observed were adenosis (68%), epithelial hyperplasia (72%) and apocrine metaplasia

(64%). Stroma was fibrocollagenous in 11 cases (44 %), hyalinised in 8 cases (32%), myxoid in 6 cases (24%) of fibrocystic disease. In 9 cases (36%) stroma showed inflammatory infiltrate consisting of lymphocytes, plasma cells, cyst macrophages and giant cells [Figure 6].

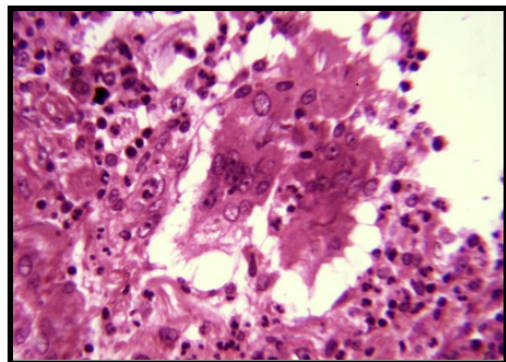


Fig. 1: Granulomatous mastitis. Multinucleated giant cells of foreign body type. H & E, HP

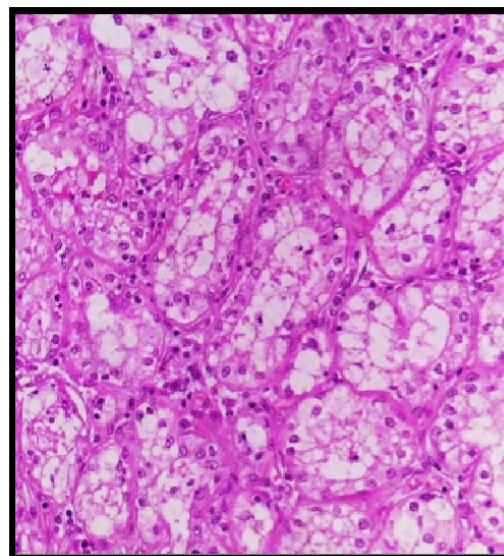


Fig. 3: Lactational adenoma. Glandular cells have vacuolated cytoplasm. H & E, HP

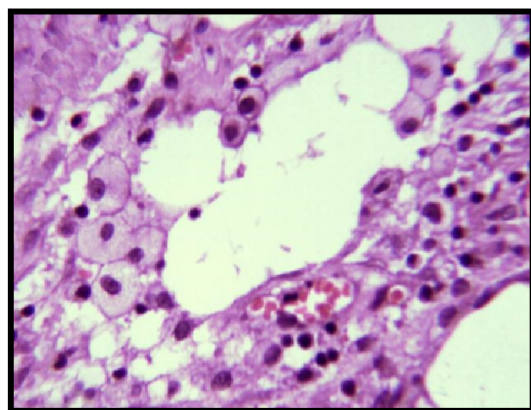


Fig. 2: Fat necrosis. Foamy histiocytes and lymphocytes infiltrating fat. H & E, HP

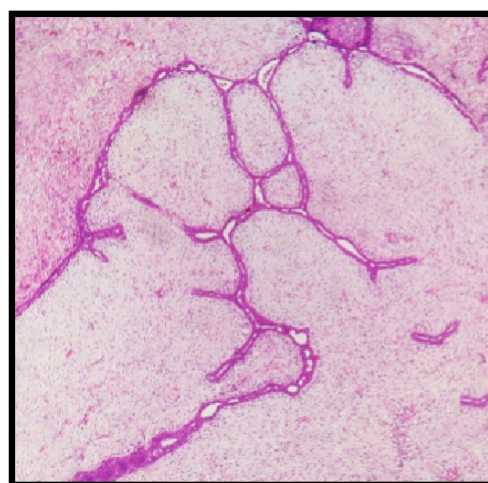


Fig. 4: Fibroadenoma. Stroma showing myxoid areas. H & E, HP

4. Discussion

Specimens of breast lesions constituted 1.4% (248/17835) of all histopathology specimens received in the Department of Pathology over 6 years. Out of 248 breast lesions 153 (61.7%) were benign and 95 (38.3%) were malignant lesions with benign to malignant ratio of 1.6:1 which was similar to the study done by Khanna et al in 1998 for a period of 20 years [Table 2].⁵ Benign breast diseases are more common compared to malignant breast diseases among women as seen in studies done by Oluwole et al and other studies which is consistent with the present study.⁴ But the study done by Batool in Lahore, Pakistan varied where malignant lesions were more common compared to benign.⁸ Among various benign lesions, it was seen

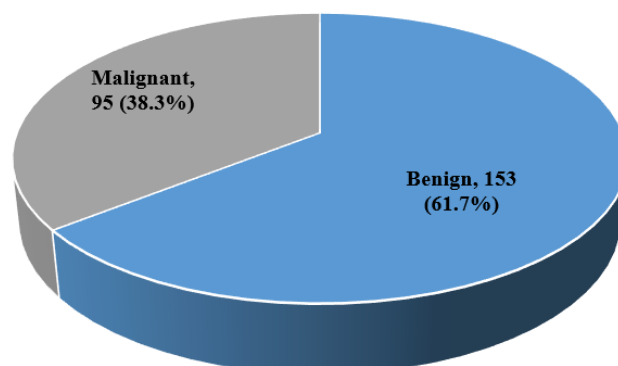


Chart 1: Prevalence of benign and malignant lesions of breast

Table 1: Age wise distribution in relation to the histologic type of benign breast lesions

Histologic type	10-19 years	20-29 years	30- 39 years	40-49 years	50-59 years	60-69 years	Total
Fibroadenoma	25	48	18	6	1	1	99
Benign Phyllodes tumor	0	1	1	6	0	0	8
Fibrocystic disease	2	4	13	6	0	0	25
Acute mastitis	2	1	2	0	0	0	5
Chronic mastitis	0	1	2	0	1	0	4
Granulomatous mastitis	0	1	3	1	0	0	5
Fat Necrosis	0	1	0	0	0	0	1
Gynecomastia	0	1	1	0	0	0	2
Lactational adenoma	0	2	2	0	0	0	4
Total	29	60	42	19	2	1	153

Table 2: Incidence of breast lesions in different studies

Study	Duration	Benign	Malignant
Oluwole et al ⁴ (1979)	3 years	72 %	28 %
Khanna et al ⁵ (1998)	20 years	61.3 %	38.7 %
Ochicha et al ⁶ (2002)	5 years	73 %	27 %
Malik R et al ⁷ (2003)	20 years	89 %	11 %
Batool ⁸ (2005)	5 years	30.7%	69.3%
Malik et al ⁹ (2010)	8 years	71.5%	28.5%
Dayan et al ¹⁰ (2013)	1 year	75.5%	24.5%
Rasheed et al ¹¹ (2014)	3 years	77.8%	22.2%
Dafe ¹² (2014)	7 years	71.2%	28.8%
Present Study	6 years	61.7%	38.3 %

Table 3: Different types of benign breast lesions

Lesions	Samir et al ¹³ (1995)	Khanna et al (1998) ⁵	Bafakeer ¹⁴ (2010)	Mc Farlane ¹⁵ (2001)	Ochicha et al ¹¹ (2002)	Okoth et al ¹⁶ (2013)	Rasheed et al ¹¹ (2014)	Present Study
Inflammatory lesions	21.2%	20 %	10.8 %	11.2%	8 %	6.7%	8.9%	9.8 %
Fibroadenoma and its variants	38%	60 %	52.3 %	33.6%	29 %	56.9%	71.4%	64.7 %
Fibrocystic disease and related lesions	25.4%	15 %	20.1 %	41.0%	34 %	20.5%	14.3%	16.3 %
Others	15.4%	5 %	16.8 %	14.2%	29 %	15.9%	5.4%	9.2 %
Total (%)	100	100	100	100	100	100	100	100

that fibroadenomas and its variants formed the majority in the present study. Similar finding was noted in other studies as well.^{8,11,13,14,16} But studies done by Ochicha and Mc Farlane differed where fibrocystic disease and related lesions predominated [Table 3].^{6,15}

In the studies conducted by various authors it was noted that benign breast lesions were more common in the 3rd decade which was also seen in the current study (39.2%).^{12,17-19} Second common age group in the current study was 4th decade similar to Ullah et al and Maychet

et al.^{17,18} However Nggada et al and Dafe et al found adolescent age group to be the second most common age group in Nigeria.^{12,19} In the current study mean age of presentation of benign breast lesions was 28.3 years. Similar finding was noted by Abhijit et al and Maychet et al.^{18,20} However Hussain et al, Godwins et al and Dafe et al had higher mean ages.^{12,21,22} Left sided lesions were more common compared to right sided in the present study, a finding which was also noted by Naveen et al while other studies like that of Usmaan et al and others showed right

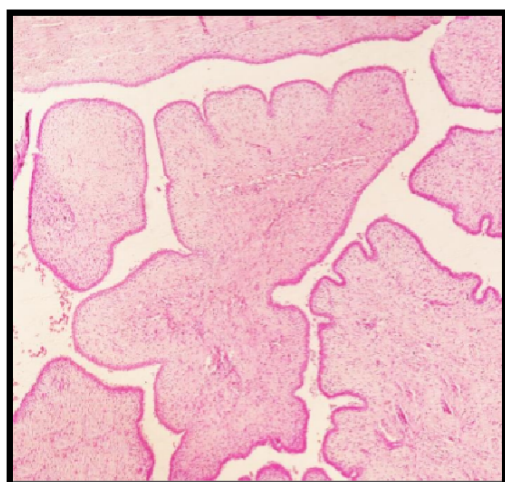


Fig. 5: Fronds of stroma covered by a thin layer of epithelium in benign phyllodes tumor. H& E, LP.

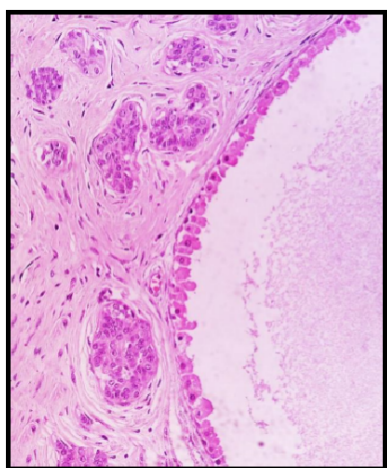


Fig. 6: Apocrine metaplasia in fibrocystic disease. H & E, HP

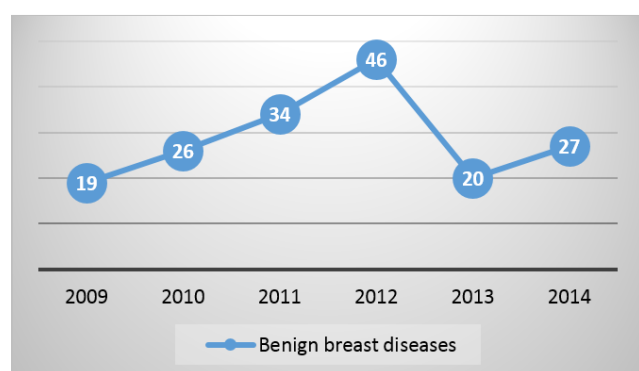


Chart 2: Yearly distribution of benign breast diseases

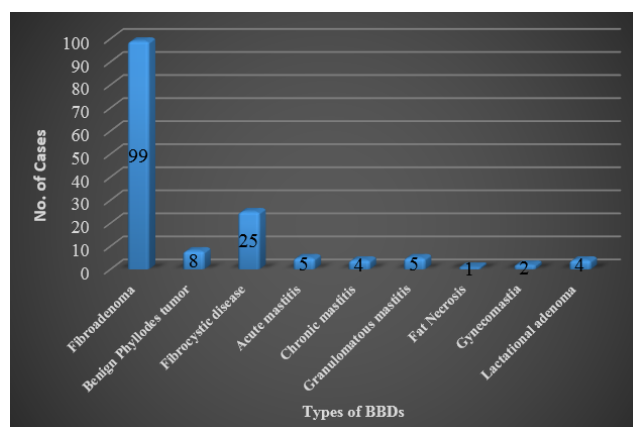


Chart 3: Frequency of benign breast diseases

sided lesions to be common.^{1,12,18,20,23} Breast lesions varied in size with maximum number of lesions in the range of 2-5cm similar to studies by Naveen et al and Gupta et al.^{1,24}

Inflammatory lesions of breast accounted for 6% of cases in our study which was similar to the study done by Olu-eddo et al and Ochicha et al.^{6,25} We found them to occur most commonly in the 4th decade which is similar to the finding of Bafakeer¹⁴ However, Nggada et al observed the frequency to be higher in the 3rd decade.¹⁹

We observed that the incidence of acute mastitis among benign breast lesions was relatively low (3.3%) which concurs with the studies of Shirley et al, Maychet et al and Yusufu et al.^{18,26,27} Other studies like Malik et al (12.4%) and Siddiqui et al (12%) reported a higher incidence.^{9,28} In the context of age group, acute mastitis was most commonly seen in the 2nd decade [Mean age = 24 years; Median age = 20 yrs] while Usmaan K et al found it to be in the 3rd decade.²³ Mean age of acute mastitis in the other studies was even higher.^{10,13,25,28}

Chronic mastitis is a chronic inflammation of the breast tissue. It's incidence in our study was around 2.6% which concurs with the findings of Dafe et al and Malik et al.^{9,12} We found that the predominant age group affected are women in their thirties as was also the case in the study by Oltean et al.²⁹

Granulomatous mastitis was first enunciated as a distinct histopathological entity by Kessler and Wolloch et al in 1972.³⁰ They reported breast masses in five women with a florid, sometimes necrotising, granulomatous lobulitis that was not associated with trauma, specific infection, or exogenous material. Since then, Fletcher et al has furnished the medical community with the largest body of published work on the subject followed by a smaller series of individual cases reported by Koelmeyer and MacCormick et al, Cohen et al and Brown and Tang et al.^{31–34} The present study had 5 cases of granulomatous mastitis with an incidence of 3.3% which is comparable to the study by Siddiqui et al.²⁸ The mean age of patients was 34.4

years and a majority of them fell in the 4th decade of life, which was similar to the finding of Boufettal et al in 2012.³⁵ In our present study, discrete granulomas were seen in 2 cases and confluent granulomas in 3 cases of granulomatous mastitis. However in the studies done by Kessler & Wolloch et al and other authors the focus was only on discrete granulomas.³⁰ Inflammatory changes were observed in the ducts in one case in the present study which was also observed in studies done by Fletcher et al and Miller et al.^{31,36} Other miscellaneous changes like ductular dilatation was seen in one case in the present study similar to various other studies.

Lactating adenoma is an uncommon tumor of secretory mammary epithelium that occurs in pregnant and lactating women. It is a well differentiated benign neoplasm of the terminal ducts with distinct morphologic features.³⁷ In the present study incidence of lactating adenoma was 2.6 similar to the study done by Yusufu et al.²⁷ Lactating adenoma was seen more commonly in 3rd decade of life with mean age of 27 years which was also reported in the study by Hussain et al.²¹

Fibroadenoma of the breast is a frequently occurring tumor. In the present study incidence of fibroadenoma was 64.7% similar to the study done by Khanna et al (60%).⁵ Majority of cases in the present study occurred in the 3rd decade of life similar to the studies by Samir et al, Olu-eddo et al and others.^{13,25}

Proliferating fibromyxoid stroma compressing the surrounding ducts in intracanalicular pattern was the chief histologic feature in 29.3% cases of this tumor while 26.3% cases were pericanalicular. Majority of cases however showed mixed features (44.4%) unlike in the study by Geethamala et al. where pericanalicular pattern was most the common pattern (50.9%).³⁸ Nevertheless this distinction has been observed to have no clinical outcome.

Complex features like apocrine metaplasia, epithelial hyperplasia, cysts measuring > 3 mm and calcification were appreciated in fibroadenoma in our study which was similar to the study done by Kujiper et al, who in addition encountered findings of sclerosing adenosis.³⁹

Phyllodes tumors are a rare entity in the breast. They make up < 1% of all breast tumors. In the present study they comprised 5.2% of benign breast lesions comparable to the study done by Naveen et al where it was 4%.¹ In our study mean age of phyllodes tumor was 40.5 years similar to studies done by Tan et al. and Hussain et al.^{21,40} Majority of these tumors (87.5% cases) were well circumscribed in our study which was similar to Tan et al's study. Cystic degeneration in phyllodes tumor was seen in 14.3% cases in his study which was again comparable to our study (12.5%).⁴⁰

Fibrocystic disease of the breast is common and it can mimic carcinoma in clinical, radiographic, gross and microscopic appearance. Clearly some forms, especially those that are proliferative and atypical, are

associated with increased risk for subsequent development of carcinoma. Our study documented 16.3% of cases (25 cases) of fibrocystic disease which correlated with study done by Rasheed et al.¹¹ Fibrocystic disease was found to be most common in the 4th decade in our study which is similar to the study done by Bafakeer and Godwins et al.^{14,22} But studies done by Olu-eddo and Raju showed increased number of cases in the 3rd decade.^{25,41}

5. Conclusion

Breast lesions are a cause of concern as a few of them carry the potential risk of turning malignant. Timely excision, evaluation and confirmation of histological findings helps us to differentiate benign from malignant lesions. In our study, benign lesions outnumbered malignant with a benign to malignant ratio of 1.6:1. Benign breast lesions have diverse varieties and presentations, hence are very interesting. Among the benign breast lesions encountered in the present study, fibroadenoma was the commonest BBD followed by fibrocystic disease occurring in young females peaking in the third decade of life. Since majority of benign lesions do not carry the risk of turning malignant, a timely diagnosis will prove invaluable in averting a needless radical mastectomy. It is therefore, imperative for pathologists, radiologists and oncologists to identify the small minority of benign cases that do carry the risk of evolving into a full-fledged cancer, so that the appropriate treatment modality may be implemented at the earliest. Though fine needle aspiration cytology prior to surgery provides a reliable picture as to the nature of the lesion, histopathology ultimately remains the gold standard for the diagnosis of benign breast lesions. Other diagnostic tools like immunohistochemistry are certainly helpful but may not be cost effective.

6. Source of funding

None.

7. Conflict of interest

None.

References

1. Naveen N, Mukherjee A, Mahajan V. A clinical study of benign breast disease in rural population. *J Evol Med Dent Sci*. 2013;2(30):5499–511.
2. Rosai J. Rosai and Ackerman's Surgical pathology. 9th ed. India: Elsevier; 2004. p. 1763–1876.
3. Connolly JL, Jacobs TW. The breast. In: Silverbergs principles and practice of surgical pathology and cytopathology. 4th ed. Philadelphia: Churchill Livingstone; 2006. p. 419–504.
4. Oluwale SF, Freeman HP. Analysis of benign breast lesions in blacks. *Am J Surg*. 1979;137:786–789.
5. Khanna R, Khanna S, Chaturvedi S, Arya NC. Spectrum of breast disease in young females: A retrospective study of 1315 patients. *Indian J Pathol Microbiol*. 1998;41(4):397–401.

6. Ochicha, Edino ST, Mohammed AZ, Amin SN. Benign breast lesions in Kano. *Nigerian J Surg Res*. 2002;4(1):1–5.
7. Malik R, Bharadwaj VK. Breast lesions in young females a 20-year study for significance of early recognition. *Indian J Pathol Microbiol*. 2003;46(4):559–562.
8. Batool M, Arian M, Gardezi J. An experience with breast disease in a surgical unit of a teaching hospital of Lahore. *Biomedica*. 2005;21:108–112.
9. Malik M, Salahuddin O, Azhar M, Dilawar O, Irshad H, et al. Breast diseases; Spectrum in Wah Cantt; POF Hospital Experience. *Professional Med J*. 2010;17(3):366–372.
10. Dayan A. Frequency of Clinically Palpable Lumps in Patients Presenting with. *Breast Dis Breast Clin JSOGP*. 2013;4:212–217.
11. Rasheed A, Sharma S, Rasool M, Bashir S, Hafiz A, Bashir N. A Three Year Study of Breast Lesions in Women aged 15-70 years in a Tertiary Care Hospital. *Sch J App Med Sci*. 2014;2(1):166–168.
12. Dafe G, Nwachokor FN, Igbe AP, Odokuma EI, Ijomone EA. Benign breast diseases in Warri Southern Nigeria: A spectrum of histopathological analysis. *Ann Nigerian Med*. 2014;8(1):28–31.
13. Samir S, Rahman A, Ilahi F, Sheikh S. The spectrum of breast diseases in Saudi Arab females: A 26 year pathological survey at Dhahran health center. *Ann Saudi Med*. 1995;15(2):125–132.
14. Bafakeer S. Breast diseases in Southern Yemen. *Saudi Med J*. 2010;31(9):1011–1014.
15. McFarlane MFC. Benign Breast Diseases in an Afro-Caribbean Population. *East Afr Med J*. 2001;78(7):358–359.
16. Okoth C, Galukande M, Jombwe J, Wamala D. Benign proliferative breast diseases among female patients at a sub Saharan Africa tertiary hospital: a cross sectional study. *BMC Surg*. 2013;13(9):1–5.
17. Ullah N, Israr M, Ali M. Evaluation of Benign Breast Lump. *Pak J Surg*. 2010;26(4):261–264.
18. Maychet MB, Panda SK, Dasiah S. A Clinico-Pathological study on Benign Breast Diseases. *J Clin Diagn Res*. 2013;7(3):503–506.
19. Nggada HA, Gali BM, Bakari AA, Yawe-Terna EH, Tahir MB, Apari E. The spectrum of female breast diseases among Nigerian population in Sahel climatic zone. *J Med Med Sci*. 2011;2(10):1157–1161.
20. Abhijit MG, Anantharaman D, Bhoopal S, Ramanujam R. Benign breast diseases: experience at a teaching hospital in rural India. *Int J Res Med Sci*. 2013;1(2):73–78.
21. Hussain N, Ayaz B, Nadia N, Ali Z. Pattern of Female Breast Diseases in Karachi. *Biomedica*. 2005;21:36–38.
22. Godwins E, Dzuachi D, Jenrola A. Histopathological analysis of benign breast diseases in Makurdi, North Central Nigeria. *Int J Med Sci*. 2012;3(5):125–128.
23. Usman K, Ullah E, Hussain S, Shafiq S. Benign Breast Diseases- An experience at Victoria Hospital Bahawalpur. *Pak J Med Sci*. 2013;6(4):877–879.
24. Gupta A, Gupta AK, Goyal R, Sharma K. A Study of Clinical Profile of Benign Breast Diseases Presenting at a Tertiary Care Centre in Central India. *Sch J App Med Sci*. 2015;3(2):695–700.
25. Olu-Eddo AN, Ugiagbe EE. Benign breast lesions in an African population: A 25-year histopathological review of 1864 cases. *Niger Med J*. 2011;52(4):211–216.
26. Shirley SE, Mitchell D, Soares DP, James M, Escoffery CT, Rhoden AM. Clinicopathologic Features of Breast Disease in Jamaica: Findings of The Jamaican Breast Disease Study. *West Ind Med J*. 2008;57(2):90–94.
27. Yusufu L, Odigie VI, Mohammed A. Breast masses in Zaria. *Nigeria Ann Afr Med*. 2003;2(1):13–16.
28. Siddiqui MS, Kayani N, Gill MS, Pervez S, Aziz SA, Muzaffar S. Breast Diseases: a histopathological analysis of 3279 Cases at a Tertiary Care Center in Pakistan. *JPMMA*. 2003;53:94.
29. Oltean HN, Soliman AS, Omar SO, Youssef TF, Karkouri M, Abdel-Aziz A. Risk Factors for Chronic Mastitis in Morocco and Egypt. *Int J Inflamm*. 2013;p. 10. Available from: <http://dx.doi.org/10.1155/2013/184921>.
30. Kessler E, Wooloch Y. Granulomatous mastitis: a lesion clinically simulating carcinoma. *Am J Clin Pathol*. 1972;58:642–646.
31. Fletcher A, Magrath IM, Riddell RH, Talbot I. Granulomatous mastitis: a report of seven cases. *J Clin Pathol*. 1982;35:941–945.
32. Koelmeyer TD, Dem M. Granulomatous mastitis. *Aust NZ J Surg*. 1976;46:173–176.
33. Cohen C. Granulomatous mastitis: a review of 5 cases. *S Afr Med J*. 1977;52:15–16.
34. Brown LK, Tang P. Post-lactational tumoral granulomatous mastitis: a localised immune phenomenon. *Am J Surg*. 1979;138:326–329.
35. Boufettal H, Essodegui F, Noun M, Heras S, Samouh N. Idiopathic granulomatous mastitis: A report of twenty cases. 2012;93(7):586–596.
36. Miller F, Seidman I, Smith CA. Granulomatous mastitis. NY State. *J Med*. 1971;71:2194–2195.
37. Choudhury M, Singal MK. Lactating adenoma - cytomorphic study with review of literature. *Indian J Pathol Microbiol*. 2001;44(4):445–448.
38. Geethamala K, Vani BR, Murthy VS, Fibroadenoma RM. A harbor for various histopathological changes. *Clin Cancer Investig J*. 2015;4:183–187.
39. Kuijper A. Histopathology of fibroadenoma of the breast. *Am J Clin Pathol*. 2001;115:736–742.
40. Tan PH, Thiagarajan J, Khoon-Leong C, Hwei-Yee L, Maryam YT, H. Phyllodes Tumors of the Breast: The Role of Pathologic Parameters. *Am J Clin Pathol*. 2005;123:529–540.
41. Raju GC, Jankey N, Naraynsingh V. Breast disease in young West Indian women: an analysis of 1051 consecutive cases. *Postgrad Med J*. 1985;61:977–978.

Author biography

Shweta Pai Assistant Professor

Cite this article: Pai S. The spectrum of benign breast diseases among females: A 6-year histopathological study. *Indian J Pathol Oncol* 2019;6(4):561-567.