

Cytological diagnosis and management of Bacille-Calmette-Guerin (BCG) induced lymphadenitis in infants

Devyani Pendharkar¹, Mohammad Jaseem Hassan^{2,*}, Sabina Khan³, Shaan Khetrpal⁴, Nehal Ahmad⁵, Sujata Jetley⁶

¹Demonstrator, ^{2,3}Associate Professor, ^{4,5}Assistant Professor, ⁶Professor, Dept. of Pathology, Hamdard Institute of Medical Sciences & Research (HIMSR), Jamia Hamdard, New Delhi, India

***Corresponding Author: Mohammad Jaseem Hassan**

Email: jaseemamu@gmail.com

Received: 4th September, 2018

Accepted: 15th October, 2018

Abstract

Introduction: Bacillus-Calmette-Guerin (BCG) is a live attenuated vaccine and used to prevent tuberculosis since 1921. The efficacy of BCG Vaccine against tuberculosis is uncertain, this vaccine is protective against the meningeal/miliary TB in childhood tuberculosis and not for adult tuberculosis. BCG vaccine is considered as a safe method of tuberculosis prevention because there are only local adverse reactions seen with this and serious complications are rare. Lymphadenitis is the most common complication of BCG vaccination. There are two forms of BCG lymphadenitis in natural course of lymphadenopathy. Simple or non-suppurative lymphadenitis which usually resolves spontaneously within a few weeks, and suppurative lymphadenitis, which characterized by appearance of fluctuation with erythema and edema of overlying skin.

Materials and Methods: A total of 8 cases were included in our study, which presented to our institute in a period of one and half year, age varying from 2 months to 1 year, presented with left axillary lymph nodes. None of the child had fever/ cough or any history of weight loss or loss of appetite. FNAC was performed and smears were stained with Giemsa stain, Hematoxylin & Eosin stain (H&E) and Ziehl-Neelson (ZN) stain.

Results: A total of 8 cases were studied with the mean age of 5.12 months. Majority of the patients were male with male to female ratio of 1.6:1. Out of 8 cases, only two cases had partially healed BCG scar while rest 6 cases had healed BCG scar mark with no reaction or inflammation at that site. On FNAC pus was aspirated in 50% of cases. On microscopic examination, epithelioid granulomas along with necrosis was seen in six cases, while only degenerated cells with diffuse necrosis were seen in two cases. On ZN stain acid fast bacilli were seen in 7 cases.

Conclusion: Awareness about BCG induced lymphadenitis as a possible complication following BCG vaccination is necessary among parents, paramedical staff and medical practitioners is of paramount importance so that early diagnosis and effective management is done for such cases.

Keywords: BCG Vaccination, Complication, FNAC, Infants, Tuberculosis.

Introduction

The causative organism of Tuberculosis (TB) is *Mycobacterium tuberculosis*. Tuberculosis affects large human population and causes morbidity and mortality significantly. It spreads by airborne mode and primarily affects lungs and usually associated with overcrowding, poor hygiene and increasingly associated with Human Immunodeficiency Virus (HIV) pandemic. In 2008, around 1.4 million new cases of TB among persons with HIV infection and TB accounted for 23% of AIDS-related deaths.¹ Diagnosis of TB can be difficult which leads to delayed diagnosis and treatment initiation that causes further spread. There are few preventive measures for TB i.e. BCG vaccination, treatment of patient with latent tuberculosis and other epidemiological measures like prevention of overcrowding, contact tracing and screening as well as chemoprophylaxis.

Bacillus-Calmette-Guerin (BCG) is a live attenuated vaccine and used to prevent tuberculosis since 1921. The world health organization (WHO) has recommended BCG Vaccination as a part of the global expanded program for immunization (EPI) in developing countries.² The efficacy of BCG Vaccine against tuberculosis is uncertain, this vaccine is protective against the meningeal/miliary TB in childhood

tuberculosis and not for adult tuberculosis.³ BCG vaccine induces delayed type of hypersensitivity (DTH) reaction and cell-mediated immunity in the host 4-8 weeks after vaccination.⁴

BCG vaccine is considered as a safe method of tuberculosis prevention because usually there are local adverse reactions seen and serious complications are rare. Lymphadenitis is the most common complication of BCG vaccination.^{5,6} There are two forms of BCG lymphadenitis in natural course of lymphadenopathy. Simple or non-suppurative lymphadenitis which usually resolves spontaneously within a few weeks, and suppurative lymphadenitis, which characterized by appearance of fluctuation with erythema and edema of the overlying skin.⁵

Materials and Methods

A total of 8 cases were included in our study, which presented to our institute in a period of one and half year. Infants' age varying from 2 months to 1 year who presented with left axillary lymph nodes, noticed by the parents at different time and children were brought to hospital and clinicians advised FNAC of the swellings. None of the child had fever/ cough or any history of weight loss as per the history provided by the parents. All the children were taking

feed properly and apparently no decrease in weight or appetite.

FNAC of these patients were done with 24 gauge needle and obtained material on slides were stained with Giemsa stain, Hematoxylin & Eosin stain and Ziehl Neelson stain.

The following criteria was used to identify a case as BCG adenitis: enlargement of isolated axillary lymph node, history of BCG vaccination on the ipsilateral arm, and no local or systemic signs of inflammation.

Results

A total of 8 cases were studied with the mean age of 5.12 months, ranging from 2 months to 12 months. Majority of the patients were male 5 out of 8. All presented with left axillary

lymph node enlargement without any associated symptoms and had a history of enlargement of axillary lymph nodes after BCG vaccination on the same side. Only 2 infants with age of 2 months had partially healed BCG scar, otherwise all other had healed BCG scar mark and no reaction or inflammation at that site. FNAC of the left axillary lymph nodes were done of these infants and in 50% of the patients we got pus on aspiration and in another 50% of cases blood mixed aspirate was obtained. On microscopic examination epithelioid granulomas along with necrosis and only degenerated cells with diffuse necrosis were seen. In 87.5% cases ZN stain showed positivity.

The details of FNAC are given in table number 1.

Table 1: Clinical and cytological details of all eight cases

S. No	Age/ Sex	Clinical Presentation	Site of FNAC	Material aspirated	Microscopic findings	Ziehl- Neelson stain	Diagnosis
Case 1	2 Months /Male	Left axillary swelling since 15 days	Left axillary lymph node, 1.5x1 cm	Grayish aspirate	Few epithelioid cell granulomas	Positive	BCG induced non- necrotizing lymphadenitis
Case 2	2 Months 13 days/ Male	Left axillary swelling since 1 month	Left axillary lymph node, 1.3x1 cm.	Pus	Necrosis along with viable and degenerated lymphocytes and neutrophils	Positive	BCG induced necrotizing lesion
Case 3	3.5 Months /Female	Left axillary swelling since 10- 12 days	Left axillary lymph node, 1.5x1.5 cm.	Blood mixed aspirate	Ill-defined epithelioid cell granulomas	Negative	BCG induced non- necrotizing lymphadenitis
Case 4	3 Months /Male	Left axillary swelling since 2 months	Left axillary swelling, 1.2x1.2 cm	Blood mixed pus	Necrosis and many epithelioid cell granulomas	Positive	BCG induced necrotizing lesion
Case 5	7 Months /Female	Left axillary swelling noticed 6 months back	Left axillary swelling, 2.5x2.5 cm	Pus	Necrosis and epithelioid cell granulomas	Positive	BCG induced necrotizing lesion
Case 6	01year/ Female	Left axillary swelling noticed 1 week back	Left axillary swelling, 1.5x1 cm.	Pus	Predominantly necrosis with scattered histiocytic cells	Positive	BCG induced necrotizing lesion
Case 7	2 months/ Male	Left axillary swelling noticed 15 days back	Left axillary swelling, 2x2 cm.	Blood mixed pus	Epithelioid cell granuloma in a necrotic background	Positive	BCG induced non- necrotizing lesion
Case 8	09 Months /Male	Left axillary lymph node after BCG vaccination	Left axillary lymph node, 1.5x1 cm	Pus	Few degenerating epithelioid cell granulomas with necrosis	Positive	BCG induced necrotizing lesion

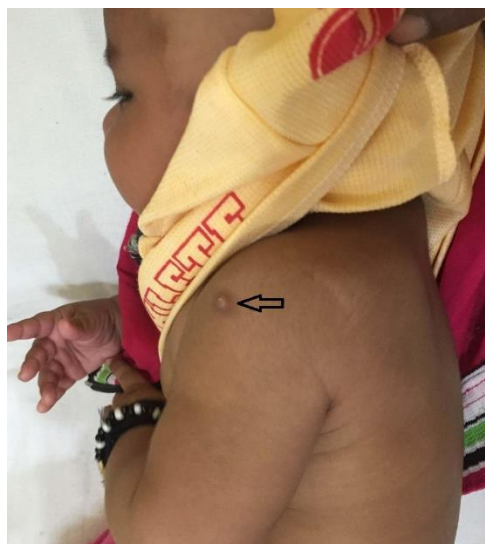

Fig. 1: Clinical photograph of 02 months old male child presenting with swelling and erythema at BCG vaccination site at left arm (Arrow). This patient presented with axillary swelling of 1.5x 1cm, which on FNAC yielded grayish particulate aspirate

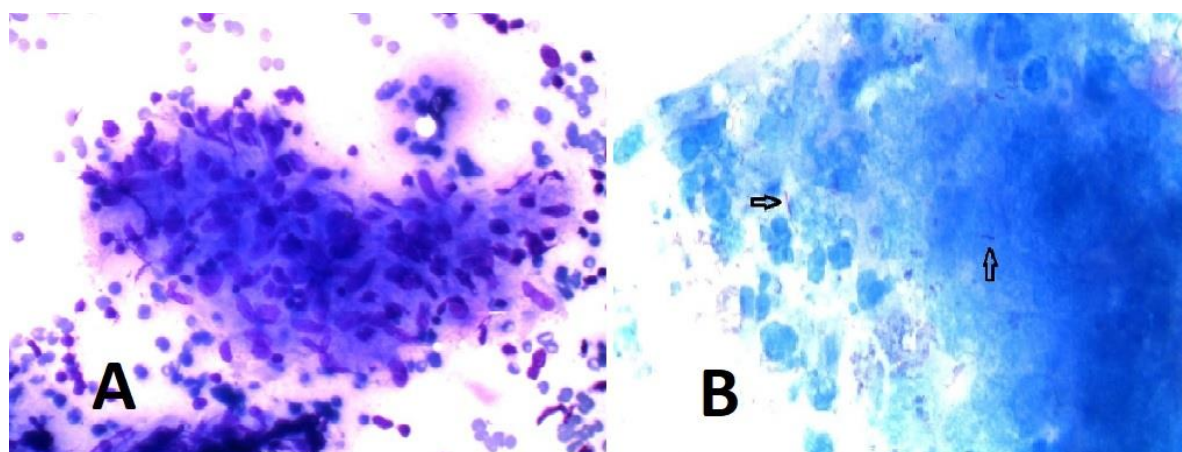


Fig. 2A: FNAC smear from same patient revealed few epithelioid cell granulomas with focal necrosis in a lymphoid background. (Giemsa x 400); **B:** Ziehl- Neelson stain show acid fast bacilli. (Arrow) (ZN x 1000)

Discussion

The BCG vaccine is prepared from live-attenuated strain of bacilli named *Mycobacterium bovis*. It was first developed in the year 1921, however, it was only in 1974 that its wide scale use was recommended by World Health Organization through its inclusion in Expanded Program on Immunization so as to prevent episodes of severe forms of childhood tuberculosis namely TB meningitis and disseminated TB in infants and young children. Majority (around 90%) of the BCG vaccine used worldwide is derived from four strains of *Mycobacterium bovis* namely Pasteur strain 1173, Danish strain 1331, Glaxo strain 1077, and Tokyo strain 172. Among these strains, WHO in 1965 recognized Tokyo 172 strain as an International Reference Strain.⁷ Till now, it is the only available vaccine for prevention of severe forms of TB, however, primary TB infection or the reactivation of latent TB is not prevented by BCG vaccination. Despite this limitation, it remains a proven intervention for TB control measures in endemic areas. The vaccine has widespread use

globally which is indicated by an estimated 100 million children that receive this vaccine each year.⁸

Rare complications arising as a result of BCG vaccination could be described as: 1) mild and 2) severe. Mild complications occur in less than 1 out of 1000 recipients of BCG vaccine and are usually localized, with the most common being regional lymphadenitis either ipsilateral axillary or supraclavicular lymphadenitis. Cutaneous manifestations of mild complications are mainly lupoid reaction and eczema vaccinatum.⁸ Severe complications that may result following BCG vaccination are suppurative lymphadenitis, osteitis/osteomyelitis, and disseminated BCG infection. BCG osteitis/osteomyelitis and disseminated BCG infection are rare but lethal complications with incidence as low as 0.19-1.56 per million recipients, being reported almost exclusively in the vaccines with severely deficient cellular immunity as in severe combined immunodeficiency, chronic granulomatous disease, DiGeorge syndrome, type 1 cytokine axis defects, and HIV infection.⁸⁻¹⁰

Diagnostic criteria of BCG lymphadenitis

1. Isolated axillary (or supraclavicular/cervical) lymph node enlargement.
2. BCG vaccination on the same side.
3. No tenderness and raised temperature over the swelling.
4. No fever and other constitutional symptoms.
5. Chest X-ray, Mantoux reaction and hematological analysis are not helpful. FNAC helps in the clinical diagnosis in doubtful cases.

Tariq et al studied 100 cases and findings revealed unilateral axillary node enlargement in 75% cases, with more than half of them being of suppurative lymphadenitis (55.3%) and remaining 44.7% of non- suppurative lymphadenitis.¹¹ Vaccination at < 1 month old has been identified, as the main predictor of increased risk of lymphadenitis.¹² Such infants had twice the incidence of lymphadenitis as those vaccinated at >3 months of age.¹³ Diagnosis of BCG lymphadenitis is usually made on clinical ground. Small lymph node enlargement occurs as a natural process after vaccination and not considered as complication. However, when axillary lymph node site become visibly enlarged after BCG vaccination and causes concern to the patient, this is considered adverse reaction. Usually there are lack of systemic symptoms like fever and tenderness over the swelling.

Management of BCG lymphadenitis¹⁴

1. Medical- There is no role of antibiotics and antitubercular drugs also are ineffective.
2. Needle aspiration- useful in cases of suppurative BCG lymphadenitis as it reduces the discharge of pus and complications related to suppuration, thereby enhancing the process of healing.
3. Surgical excision- When needle aspiration is failed, multiloculated or matted lymph nodes and draining sinuses are present.

Conclusion

Awareness about BCG induced lymphadenitis as a possible complication following BCG vaccination is necessary among parents, paramedical staff and medical practitioners is of paramount importance so that early diagnosis and effective management is done for such cases. Simple BCG lymphadenitis is managed conservatively and usually resolves on its own. Aspiration for Suppurative lymphadenitis prevents sinus formation and enhances the recovery. In children developing severe complications following BCG vaccination, apart from medical/surgical management, screening for immunodeficiency disorders should also be undertaken.

Conflict of Interest: None.

References

1. World Health Organization. Consolidated guidelines on the use of antiretroviral drugs for treating and preventing HIV infection: recommendations for a public health approach. Geneva: World Health Organization; 2013.

2. Lugosi L. Theoretical and methodological aspects of BCG vaccine from the discovery of Calmette and Guérin to molecular biology. A review. *Tuber Lung Dis Off J Int Union Tuberc Lung Dis* 1992;73(5):252–261.
3. Bannon MJ. BCG and tuberculosis. *Arch Dis Child* 1999;80(1):80–83.
4. Kaur S, Faridi MMA, Agarwal KN. BCG vaccination reaction in low birth weight infants. *Indian J Med Res* 2002;116:64–9.
5. Goraya JS. Bacille Calmette-Guerin lymphadenitis. *Postgrad Med J* 2002;78(920):327–329.
6. Milstien JB, Gibson JJ. Quality control of BCG vaccine by WHO: a review of factors that may influence vaccine effectiveness and safety. *Bull World Health Organ* 1990;68(1):93–108.
7. Yamamoto S, Yamamoto T. Historical review of BCG vaccine in Japan. *Jpn J Infect Dis* 2007;60(6):331–336.
8. Parthasarathy A, Hitt S. BCG Vaccination: Is there light at end of the Tunnel? 2010 [cited 2018 Sep 8];2(5). Available from: <http://www.pediatricsciences.com/article/view/1050000136>
9. Rezai MS, Khotaei G, Mamishi S, Kheirkhah M, Parvaneh N. Disseminated Bacillus Calmette-Guerin Infection after BCG Vaccination. *J Trop Pediatr* 2008;54(6):413–416.
10. Ottenhoff THM, Verreck FAW, Hoeve MA, van de Vosse E. Control of human host immunity to mycobacteria. *Tuberc Edinb Scotl* 2005;85(1–2):53–64.
11. Alfawaz TS, Alshehri M, Alshahrani D. BCG related complications: A single center, prospective observational study. *Int J Pediatr Adolesc Med* 2015;2(2):75–78.
12. Lotte A, Wasz-Höckert O, Poisson N, Dumitrescu N, Verron M, Couvet E. BCG complications. Estimates of the risks among vaccinated subjects and statistical analysis of their main characteristics. *Adv Tuberc Res Fortschritte Tuberkuloseforschung Progres Explor Tuberc* 1984;21:107–193.
13. Murphy D, Corner L a. L, Gormley E. Adverse reactions to Mycobacterium bovis bacille Calmette-Guérin (BCG) vaccination against tuberculosis in humans, veterinary animals and wildlife species. *Tuberc Edinb Scotl* 2008;88(4):344–357.
14. Hong Kong Journal of Paediatrics [HK J Paediatr (New Series) 2011;16:85-94] [Internet]. [cited 2018 Sep 8]. Available from: <http://www.hkjpae.org/details.asp?id=782&show=1234http://www.nlm.nih.gov/medlineplus/ency/article/000821.htm5&artcount=F>

How to cite this article: Pendharkar D, Hassan MJ, Khan S, Khetrapal S, Ahmad N, Jetley S. Cytological diagnosis and management of Bacille-Calmette-Guerin (BCG) induced lymphadenitis in infants. *Indian J Pathol Oncol* 2019;6(1):63-66.